

CONGENITAL DIAPHRAGMATIC HERNIA: ANAESTHETIC MANAGEMENT

Dr.Mohammed Shahid, Dr.Sharath Krishnaswami, Dr.Ravi Madhusudhana*,
Dr.Manjunath Basvapatna, Dr.Dinesh Krishnamurthy, Dr.Rajanna Kapanaiiah

Sri Devaraj Urs Medical College, Tamaka, Kolar, Karnataka, India.

Article Received on
28 Feb 2015,

Revised on 20 March 2015,
Accepted on 13 April 2015

*Correspondence for
Author

Dr.Ravi Madhusudhana
Sri Devaraj Urs Medical
College, Tamaka, Kolar,
Karnataka, India.

ABSTRACT

Anomalous closure of pericardio-peritoneal canal can result in Congenital Diaphragmatic Hernia. It is associated with a high degree of mortality and morbidity because of associated pulmonary hypertension and pulmonary hypoplasia. The management poses a challenge to the Anaesthesiologist due to hypoxia and hypercarbia which leads to pulmonary hypertension and right to left shunt. Here we describe the successful anaesthetic management of a three day old female child with Congenital Diaphragmatic hernia.

KEYWORDS: Congenital Diaphragmatic hernia, pulmonary hypertension, hypoxia, Pulmonary hypoplasia.


INTRODUCTION

Congenital diaphragmatic hernia is a neonatal surgical emergency. This malformation occurs in 1 in 2,500 live births and affects left side 4 to 8 times more than the right.^[1] It results from anomalous closure of pericardio-peritoneal canal. Consequently, abdominal organs develop in the pleural cavity, impairing the growth of the ipsilateral lung. In 90% of the cases the hernia is on the left side through foramen of Bochdalek.

Infants with severe hypoplasia exhibit symptoms in the first few minutes to hours of life. Classic triad of CDH includes; cyanosis, dyspnea, and apparent dextrocardia. Physical examination shows; scaphoid abdomen, bulging chest, decreased breath sounds, right displaced heart sounds, and bowel sounds in chest. Radiographic examination shows; bowel gas pattern in the chest, mediastinal shift, and little lung tissue at the costophrenic sulcus. Ultrasonography is vital for antenatal diagnosis of CDH.^[2] After recent advances in the care of these patients, several centres are now reporting survival rates >80%.^[3]

"DME/VIR/ANAE/1913/2015-16"

"1651"

	SRI DEVARAJ URS MEDICAL COLLEGE TAMAKA, KOLAR	FORMAT No.	
		ISSUE NO.	
		REV. NO.	
	REQUISITION FORM - FOR STAFF		DATE

Date 8/5/15

From

Staff Name: Mohammed Shahid
Designation: Assistant Professor
Department: Anaesthesia

To

The Principal
SDUMC, Tamaka, Kolar

Through: Proper Channel

Respected Sir,

Sub:- To inform regarding publication of case report & request for Incentive

I, Dr. Mohammed Shahid, Asst Prof in Dept of anaesthesia want to inform regarding the publication of a case report "Congenital Diaphragmatic hernia - Anaesthesia management". I request you for the incentive kindly do the needful

Forwarded to the principal
to do the needful




Signature of Staff

Inward Register No.

Concerned Section Comments:

Verified Concerned Manager:

Principal Remarks:


Professor Anand
Department of Anaesthesiology
Sri Devaraj Urs Medical College
R.L. Jolappa Hospital & Research Centre
TAMAKA, KOLAR-563 401.

8.5.15

PREPARED BY	APPROVED BY
-------------	-------------

Forwarded to R&D Co-ordinator for documentation. 18/5/15

CASE REPORT

A single live female baby was delivered vaginally on 24.12.2015 at 3:00 pm. The baby cried immediately after birth and was shifted to the Neonatal ICU. The patient was delivered after a prolonged labor for more than twenty-four hours. The baby had a birth weight of 3.2 kg. At the NICU, the baby was found to have cyanosis and tachypnoea. The room air saturation was found to be 68% and baby had secretions through the mouth and nose. APGAR score was 8/10. The patient was intubated with size 3.5 oral endotracheal tube and connected to the ventilator.

Post Intubation, the baby was pink in color, respiratory rate was 50/min, Pulse rate was 170/min, patient was found to have a prominent chest, and breath sounds were not heard on the left side. The bowel sounds were found to be heard over the chest on auscultation.

On abdominal examination, inguinal sites were normal. Abdomen was scaphoid in shape. (Fig 1) Skin was healthy, abdomen was soft and no masses were felt. Bowel sounds were present. Anal opening was present and was stained with meconium. Spine was normal and the nasogastric tube could be passed into the stomach.

An Abdominal Ultrasonogram showed Congenital Diaphragmatic Hernia. Chest X ray PA view showed multiple air shadows in left hemithorax and mediastinum shifting to right. (Fig 2).

Laboratory investigations showed, blood urea: 99 mg%, Serum Creatinine: 1.0 mg%, Sodium: 127 mg%, Potassium: 5.8 mg%, and Calcium: 8.8 mg%. Hb: 18 g%, Total Count: 15,500/uL, and Platelets: 1,50,000/uL. Echocardiography showed dextrocardia, small Patent Foramen Ovale (1-2MM) Small Patent Ductus Arteriosus (1-2MM) with Right -Left Shunt, Severe Pulmonary Hypertension (ESVP- 50MMH) with Good Left Ventricle/Right Ventricle Function. Interatrial septum had a small Foramen Ovale. The pre-intubation Arterial Blood Gas showed a pH of 7.17, pO₂ of 128 mm Hg and pCO₂ of 55 mm Hg. Post intubation and surgery the Arterial Blood Gas showed pH of 7.36, pO₂ of 206 mm Hg and pCO₂ of 25 mm Hg.

The patient was shifted into the OT with Oral Endotracheal tube in situ. The patient was induced with Inj. Thiopentone 15 mg i.v. through a peripheral venous line secured over the right forearm. Inj. Morphine 0.3 mg i.v. was given as an analgesic. Patient was maintained

with Oxygen and Sevoflurane at the rate of 2 Litres per minute and a MAC of 1-2 respectively. Nitrous Oxide was avoided in view of pulmonary artery hypertension.

Inj. Atracurium i.v. was given as a muscle relaxant and the patient was manually ventilated through Jackson Ree's modification of Ayer's T piece. Hypothermia was avoided using warm blankets. Normocapnia was maintained by ventilating with a low tidal volume and high respiratory rate.

The patient was monitored using pulse oximetry, electrocardiography, End Tidal Carbon Dioxide and fluids were given according to Holliday and Segar formula. The Heart was auscultated using a Pre-cordial Stethoscope placed over the right hemithorax. As the surgery progressed, the position of the maximal impulse was found to shift from the right hemithorax towards the left hemithorax. The left lung inflation was found to be adequate. (Fig 4) Post surgery, the vitals were found to be stable.

Intra operatively, the contents of the Diaphragmatic Hernia were reduced and the diaphragm repaired. (Fig 3) The patient was reversed using Inj. Atropine 0.04 mg i.v. and Inj. Neostigmine 0.15 mg. i.v. The patient was not extubated but shifted directly to the Neonatal Intensive Care Unit for further management. The patient was put on Pressure Control Mode of Ventilation with a Positive End Expiratory Pressure (PEEP) of 3 cm of H₂O, P (insp) of 12 cm of H₂O and FiO₂ of 40%. The patient was extubated after three days. Pulmonary pressures returned to normal. Post operative Chest X-Ray showed lung shadows within normal limits. The patient showed no signs of failure to thrive.

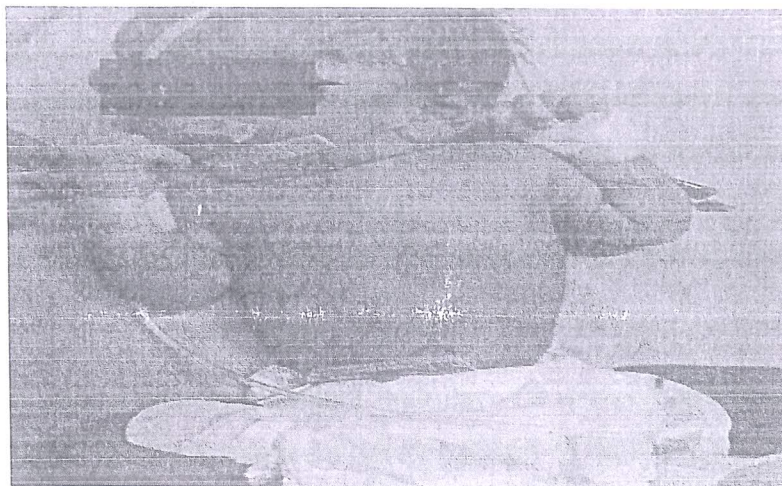


FIG 1: Scaphoid abdomen

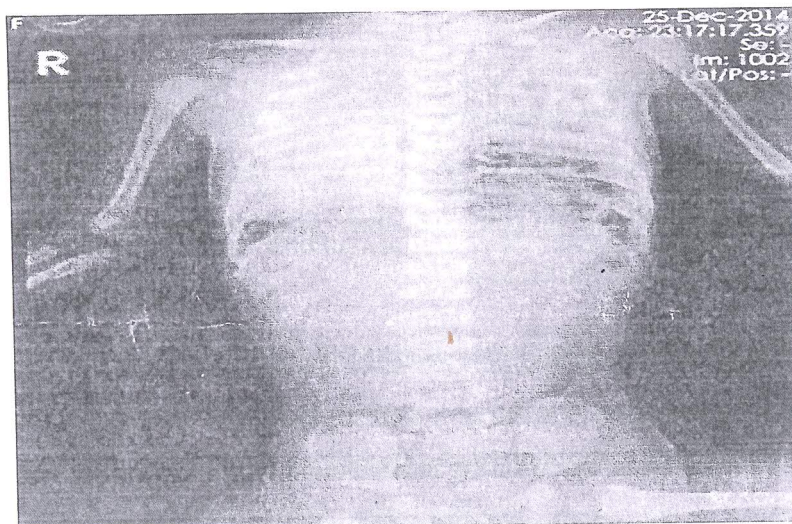

FIG 2: CXR pre surgery

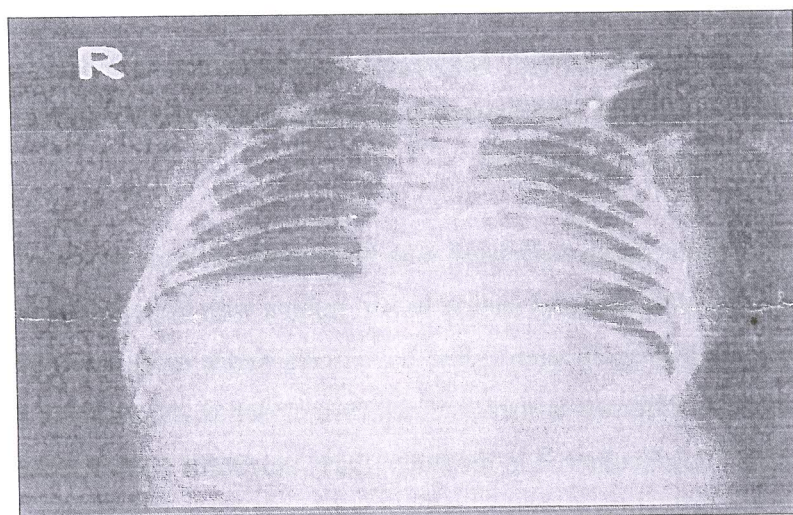


FIG 3: Post op CXR

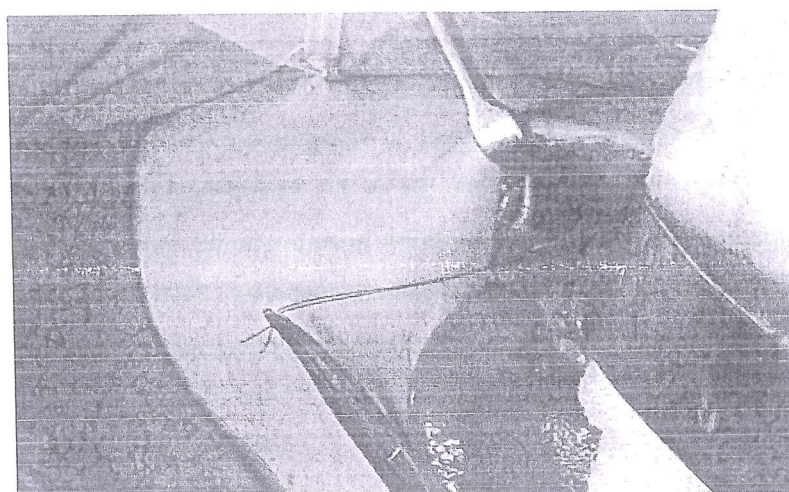


FIG 4: Diaphragmatic rent

DISCUSSION

Congenital diaphragmatic hernia symptomatic at birth is traditionally considered a surgical emergency and correction of defect is carried out as early as possible. However poor pulmonary functions contribute to poor outcome. The rationale of surgery is to allow maximum expansion of lung at the earliest.^[4]

Early antenatal diagnosis, with proper perioperative management is vital for good prognosis. Nitrous oxide (N_2O) should be avoided as it diffuses inside the viscera and exaggerates lung compression. Challenges faced by us during management of this case, included the possibility for reversal of shunt in the presence of already existent pulmonary hypoplasia, pulmonary hypertension, and systemic hypotension due to mediastinal shift. The primary pulmonary hypoplasia and pulmonary hypertension would lead to hypoxemia. Therefore, ventilation with low tidal volume and careful intraoperative monitoring of SpO_2 , $EtCO_2$ and intraoperative airway pressures is important to prevent hypoxemia. The intraoperative airway pressure was maintained at $<25 \text{ cmH}_2\text{O}$.

Postoperative ventilation can be associated with barotrauma. Hence, low inspiratory pressure ($<25 \text{ cmH}_2\text{O}$) and low tidal volumes should be set. Infants with large defects may not tolerate primary closure of abdomen. In such cases, the viscera needs to be covered with a silastic pouch initially and the abdomen is stretched and then closed at a later stage. This gives time for gradual healing.^[1] Lochbuhler H in his study, thirty newborns were anesthetized for repair of a congenital diaphragmatic hernia with no intraoperative complication and an overall mortality of 27%.^[5]

CONCLUSION

Congenital diaphragmatic hernia symptomatic at birth with poor pulmonary functions contribute to poor outcome with a challenge to anaesthesiologist. The concept of permissive hypercarbia ($PaCO_2$ of 45-55 mmHg and pH of 7-7.3) and gentle ventilation with low tidal volume and high respiratory rate, maintaining normovolemia, normocapnia, normothermia makes most significant impact on survival in neonates with CDH. The rationale of surgery is to allow maximum expansion of lung at the earliest which we managed efficiently in our case with successful outcome.

REFERENCES

1. Joshi S, George A. Anesthetic management of a case of congenital diaphragmatic hernia; delayed diagnosis. *Med J DY Patil Univ.*, 2013; 6: 281-3.
2. Brett CM, Davis PJ, Bikhazi G. Anesthesia for neonates and premature infants. In: Motoyama EK, Davis P, editors. *Smiths Anesthesia for infants and children*. 7th ed. Philadelphia, Mosby, 2005; 545-6.
3. King. H, Booker. P.D, *Continuing Education in Anaesthesia, Critical Care & Pain*, 2005; 5(5): 171-4.
4. Jain.A, Dr. Singh.V, Sharma.M; Congenital diaphragmatic hernia: Our experience - a brief review; *Indian J. Anaesth.*, 2002; 46(6): 426-429.
5. Lochbühler H. Anesthesia for congenital diaphragmatic hernia, *Anaesthesist.*, 1987; 6(6): 280-4.