

**“EFFECTIVENESS OF LASER PERIPHERAL IRIDOTOMY IN
PRIMARY ANGLE CLOSURE SUSPECTS VISITING TERTIARY
CARE HOSPITAL”**

By

DR. SHREY MAHESHWARI

Dissertation Submitted to

**SRI DEVARAJ URS ACADEMY OF HIGHER EDUCATION AND
RESEARCH**

KOLAR



In partial fulfillment
Of the requirements for the degree of

**MASTER OF SURGERY
IN
OPHTHALMOLOGY**

**Under the Guidance of
DR. K. KANTHAMANI, M.S.**



**DEPARTMENT OF OPHTHALMOLOGY
SRI DEVARAJ URS MEDICAL COLLEGE
TAMAKA, KOLAR (APRIL - 2017)**

**SRI DEVARAJ URS ACADEMY OF HIGHER EDUCATION AND
RESEARCH**

DECLARATION BY THE CANDIDATE

I hereby declare that this dissertation entitled

**“EFFECTIVENESS OF LASER PERIPHERAL IRIDOTOMY IN
PRIMARY ANGLE CLOSURE SUSPECTS VISITING TERTIARY CARE
HOSPITAL”**

*is a bonafide and genuine research work
carried out by me
under the guidance of*

DR. K.KANTHAMANI, M.S.

Professor and H.O.D.

Department of Ophthalmology

Sri Devaraj Urs Medical College

Kolar, Karnataka.

DATE:

SIGNATURE OF THE CANDIDATE

PLACE: KOLAR

DR. SHREY MAHESHWARI

**SRI DEVARAJ URS ACADEMY OF HIGHER EDUCATION AND
RESEARCH**

CERTIFICATE BY THE GUIDE

This is to certify that the dissertation entitled

**“EFFECTIVENESS OF LASER PERIPHERAL IRIDOTOMY IN
PRIMARY ANGLE CLOSURE SUSPECTS VISITING TERTIARY
CARE HOSPITAL”**

is a bonafide research work done by

DR. SHREY MAHESHWARI

*Under my guidance and supervision,
in partial fulfilment of the requirement for the degree of*

M.S. IN OPHTHALMOLOGY.

DATE :

SIGNATURE OF THE GUIDE

PLACE: KOLAR

DR. K.KANTHAMANI , M.S.

Professor and H.O.D.

Department of Ophthalmology

ENDORSEMENT BY THE HOD, PRINCIPAL / HEAD OF THE
INSTITUTION

This is to certify that the dissertation entitled

**“EFFECTIVENESS OF LASER PERIPHERAL IRIDOTOMY IN
PRIMARY ANGLE CLOSURE SUSPECTS VISITING TERTIARY
CARE HOSPITAL”**

is a bonafide and genuine research work carried out by

DR. SHREY MAHESHWARI

under the guidance of

DR. K.KANTHAMANI, M.S

Professor and H.O.D.

Department of Ophthalmology

Sri Devaraj Urs Medical College

Signature of the HOD

Dr. K.KANTHAMANI, M.S.

Professor and H.O.D.

Department of Ophthalmology

S.D.U.M.C., Tamaka, Kolar.

Signature of the Principal

Dr. M.L. HARENDRA KUMAR, M.D.

Principal

Sri Devaraj Urs Medical College

Kolar, Karnataka

DATE:

PLACE: KOLAR

DATE:

PLACE : KOLAR

**SRI DEVARAJ URS ACADEMY OF HIGHER EDUCATION &
RESEARCH**

ETHICAL COMMITTEE CERTIFICATE

*This is to certify, the ethical committee of
Sri Devaraj Urs Medical College, Tamaka, Kolar
has unanimously approved,*

Dr. SHREY MAHESHWARI

*Post Graduate student in the subject of
Ophthalmology at Sri Devaraj Urs Medical College
Kolar*

to take up the dissertation work titled

**“EFFECTIVENESS OF LASER PERIPHERAL IRIDOTOMY IN
PRIMARY ANGLE CLOSURE SUSPECTS VISITING TERTIARY
CARE HOSPITAL”**

*to be submitted to Sri Devaraj Urs Academy of Higher
Education and Research, Kolar, Karnataka*

Signature of Member Secretary

Ethical committee

DATE:

PLACE: KOLAR

Signature and seal of the Principal

Dr. M.L. HARENDRA KUMAR

Sri Devaraj Urs Medical College

Kolar, Karnataka

ACKNOWLEDGEMENT

I express my deepest gratitude to my guide **DR.K.KANTHAMANI, M.S**, Professor and HOD, Department of Ophthalmology, Sri Devaraj Urs Medical College, Tamaka, Kolar; without whose support this would have never been accomplished. She has always been a constant source of inspiration and motivation that guided and pushed me to the next level of my career. Her insight broadened my horizons and enabled me to expand my knowledge in a number of ways. With a great teacher like you, I was sure that this would be a successful journey. I would be indebted to you life long for teaching me valuable lessons both in ophthalmology and life.

I would also like to thank **DR. NARENDRA.P.DATTI**, Professor, Department of Ophthalmology, Sri Devaraj Urs Medical College, Tamaka, Kolar for guiding me throughout this journey called ophthalmology.

I also express my sincerest gratitude to **DR. PADMAJOTHI**, Professor, Department of Ophthalmology, Sri Devaraj Urs Medical College, Tamaka, Kolar, for their valuable suggestions and help all through this time.

I would like to express my heartfelt thanks to my Assistant Professors, **DR. USHA B.R., DR. SANGEETHA, DR. RASHMI** & Senior Residents **DR. INCHARA, DR. CHAITRA**, Department of Ophthalmology, Sri Devaraj Urs Medical College Tamaka, Kolar for their help and suggestions rendered to me during this study.

My gratitude and thanks to **Dr. M.L HARENDRA KUMAR M.D**, Principal, Sri Devaraj Urs Medical College Tamaka, Kolar, for letting me use the college and hospital facilities and resources.

The list cannot be compiled without special thanks **Dr. Shubratanu, Dr. Ashwini, Dr. Asadhi Nithin, Dr. Preethi, Dr. Ankita, Dr. Bhavya, Dr. Vaibhav , Dr. Arvind and Dr. Raghvendra Varma**, without whom this would not have been possible.

I would also like to thank all my co-pgs **Dr. Prashanth, Dr. Dildar and Dr. Shaliini**. The list will be incomplete without my seniors and juniors who were an important part of this journey, with a special mention to **Dr. Sugranjini** and **Dr. Dilip**, who guided me just like a friend.

Last but not least, I would like to thank my parents Dr.Sunil Maheshwari and Mrs. Chanchal Maheshwari, for being with me and giving me strength at every step of my life. Without whom I would have never got it through.

At the end but not the least, my heartfelt gratitude to all my patients who submitted themselves most gracefully and whole-heartedly participated in this study. I sincerely thank my institute Sri Devaraj Urs Medical College, Tamaka, Kolar for giving me a wonderful foundation and forum of knowledge in the field of Ophthalmology which stands for the rest of my life.

DATE:

SIGNATURE OF THE CANDIDATE

PLACE: KOLAR

LIST OF ABBREVIATIONS USED

- POAG – PRIMARY OPEN ANGLE GLAUCOMA
- PACG – PRIMARY ANGLE CLOSURE GLAUCOMA
- PACS – PRIMARY ANGLE CLOSURE SUSPECT
- PAC – PRIMARY ANGLE CLOSURE
- CPAC – CHRONIC PRIMARY ANGLE CLOSURE
- CPACG – CHRONIC PRIMARY ANGLE CLOSURE GLAUCOMA
- IOP – INTRA OCULAR PRESSURE
- PAS – PERIPHERAL ANTERIOR SYNECHIAE
- LPI – LASER PERIPHERAL IRIDOTOMY
- VES – VELLORE EYE STUDY
- UBM – ULTRABIOMICROSCOPY
- APEDS – ANDHRA PRADESH EYE DISEASE
- ACES – ARAVIND COMPREHENSIVE EYE SURGERY
- CGS – CHENNAI GLAUCOMA STUDY
- WBGS – WEST BENGAL GLAUCOMA STUDY
- AGIS – ASSOCIATION OF INTERNATIONAL GLAUCOMA SOCIETY
- C.E. – COMMON ERA
- SD – STANDARD DEVIATION
- US – UNITED STATES
- WGA – WORLD GLAUCOMA ASSOCIATION
- GAT – GOLDMANN APPLANATION TONOMETRY

- CCT – CENTRAL CORNEAL THICKNESS
- TM – TRABECULAR MESHWORK
- NO. – NUMBER
- e.g.. – EXAMPLE
- OD – OCULUS DEXTER (RIGHT EYE)
- OS – OCULUS SINISTER (LEFT EYE)
- i.e. – THAT IS
- mm – MILLIMETER
- Hg – MERCURY
- mg - MILLIGRAM
- CAI – CARBONIC ANYDRASE INHIBITOR
- Nd : YAG – NEODYMIUM YITTRIUM ALUMINUM GARNET
- mj – MILLI JOULES
- SPSS – STATISTICAL PACKAGE FOR SOCIAL SCIENCES
- t – STUDENT ‘T’ TEST
- ANOVA – ANALYSIS OF VARIANCE

ABSTRACT

TITLE OF THE TOPIC:

“EFFECTIVENESS OF LASER PERIPHERAL IRIDOTOMY IN NARROW ANGLE GLAUCOMA SUSPECTS VISITING TERTIARY CARE HOSPITAL”

NEED FOR THE STUDY:

Glaucoma is the second leading cause of blindness in the world. The prevalence of glaucoma is estimated to be 1.44% in general population. Laser peripheral iridotomy (LPI) has been proposed as the standard prophylactic option for patients with primary angle closure suspect (PACS) and a treatment option for PACG. The purpose of the study is to comment on actual reduction in incidence of narrow angle glaucoma after laser peripheral iridotomy.

OBJECTIVES OF THE STUDY:

To see the effectiveness of LPI in Primary Angle closure suspects

1. By measuring changes in Anterior chamber depth and Anterior Chamber angle after peripheral iridotomy in PACG suspects.
2. By determining the number of cases that converted from suspects to primary angle closure glaucoma cases even after LPI

MATERIAL AND METHODS:

Source of Data:

Informed consent was taken from all patients and procedure was done on patient were followed for 1 year and parameters like IOP and changes in anterior chamber were noted.

Minimum of 56 patients suspected, as narrow angle glaucoma will be selected for this prospective study R.L.J.H and R.C attached to SDUMC

MATERIAL AND METHODS:

FiftySix patients fulfilling the criteria framed were included in this study. All the patients underwent detailed evaluation comprising of history, visual acuity, anterior segment examination with slit lamp, applanation tonometry, gonioscopy, stereo examination of optic disc, keratometry, fields and A-Scan biometry.

Data was analyzed using the statistical program for social sciences software (SPSS). Paired t test will be used to investigate the difference in anterior segment parameters before and after the LPI.

RESULTS:

In this observational clinical study, the mean age of the patients included in the study fell between 49.54 ± 6.05

Majority of the patients were female that accounted to 83.9% of the total while male patients constituted only 16.1% of the total studied cases.

The mean IOP of the enrolled participants before LPI treatment was 17.07 ± 2.02 mm of Hg. After LPI, the IOP decreased by an average of 3 mmHg in treated eyes at 1 month follow up which was statistically significant.

Peripheral ACD evaluation using van Herick method and A-scan biometry showed significant widening after LPI ($P < 0.001$; t paired test) between pre-LPI and the follow-up cases.

The Shaffer angle width, analyzed using gonioscopy done by 3 mirror, increased significantly in all 4 quadrants especially both superior and inferior quadrants ($P < 0.001$, paired t test).

CONCLUSION:

In our study we found that Laser peripheral iridotomy, is an effective way of preventing the conversion of Primary angle closure suspects to Primary angle closure glaucoma.

LPI is the effective way of widening the angle in occludable angles and it also increases the anterior chamber depth, thus helping in control of the IOP.

We have come to a conclusion that patients who are suspected to have future attacks of angle closure, especially females above 40 year of age, should prophylactically undergo LPI.

KEYWORDS

PACS, LPI,

LIST OF CONTENT

<u>NO.</u>	<u>PARTICULARS</u>	<u>PAGE NO.</u>
1	INTRODUCTION	1
2	AIMS AND OBJECTIVES	4
3	REVIEW OF LITERATURE	6
4	MATERIALS AND METHOD	49
5	STATISTICAL ANALYSIS	53
6	OBSERVATION AND RESULTS	54
7	DISCUSSION	66
8	CONCLUSION	77
9	SUMMARY	79
10	BIBLIOGRAPHY	81
11	ANNEXURES	90

LIST OF TABLES

<u>NO.</u>	<u>PARTICULARS</u>	<u>PAGE NO.</u>
1	INDIAN POPULATION BASED STUDIES	12
2	SHAFFER'S GONIOSCOPIC CLASSIFICATION	39
3	AGE DISTRIBUTION OF PATIENT STUDIED	55
4	GENDER DISTRIBUTION OF PATIENT STUDIED	56
5	EYE LATERALITY IN PATIENT STUDIED	57
6	BEST CORRECTED VISUAL ACUITY (LOGMAR)	58
7	INTRAOCULAR PRESSURE	59
8	ANTERIOR CHAMBER DEPTH	61
9	ANTERIOR CHAMBER ANGLE: BEFORE LPI	62
10	ANTERIOR CHAMBER ANGLE: AFTER LPI	63
11	AXIAL LENGTH	64

LIST OF TABLES

<u>NO.</u>	<u>PARTICULARS</u>	<u>PAGE NO.</u>
12	LENS THICKNESS	64
13	PACS TO PACG CONVERSION	65
14	VISUAL FIELD CHANGES	65
15	FUNDUS CHANGES	65
16	AGE DISTRIBUTION: COMPARISION	67
17	SEX DISTRIBUTION: COMPARISION	68
18	FOLLOW UP PERIOD: COMPARISION	69
19	CHANGE IN IOP: COMPARISION	70
20	CHANGE IN ACD: COMPARISION	71
21	CHANGE IN ACA: COMPARISION	72
22	PACS TO PACG CONVERSION: COMPARISION	75

LIST OF GRAPHS

<u>NO.</u>	<u>PARTICULARS</u>	<u>PAGE NO.</u>
1	AGE DISTRIBUTION OF PATIENT STUDIED	55
2	GENDER DISTRIBUTION OF PATIENT STUDIED	56
3	EYE LATERALITY IN PATIENT STUDIED	57
4	INTRAOCULAR PRESSURE	60
5	ANTERIOR CHAMBER DEPTH	61
6	ANTERIOR CHAMBER ANGLE: BEFORE LPI	62
7	ANTERIOR CHAMBER ANGLE: AFTER LPI	63

LIST OF FIGURES

<u>NO.</u>	<u>PARTICULARS</u>	<u>PAGE NO.</u>
1	GONIOSCOPIC VIEW	14
2	ANGLE OF ANTERIOR CHAMBER	17
3	UVEOSCLREAL OUTFLOW SYSTEM	17
4	PENLIGHT EXAMINATION OF ANTERIOR CHAMBER	37
5	SLIT LAMP EXAMINATION OF ANTERIOR CHAMBER	38
6	SHAFFER'S GONIOSCOPIC CLASSIFICATION	40
7	CONVENTIONAL LPI	46

LIST OF PHOTOGRAPHS

<u>NO.</u>	<u>PARTICULARS</u>	<u>PAGE NO.</u>
1	SLIT LAMP EXAMINATION	94
2	IOP MEASUREMENT BY GOLDMANN'S APPLANATION TONOMETER.	94
3	GONIOSCOPY BY 3 MIRROR GONIO LENS.	95
4	PATENT IRIDOTOMY SITE AFTER LPI	95
5	VISUAL FIELDS TESTING BY HUMPHREYS FIELD ANALYZER	96
6	GLAUCOMATOUS DISC CUPPING	96
7	NEURO-RETINAL RIM THINNING WITH NERVE FIBRE LAYER DEFECT	97
8	NORMAL VISUAL FIELD	97
9	GLAUCOMATOUS VISUAL FIELD DEFECT	98

INTRODUCTION

Glaucoma is the second leading cause of blindness in the world. The prevalence of glaucoma is estimated to be 1.44% in general population.¹ The epidemiological studies indicate the higher prevalence of primary open angle glaucoma (POAG) in comparison with primary angle closure glaucoma (PACG). However, the visual impairments in patients with PACG is 2 to 3 times more than POAG.²

World Health Organization statistics, indicate that glaucoma accounts for blindness in more than 5.1 million people, or 13.5% of global blindness (behind cataracts and trachoma at 15.8 million and 5.9 million persons, or 41.8% and 15.5% of global blindness, respectively)³.

Primary angle closure glaucoma (PACG) is a leading cause of bilateral blindness worldwide⁴. The disease is estimated to affect 16 million people, with 4 million bilaterally blind. The chronic primary angle closure (CPAC) spectrum of disease ranges from primary angle closure suspects (PACS) to CPAC to chronic primary angle closure glaucoma (CPACG). This is a relative common condition especially in East Asia and a leading cause of bilateral glaucoma blindness in countries such as Singapore (Chinese)⁵ and Indian population.

PACS consists of eyes with anatomically narrow angles potentially predisposing to angle closure. These patients are prone to undergo angle closure later. Once closure has developed [as evidenced by elevated intraocular pressure (IOP), peripheral anterior synechia (PAS), trabecular pigment smudging, or other signs of true

apposition of iris to trabecular meshwork)], CPAC has occurred. Chronic primary angle closure glaucoma (CPACG) is diagnosed when, in addition to CPAC, glaucomatous optic neuropathy is present, as evidenced by visual field defect, nerve fiber layer, or optic nerve damage.

As PACS possess such a risk, it is advisable to screen and diagnose the patients who belong to suspect spectrum and to provide a prophylactic treatment with Laser peripheral iridotomy, to prevent them from developing glaucoma and thus decreasing morbidity and the overall burden of glaucoma on the health system.

The various studies done could not comment on actual reduction in number of narrow angle glaucoma after laser peripheral iridotomy in PACS. Hence we conducted this study to check the effectiveness of LPI in angle closure suspects.

OBJECTIVES OF STUDY

THE OBJECTIVE OF THE STUDY WAS TO:

To study the effectiveness of LPI in Primary Angle closure suspects by:

- Measuring changes in anterior chamber angle and anterior chamber depth
- Determining the number of suspects that converted to glaucoma cases.

REVIEW OF LITERATURE

REVIEW OF LITERATURE

Hippocrates is credited for the term “glaucois,” which translates to “sea green eye. It was not until the beginning of the nineteenth century that Antoine-Pierre Demours (1818) gave the first excellent description of glaucoma with a raised ocular tension in a treatise. The clinical picture was fully detailed and he described for the first time as the appearance of the colors of a rainbow around the lights. In London, Guthrie GJ recognized hardness of the eye as a characteristic of a disease, which he termed ‘Glaucoma’.

Currently, we define the glaucoma as a group of optic neuropathy characterized by recognizable patterns of optic disc and retinal nerve fiber structural and visual field functional damage, which may or may not be associated with a raised IOP⁶.

Glaucomatous optic neuropathy is not the disease; it is the end-result of several as yet unidentified cellular disease processes. The changes of the optic nerve head known as cupping with progressive loss of the retinal nerve fiber layer and associated functional deficits are hallmark of the disease; which is due to accelerated retinal ganglion cell apoptosis. Therefore, the definition varies according to the person defining: blindness fear for the patient, ganglion cell apoptosis to a scientist and an optic neuropathy to a clinician.

The link with disc cupping followed Hermann von Helmholtz’s 1860s invention of the ophthalmoscope and Albrecht von Graefe’s observations. Thus, there arose the structural nerve head-based definitions in which Glaucoma was considered a

neurological disease. The association with raised intraocular pressure (IOP) occurred over several centuries but was boosted by improvements in tonometer between 1880 and 1910.

In 1907, Trantas visualized the angle in an eye with keratoglobus by indenting the limbus. He later coined the term gonioscopy, meaning observation of angle. Salzmann, realizing that the angle was not visible due to internal reflection introduced the goniolens in 1914. Otto Barkan established the use of goniolens in management of glaucoma.⁷

With the advent of the gonioscope, various others pointed out that glaucoma could be divided into two types, one with an open angle and other with closed angle.

Clinical based studies from a white- Caucasian population reported 19% of those untreated PACS or PAC progressed to PACG over a mean follow up period of 2.5 years. Most (68%) presented with non acute angle closure.⁸

There is very little population-based data available on the natural history of primary angle closure disease, mostly from India. Those diagnosed to have PACS and PAC in the Vellore eye survey (VES) were followed up untreated over a period of 5 year.⁹

In VES, 11 of 50 persons with PACs progressed to develop PAC over a period of 5 year but none progressed to PACG. All those who progressed had bilateral PACS at baseline. One previously normal person progressed to PAC with time; the relative risk

of progression was shown to be 24.2%. Out of all the patients 9 patients who underwent laser peripheral iridotomy (LPI), 1 patient that accounted to 11.1% progressed to PACG. 7 out of 19 patients who refused LPI, progressed to PACG⁹

LPI has been proposed as the standard prophylactic option for patients with primary angle closure suspect (PACS) and a treatment option for PACG.¹⁰ It prevents recurrence of acute episodes and eliminates the risk of acute attacks in PACG suspects.^{11,12}

By allowing aqueous to flow directly through the iridotomy site, LPI equilibrates the pressure between the anterior and posterior chambers. Elimination of this pressure gradient flattens the iris thus allowing the peripheral iris to fall backward finally resulting in a wider angle configuration.¹³

A study found that 8% of 126 Chinese PACG patients (a mixture of PAC suspects, PAC patients, PACG patients, and acute angle closure patients) had ultrabiomicroscopy (UBM) features that were consistent with these other possible mechanisms before and after iridotomy¹³

Few studies on other populations showed that iridotomy had no effect on ocular biometry parameters namely axial length, Anterior chamber depth and lens thickness. No long term study reported the effect of LPI on all ocular parameters measured using A-scan biometry and UBM among primary angle closure suspects from Indian population.¹⁴

A study on angle closure glaucoma suspects reported 25(19.5%) patients progressed to angle closure glaucoma after a mean of 2.7 years follow up.¹⁵

Another study shows LPI results in a significant increase in angle width in both Europeans and Asians with narrow angles.^{16,17} However, the prophylactic efficacy of LPI for disease control is dependent primarily on the underlying mechanism.

Individuals with an anatomically narrow angle can be classified as a primary angle closure suspect when gonioscopy reveals a shallow peripheral angle recess with the iris close to trabecular meshwork. The Primary angle closure suspect (PACS) has iridotrabecular contact in three or more quadrants, no peripheral anterior synechiae, and normal intraocular pressure (IOP), optic nerve and visual fields.

A study conducted in hospital-based patients with occludable angles showed IOP to decrease from 14.0 ± 3.6 mmHg to 11.7 ± 2.8 mmHg 6 months after LPI.^{18,19}

A Mongolian population-based intervention study reported lesser increase in fellow eyes of those with PACG, which may indicate that these eyes, which are predisposed to symptomatic angle closure, behave differently in response to LPI.²⁰

EPIDEMIOLOGY:

Population based studies have yielded a wealth of data about glaucoma prevalence, incidence, and risk factors in Caucasian, Latino, African-American, Afro-Caribbean,

Indian sub-continental, and Oriental population. Second only to cataract, globally glaucoma is the leading cause of visual disability. As the damage caused is irreversible, but mostly avoidable by treatment, glaucoma is the leading cause of preventable blindness. As prevalence increases exponentially with increasing age, glaucoma is set to become increasingly and relentlessly a worldwide public health issue as populations grow.

The percentage undiagnosed is far greater in underprivileged communities with up to 90% of glaucoma patients are not diagnosed.^{21, 22}

Glaucoma affects a substantial proportion of the adult population worldwide. PACG is the major cause in some populations. Increasing age is a consistent risk factor for the disease as improvements in socioeconomic and medical care world-wide have seen steady increase in life expectancy and due to that, there is a significant increase in glaucoma prevalence world wide. As per Broman and Quigley's estimates²³, by the year 2020 we will have 21 million people suffering from PACG

PREVALENCE OF GLAUCOMA IN INDIA:

Glaucoma is estimated to affect 60.5 million persons worldwide by the year 2010. The estimated prevalence of glaucoma for India is 11.9 million. These estimates have been derived from population-based studies conducted worldwide. The availability of population-based data from India is relatively recent as compared to Western countries. There are five populations based studies, three from the state of Tamil Nadu, one from Andhra Pradesh and one from West Bengal. These studies have been carried out from 1993 to 2003. All these studies have used differing methodology and diagnostic criteria for glaucoma.

STUDY	STUDY PERIOD	SETTING	AGE GROUP	Number examined
VES	1994	Urban	30-60	972
APEDS	1996-2000	Rural, Urban	All ages	10,273
ACES	1995-97	Rural	>40	5150
CGS	2001-03	Rural , Urban	>40	7774
WBGS	1998-99	Rural	>50	1324

Table: 1. Indian population based studies.

****VES:** VELLORE EYE STUDY, **APEDS:** ANDHRA PRADESH EYE DIDESE STUDY, **ACES:** ARAVIND COMPREHENSIVE EYE SURVEY, **CGS:** CHENNAI GLAUCOMA STUDY, **WBGS:** WEST BENGAL GLAUCOMA STUDY

PRIMARY ANGLE CLOSURE GLAUCOMA PREVELENCE IN INDIA

The VES was the first to report that PACG comprised a significant proportion of those with glaucoma. The VES definition of PACG encompassed those now classified as PAC in addition to those with PACG. Five persons were reported to have angle closure disease with disc and field damage. These would correspond to a diagnosis of PACG; this prevalence is similar to other reported rates of PACG by studies in South India.^{24, 25,26,27,28} Subsequent reports from the APEDS²⁴ did report a lower prevalence of angle closure disease. The difference was most marked in the lower prevalence of PACS. The prevalence of angle closure disease in the CGS^{25,4} is again similar to that reported by the VES. The urban area of the CGS had higher rates of PAC, PACS and PACG than the rural cohort.^{25,26} The VES and the CGS used similar gonioscopy criteria to diagnose a narrow angle (needing 180° of the angle to be closed as defined) unlike other studies that needed three fourths of the angle to be narrow before grading

as occludable. The CGS did report that of those with PACG who were previously diagnosed to have glaucoma, 40% were misdiagnosed as POAG.

ANATOMICAL CONSIDERATIONS:

Intraocular pressure maintenance and glaucoma pathophysiology revolves around the aqueous humour dynamics. Pars plicata of the ciliary body, a forward continuation of the choroid at the ora serrate, forms aqueous humor, which then enters the posterior chamber and through the pupil, enters the anterior chamber and drains into the peripheral recess or angle of the anterior chamber.

The angle has an important role in the process of aqueous drainage. Clinically, the angle structures can be visualized by examination through a gonioscope. Starting from posterior to anterior, the angle recess is formed by the following structures:

THE CILIARY BAND

It is the posterior most landmark in the angle recess. It is formed by the anterior most part of the ciliary body between its attachment to the scleral spur and insertion of iris.

SCLERAL SPUR

It is the posterior portion of the scleral sulcus, which usually appears as a prominent white line on gonioscopy. Ciliary body and corneoscleral meshwork are attached to it respectively. The scleral spur-roll is composed of 75% to 80% collagen and 5% elastic tissue.

TRABECULAR MESHWORK

It is seen as a band just anterior to scleral spur. It bridges the two ends of the depression and leads to a formation of a canal like structure known as schlemm's canal. The appearance of trabecular meshwork varies considerably since at birth it does not contain any pigment but it develops pigments with increasing age.

SCHWALBE'S LINE

It is a fine ridge seen just in front of the trabecular meshwork. It is formed by the oblique insertion of uveal trabeculae into limbal stroma. Anterior limit of the structures forming the angle of the anterior chamber is marked by Schwalbe's line.

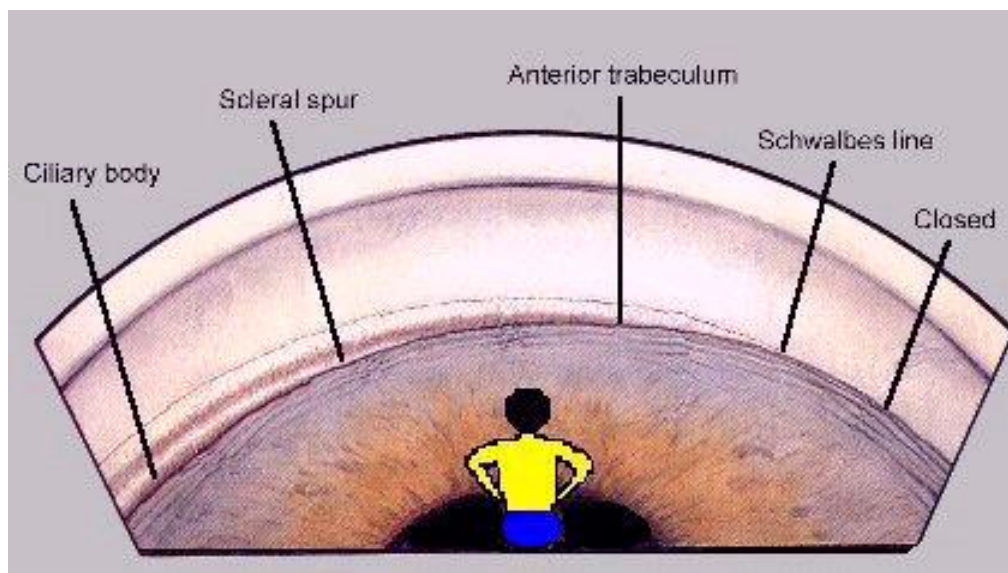


Figure 1: Gonioscopic View

THE AQUEOUS OUTFLOW SYSTEM

It consists of the trabecular meshwork, Schlemm's canal, collector channels, aqueous veins and the episcleral veins.

Trabecular meshwork

It is a band like structure seen just anterior to the scleral spur

It is a sieve through which aqueous humour flows out of the eye. Scleral sulcus is bridged by it and converted into a tube, which forms the Schlemm's canal. It is made up of connective tissue core surrounded by endothelium and can be divided into three portions: (a) uveal meshwork, (b) corneoscleral meshwork, and (c) juxtacanalicular tissue, which is sometimes also called as the cribriform layer

Uveal meshwork

It is the innermost part of the trabecular meshwork, extending from the iris root, ciliary body to the Schwalbe's line. The arrangement of uveal trabecular bands is such that it creates irregular openings, of variable sizes that range from 25 to 75 microns.

Corneoscleral meshwork

It is the larger middle portion and extends from the scleral spur to the lateral wall, of the scleral sulcus. It consists of flat sheets of trabeculae, which have elliptical openings. These opening are smaller than those in the uveal meshwork (5-50 microns).

Juxtacanalicular (endothelial) meshwork

It forms the outermost portion of the trabecular meshwork. This part offers the normal resistance to aqueous outflow.

Schlemm's canal

This is an endothelial lined oval channel present circumferentially in the sclera sulcus. The outer wall of the canal contains the numerous openings of the collector channels.

Collector channels

These are intrascleral aqueous vessels, which are about 25 - 35 in number, and leave the Schlemm's canal at oblique angles ultimately terminates into episcleral veins.

Episcleral veins

Most of the aqueous vessels drain into the episcleral veins, which in return via the anterior ciliary and superior ophthalmic veins ultimately drain into cavernous sinus

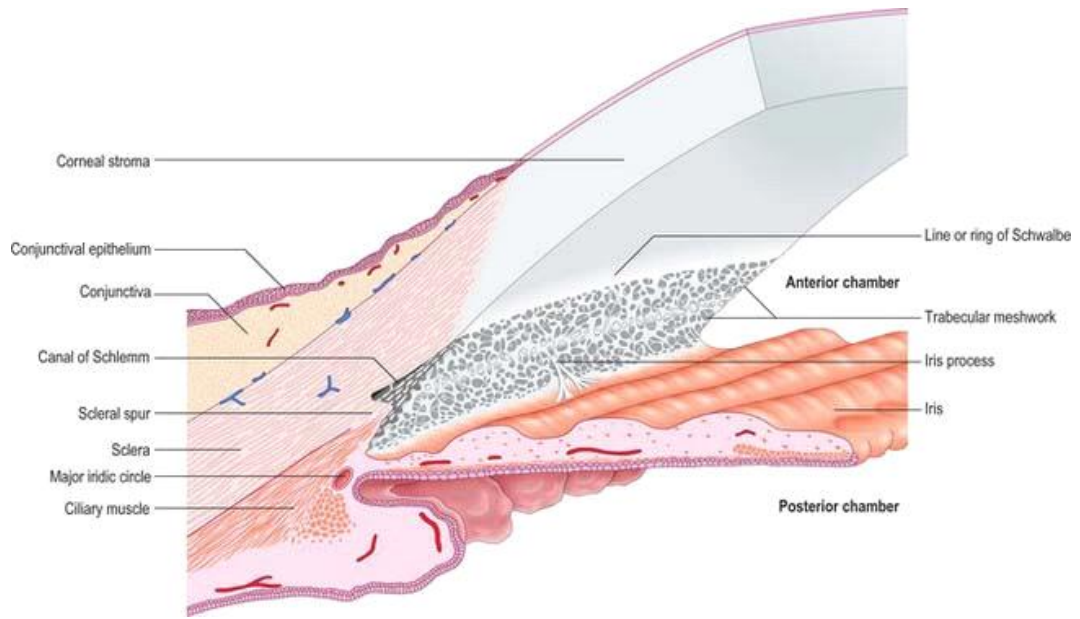


Figure 2: Angle of Anterior Chamber

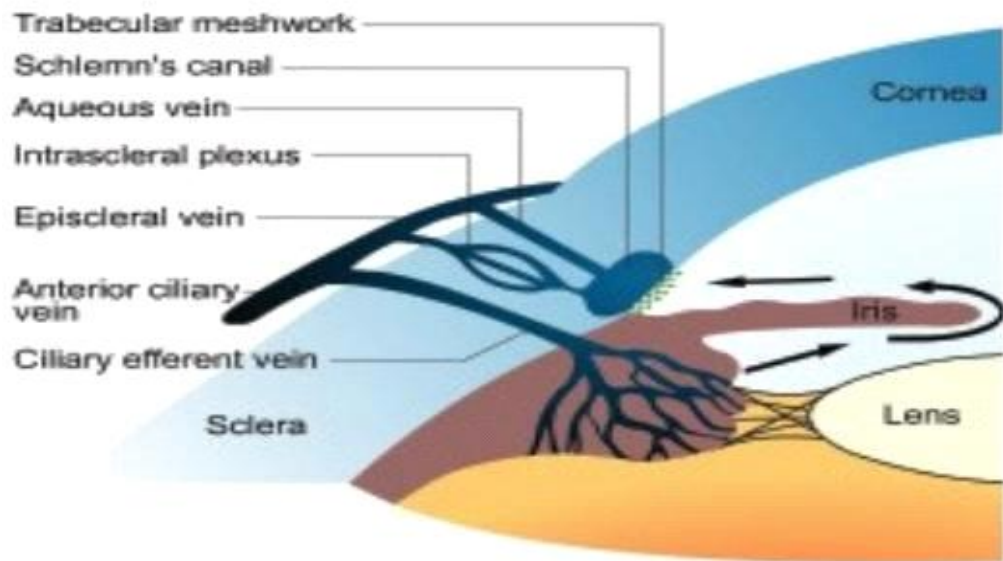


Figure 3: Uveoscleral Outflow System

FORMATION OF AQUEOUS HUMOUR

The derivation of aqueous humour is primarily from plasma within the capillary network of the ciliary processes. The various constituents of the aqueous humour traverse through the three tissue layers viz., the capillary wall, the stroma and the two layers of the epithelium; for reaching the posterior chamber from the plasma within the capillary network of the ciliary processes. The various substances appear to pass through these layers by the following processes: ²⁹

Diffusion

It is a process by which molecules of a gas or solution distribute themselves uniformly throughout the space in which they are contained. In this process, particles from areas of high concentration move to the areas of low concentration. In the process of aqueous production, the lipid soluble substances are transported following the same procedure through the lipid portions of the cell membrane of the ciliary processes. The net flux of the lipid molecules is proportional to a concentration gradient across the membrane.

Ultrafiltration

Ultrafiltration refers to occurrence of dialysis under hydrostatic pressure. In dialysis, when a solution of protein and salt is separated from plain water or a less concentrated salt solution by a membrane which is permeable to salt and water and not the protein, there will be a net movement of water on the

protein side by diffusion and a movement of the salt away from the protein side. In the process of aqueous formation, in response to osmotic gradient or hydrostatic pressure, water and water soluble substances (limited by size and charge) flow through the theoretical micro pores in the protein part of the cell membrane.

Secretion (active transfer)

It is an active process that selectively transports some substances across the cell membrane. With the help of energy, substances can be moved across a concentration gradient in a direction opposite to what would be expected by passive mechanism. In the process of aqueous formation, water-soluble substances of larger size or greater charge are actively transported across the cell membrane. This mechanism is probably mediated by globular proteins in the membrane and requires the energy usage.

CELLULAR ORGANIZATION OF THE UVEOSCLERAL PATHWAY

Historically, two unconventional pathways have been discriminated:

Through the anterior uvea at the iris root and anterior surface of the ciliary body, which is referred to the uveoscleral pathway, and

Through transfer of fluid into the iris vessels and vortex veins, which has been described as uveovortex outflow.

The uveoscleral outflow for aqueous humor also known as unconventional outflow has not been studied as extensively as the trabecular outflow pathway

Uveoscleral outflow

Studies in the eyes of animals ^{30,31} and humans ³² have shown that aqueous humor passes through the root of the iris, then to interstitial spaces of the ciliary muscle, to reach the suprachoroidal space. From there it passes to episcleral tissue via scleral pores surrounding ciliary blood vessels and nerves, vessels of optic nerve membranes, or directly through the collagen substance of the sclera. The extracellular matrix of normal human ciliary muscle comprises of collagen types I, III, and IV, fibronectin, and laminin in association with blood vessels and muscle fibers. It has been suggested that the biosynthesis of these glycoproteins may play an important role in resistance to flow within the unconventional pathways and thus mediates a few pharmacological actions

Uveovortex outflow

Tracer studies in primates have also demonstrated non-energy dependent unidirectional flow into the lumen of iris vessel by vesicular transport. The tracer can penetrate vessels of the iris, ciliary muscle, and anterior choroid to eventually reach the vortex veins. However, this role is probably not clinically significant.

Glaucoma can be divided according to the clinical description and etiology in following sub divisions:

(a) Congenital and developmental glaucoma

1. Primary congenital glaucoma (without associated anomalies).
2. Developmental glaucoma (with associated anomalies).

(b) Primary adult glaucoma

1. Primary open angle glaucoma (POAG)
2. Primary angle closure glaucoma (PACG)
3. Primary mixed mechanism glaucoma

(c) Secondary glaucoma.

PRIMARY ANGLE-CLOSURE GLAUCOMA

Angle-closure glaucoma is characterized by obstruction of aqueous outflow due to apposition of the peripheral iris against the trabecular meshwork. Traditionally, some forms of angle-closure glaucoma have been referred to as primary angle-closure glaucoma (PACG) because the mechanisms of angle closure were not thought to be associated with other ocular or systemic abnormalities or because the mechanisms were not well understood. Conditions that have been included in this group are plateau iris, pupillary-block glaucoma and combined mechanism glaucoma.

PUPILLARY-BLOCK GLAUCOMA

Pupillary-block glaucoma is the most common form of these conditions. The initiating event is thought to result due to mid-dilatation of the pupil leading to increased resistance in flow of aqueous humor between the anterior lens surface and the pupillary portion of iris. This functional block causes increased fluid pressure in the posterior chamber, leading to forward bowing of the iris. This Anterior movement of especially the peripheral iris can result

in closure of the anterior chamber angle. Pupillary block glaucoma on the basis of symptoms and clinical findings can be sub classified into 4 types:

1. Sub-acute angle-closure glaucoma
2. Acute angle-closure glaucoma
3. Chronic angle-closure glaucoma and
4. Absolute glaucoma.

SUBACUTE ANGLE-CLOSURE GLAUCOMA

It has same mechanism as the acute form, but symptoms are comparatively milder or in some cases even absent. This condition has also been called as intermittent, prodromal, or subclinical. Patients with sub-acute angle-closure glaucoma may have repeated subclinical attacks, which often go unreported and finally lead to an acute attack or in some cases peripheral anterior synechiae are developed which lead to chronic pressure elevation.

ACUTE ANGLE-CLOSURE GLAUCOMA

In this type of glaucoma, the symptoms are severe and occur suddenly, with marked pain, blurred vision, and a red eye. The patient may also show constitutional symptoms of nausea and vomiting.

CHRONIC ANGLE-CLOSURE GLAUCOMA

In chronic angle-closure glaucoma, due to peripheral anterior synechiae portions of the anterior chamber angle are permanently closed and the intraocular pressure (IOP) is chronically elevated. The synechial closure

may be due to repeated sub-acute attacks of angle-closure glaucoma or due to a prolonged acute attack.

TWENTY-FIRST CENTURY CONSENSUS CLASSIFICATION

According to the new classification of primary angle-closure (PAC) proposed by Association of international glaucoma society (AGIS) in 2006 disease is described on the basis of three simple categories: IOP measurement, gonioscopy, and disc and visual field evaluation.

Primary angle closure SUSPECT (PACS): greater than 270° of irido-trabecular contact plus absence of PAS plus normal IOP, disc, and visual field. The angle is at risk.

Primary angle CLOSURE (PAC): greater than 270° of irido-trabecular contact with either elevated IOP and/or PAS plus normal disc and visual field examinations.

Primary angle-closure GLAUCOMA (PACG): greater than 270° of irido-trabecular contact plus elevated IOP plus optic nerve and visual field damage. In other words, angle closure glaucoma manifests the criteria of closure above, plus demonstrable disc and/or visual field changes. The angle is abnormal in structure and function, with optic neuropathy.

RISK FACTORS

General Features

Factors influencing the configuration of the anterior chamber angle and the risk of developing pupillary block glaucoma can be as follows:

Age

As the age advances, due to thickening and the forward displacement of the lens, the depth and volume of the anterior chamber diminishes. Consequently, the percent of individuals with critically narrow angles is higher in older age groups. However, it can occur at any age, rare cases have been reported even in childhood.

Race

Among all forms of glaucoma, the relative prevalence of pupillary-block glaucoma is increased in various populations of Inuit^{33, 34} and individuals with far Eastern Asian extraction³⁵. Acute angle-closure glaucoma is less commonly seen in blacks, but sub-acute or chronic angle-closure glaucoma is not so uncommon finding and appears to be a regularly missed diagnosis condition.

Gender

In comparison to males according to the statistics females are more affected with pupillary block glaucoma, which is probably caused by the shallower anterior chamber among women in general^{33, 34}.

Refractive Error

The depth and volume of the anterior chamber are related to the degree of emmetropia, with smaller dimensions occurring in hypermetropia.

Family History

The potential for pupillary-block glaucoma is generally believed to be inherited³⁶. In one of the studies, 20% of 95 relatives of angle-closure glaucoma patients were thought to have potentially occludable angles³⁷. However, aside from a few reported families in which many members developed angle-closure glaucoma, the family history is not very useful in predicting a future angle- closure attack.

RISK FACTORS:

Increasing age was a common risk factor for PACG in all studies. Female gender (CGS) was a risk factor for PACG and PAC^{25,4} more women in the APEDS had PACG but this difference was not statistically significant.²⁴ Hyperopia was also a risk factor in the Chennai glaucoma a study (Urban),⁴ a trend of increased risk with hyperopia was noted both in APEDS and CGS (Rural).^{24,38} Among systemic conditions diabetes mellitus was reported to be a risk factor. Biometric data at the baseline visit was available only from the Chennai Glaucoma Study. Eyes with angle closure disease had been reported to have shorter axial length and a shallower anterior chamber and thicker lenses than normal by the CGS.³⁸

The population based studies that report glaucoma prevalence provide important information.^{24,25,26,4} The Indian population has substantial risk for POAG with the additional risk of PACG and large burden of angle closure disease. This assumes greater importance as the risk of all forms of glaucoma increases substantially with age and moreover the vast majority of glaucoma in India is undiagnosed; there is an

urgent need to adopt comprehensive eye examinations, which include IOP measurement, gonioscopy and optic disc evaluation, as a routine.

GLAUCOMA RISK FACTORS: ETHNICITY AND GLAUCOMA

Asians comprise many ethnicities, and findings in one group of Asians do not necessarily generalize to another group of Asians. For example, a nationwide Japanese glaucoma survey reported a prevalence of POAG that is intermediate between that of black-Americans and white-Americans, and a POAG to primary angle-closure glaucoma (PACG) proportion that is similar to that in western populations.³⁹ In contrast, PACG is the predominant type of glaucoma in some Asian populations such as the Chinese.⁴⁰

GLAUCOMA RISK FACTORS: INTRAOCULAR PRESSURE

For the first time, glaucoma was described as a blinding disease associated with high intraocular pressure (IOP) by the Persian physician (810–861 C.E.) in the writings Firdaws al Hikma (Paradise of Wisdom).⁴¹ In the 1800s, the Dutch ophthalmologist Franciscus C. Donders coined the expression “simple glaucoma” for increased IOP occurring without any inflammatory symptoms. In population-based surveys, intraocular pressure (IOP) has been consistently shown to be a continuous, positive risk factor for the prevalence of glaucoma, even though the normal range of IOP.

IOP was found to be an important factor in glaucoma that correlated with increased prevalence and incidence⁴². Population-based screening for glaucoma for long has been handicapped by an undue reliance on IOP levels. The number 21 mmHg as the borderline between normal and abnormal began with a groundbreaking study in 1958

when the IOP of 20,000 eyes was measured with Schiøtz tonometry, and a mean of 15.5 mmHg with a standard deviation of 2.57 mmHg was found.⁴³ In their population (40–75years), the IOP was 15.9 (SD~3) mmHg in men and 16.6 (SD~3) mmHg in women. The distribution of IOP was non-Gaussian with a skew to the right (i.e., more individuals with higher IOP than predicted) in those older than 60 years.

What is the current role of IOP in diagnosis and treatment of glaucoma?

Glaucoma definition does not consider IOP as its part but still its reduction remains the only proven and approved means of judging the efficacy of the treatment. IOP is the single most important modifiable risk factor. To cause glaucomatous optic neuropathy, there is a complex interaction between IOP and other risk factors.

The 2005 report by the US Agency for Healthcare Research & Quality, US Preventative Services Task Force⁴⁴ stated that there is no good single test at present to conduct population screening. However, in 2008, the World Glaucoma Association (WGA) devoted their fifth Consensus meeting to glaucoma screening⁴⁵ for angle-closure glaucoma.

Statistically, elevated IOP does not equate with the diagnosis of glaucoma, and conversely, normal IOP does not exclude the diagnosis of glaucoma. From the standpoint of the management of individual patients, the significance of this is that the diagnosis of glaucoma must be based primarily on the examination of the optic discs and retinal nerve fiber layer and the evaluation of visual function.

Necessity of Continuous IOP Monitoring

Sidler- Huguenin first recorded circadian variations in IOP in 1898. These variations typically range from 3 to 6 mmHg in normal eyes and can exceed 30 mmHg in glaucomatous eyes. Understanding these variations in IOP are important for two reasons. First, they raise the possibility that a single reading taken in the physician's office is not an accurate representation of the patient's normal pressure level. Second, the magnitude of the variation itself is believed to be important for the diagnosis, treatment, and prognosis of glaucoma.

IOP fluctuation during follow-up is associated with a higher probability of VF progression. Large diurnal fluctuations in intraocular pressure are an independent risk factor in patients with glaucoma. Hence, the care of patients with advancing glaucoma should include measurement of long term IOP fluctuation. Even short-term IOP fluctuation is not accurately measured by three IOP measurements during typical office hours (8 am to 5 pm). A continuous monitoring technique is necessary to accurately document a patient's baseline IOP and the extents of inter visit fluctuations. The continuous monitoring technique must be able to sample IOP quickly enough to capture its dynamic behavior.

GLAUCOMA RISK FACTORS: THE CORNEA

Central corneal thickness

It has long been accepted that elevated intraocular pressure (IOP) is a key parameter in the diagnosis of glaucoma. IOP is used in the assessment of disease progression and response to treatment. In fact, it is the only modifiable risk factor for glaucoma. Therefore, its accurate measurement is critical. For over half a century, Goldmann

applanation tonometry (GAT) has been the most widely used method of measuring IOP. In their article, Goldmann and Schmidt determined that, in accordance with the Imbert-Fick Law, IOP is equal to the force necessary to flatten a spherical surface, divided by the surface area of that flattened surface (the cornea). GAT utilizes a cone that applanates a circular area of the corneal surface with a diameter of 3.06 mm. With this circular applanation area, the force necessary to overcome the resistance of the cornea to flattening is equal to the surface tension of the tear film. This allows the force applied to equal the IOP. Goldmann and Schmidt believed that central corneal thickness (CCT) was very similar among individuals in the normal population. However, they acknowledged that when large variations in CCT did occur, the accuracy of the GAT readings could be affected. Corneas that were thicker than normal would require greater force to flatten and thinner corneas would require less, this meant that thicker corneas yielded an overestimation of IOP, whereas thinner corneas gave an underestimation. It has since been demonstrated definitely that significant variations do occur in a normal population.

Across populations, patients with normal eyes have a CCT of approximately 540 μm . Patients with ocular hypertension have been found to have CCT values that are increased about 50 μm compared to glaucoma patients or controls^{46, 47}. This means that many individuals have been falsely labeled as having ocular hypertension, when in fact they have normal IOP once CCT is taken into account. Several studies have shown that some patients with normal tension glaucoma have thinner corneas than patients with normal eyes.⁴⁸ Therefore, if CCT is taken into account, these patients may have elevated IOP with “high pressure” glaucoma. One longitudinal study showed up to a 23 μm decrease over an 8-year period in glaucoma patients.⁴⁹ This

underscores the importance of taking CCT measurements in all patients who have ocular hypertension or glaucoma.

LaRosa et al⁵⁰ reported thinner CCT values among normal black male veterans (mean thickness 530 μm) compared to their white counterparts (545 μm). In another study of patients at a large refractive surgery center, black patients also had thinner CCT values than white patients seeking surgery.⁵¹

GLAUCOMA RISK FACTORS: FAMILY HISTORY – THE GENETICS OF

GLAUCOMA

Kass and Becker⁵² were among the first to observe a relationship between family history and glaucoma, and focused their research on the cup-to-disc ratio, elevated pressure, and the glucocorticoid response. Their early investigations into hereditary aspects of glaucoma noted that there was a relationship between family history and the presence of glaucoma, but that it seemed to defy simple genetic analysis.

Becker, and later Armaly,⁵³ found that glucocorticoid treatment re-elevated IOP more often in glaucoma patients than in other individuals. Testing of family members showed that this response was usually inherited as an autosomal recessive trait.

Subsequently, Polansky⁵⁴ theorized that the mutations of these genes in the trabecular meshwork were associated with a corticoid steroid response. He called the specific induced proteins “Trabecular meshwork Inducible Glucocorticoid Response protein” (TIGR), the same protein later being termed “Myocilin”. Since then, a number of additional genetic loci have been identified that are associated with open angle glaucoma. They all appear to be autosomal dominant.

Pigmentary, pseudoexfoliation, angle closure, and mixed-mechanism glaucoma have been associated with myocilin mutations.^{55, 56} The report of a family with mixed-mechanism glaucoma having a myocilin mutation is intriguing since it suggests that two gene interactions, one for open angle glaucoma and one for narrow angle glaucoma, can both lead to glaucoma. One mutation (Gly399Val MYOC) led to adult POAG with a mean age of onset of 51.

Optineurin is located on GLC1E at chromosome 10. Optineurin may have a role in TNF alpha signaling pathways and has also been implicated in modulation of cellular cytoskeleton of TM cells.

Estimates on the frequency of optineurin have varied substantially, with the original report identifying 16 open angle glaucoma patients as having the disease.⁵⁶ GLC1E has numerous mutations. It has been suggested that those with the mutation appear to have more advanced cupping and require more frequent surgical intervention.⁵⁷ A synonymous variant Thr34Thr was associated with glaucoma in Japan.⁵⁸

REFRACTIVE ERROR

Population-based surveys in European populations have provided some evidence to the commonly held belief that hyperopia is a strong risk factor PACG. However, hyperopia was not statistically significant more prevalent in PACG group than in control group. In the sub analysis, in which a higher hyperopia was investigated, the result also did not reach statistical significance. Even if a person had a spherical equivalent of +10dioptres – an extremely high refraction- the risk of PACG was only 54%⁵⁹.

PRECIPITATING FACTORS

In an eye that is anatomically predisposed to develop angle-closure, several factors may precipitate an attack.

Dim illumination

It has been noted that most often patients give common history for the development of an acute attack of pupillary-block glaucoma when they are in a dark room, such as a theater or restaurant. It has been reported that the incidence of angle-closure is much higher in the winter and autumn.

Emotional stress

Occasionally, an acute angle-closure attack follows severe emotional stress. This may be related to increased sympathetic tone, which in turn leads to mydriasis

Drugs

Mydriatics may also precipitate an angle-closure attack in an anatomically predisposed eye.

Anticholinergics (e.g., atropine, cyclopentolate, tropicamide) are particularly high risk when administered topically. In one study, 0.5% cyclopentolate precipitated attacks in 9 (43%) of 21 high-risk eyes, and 0.5% tropicamide did the same in 19 (33%) of 58 eyes. However, in a population-based screening study of 4,870 subjects whose eyes were dilated with 1% tropicamide and 2.5% phenylephrine after penlight examination of the anterior chamber depth,

none developed an acute angle-closure attack. Other systemic drugs with weaker anticholinergic properties (e.g., antihistaminic, anti-parkinsonian, antipsychotic, and gastrointestinal spasmolytic drugs) also present a risk proportional to their pupillary effect.

Adrenergics (e.g., topical epinephrine) may precipitate an angle-closure attack in the predisposed eye. Phenylephrine can also precipitate an attack, although it was found to be safer than cyclopentolate or tropicamide for dilating high-risk eyes.

THEORIES OF MECHANISM:

RELATIVE PUPILLARY BLOCK

The study by Curran⁶⁰ and Banziger⁶¹ in the early 1920s suggested that the most common mechanism leading to angle-closure glaucoma appears to be increased resistance to aqueous flow from the posterior to the anterior chamber between the iris and lens. This concept was advanced by the teachings of Chandler⁶², who observed that an eye with a shallow anterior chamber has a wider zone of contact between the surfaces of the iris and lens. It has been suggested on the basis of gonioscopic studies that the angle closure occurs in two stages: iridocorneal contact anterior to the trabecular meshwork, followed by apposition of the iris to the meshwork as the pressure rises

Anatomic Factors Predisposing to Pupillary Block

Several anatomic aspects of the eye that combine to produce a shallow anterior chamber includes a thicker, more anteriorly placed lens, a smaller diameter, shorter posterior curvature of the cornea, and a shorter axial length of the globe. The ratio of the lens thickness to the axial length appears to correlate best with the predisposition to angle closure⁶³. All of these parameters are influenced by hyperopia, increasing age, and genetics. Loose zonules leading to forward displacement of lens can also lead to pupillary block glaucoma

CLINICAL PRESENTATION

a) PRIMARY ANGLE CLOSURE SUSPECT (PACS)

This term is used to replace the ‘latent primary angle closure glaucoma’ of clinical classification. Symptoms are as such absent in this stage. The patients belonging to this category are diagnosed either by chance or as a screening procedure during routine ocular examination or on examination in case when fellow eye already present with acute attack of PAC. They show positive eclipse sign and on slit lamp biomicroscopy signs include, decreased axial anterior chamber depth and closed proximity of iris to cornea in the periphery. On Van Herick slit lamp grading they fall in the category of narrow angle. On gonioscopic examination these patients show lower Shaffer’s grading of narrow angle.

b) PRIMARY ANGLE CLOSURE (PAC)

It is the term used to replace subacute (intermittent) primary angle closure glaucoma and acute primary angle closure glaucoma in clinical classification

Sub-acute Angle-Closure Glaucoma

Sub-acute angle-closure glaucoma, a form of pupillary-block glaucoma, may have no recognizable symptoms. In other cases, the patient may notice a dull ache behind the eye or slight blurring of vision. A symptom that is especially typical of the sub-acute attack is colored halos around lights. This is thought to result from corneal epithelial edema, which causes it to act as a diffraction grating, producing a blue-green central and yellow-red peripheral halo. These symptoms, which more often occur at night after the patient has been in a dark room, often spontaneously clear by the next morning, presumably because of the miosis of sleep.

Acute Angle-Closure Glaucoma

Acute angle-closure glaucoma characteristically has pain, redness, and blurred vision. The pain is typically a severe, deep ache that follows the distribution of trigeminal nerve and may be associated with nausea, vomiting, bradycardia, and profuse sweating. The marked conjunctival hyperemia usually consists of a ciliary flush and peripheral conjunctival congestion. The blurring of vision may be caused initially by stretching of the corneal lamellae and later due to corneal edema, as well as a direct effect of the IOP

on the optic nerve head. Rarely, in some cases the corneal decompensation may persist, requiring penetrating keratoplasty.

c) **PRIMARY ANGLE CLOSURE GLAUCOMA (PACG)**

It is the replacement of the term chronic primary angle closure angle glaucoma

Chronic Angle-Closure Glaucoma

Another form of pupillary-block glaucoma, chronic angle-closure glaucoma, is typically asymptomatic until advanced visual field loss develops, although the patient may give a history suggestive of one or more episodes of sub-acute or acute angle-closure glaucoma. Peripheral anterior synechiae may eventually develop with prolonged or recurrent acute or sub-acute attacks, leading to chronic angle-closure glaucoma. The peripheral anterior synechiae in patients after acute angle-closure attacks tend to be broad based, are most commonly seen in the superior quadrant. The synechial closure usually begins superiorly, where the angle is normally narrowest, and progresses inferiorly. This condition has been referred to as shortening of the angle or creeping angle closure.

EXAMINATION OF ANTERIOR CHAMBER

Penlight Examination

The anterior chamber depth can be estimated with oblique illumination by a penlight across the surface of the iris. With the light coming from the

temporal side of the eye, a relatively flat iris is illuminated on the temporal and nasal sides of the pupil, whereas an iris that is bowed forward as in shallow anterior chamber has a shadow on the nasal side.

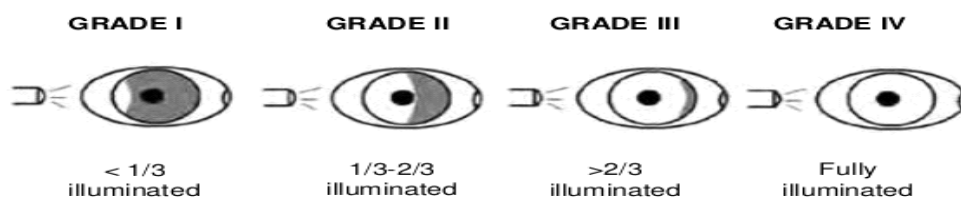


Figure 4: Illumination from the temporal side casts shadow on iris if there is considerable bombé.

Slit-Lamp Examination

The central anterior chamber depth may be estimated during examination with the slit-lamp, several techniques for quantitating this parameter have been proposed. Van Herick et al.⁶⁴ developed a technique by comparing the peripheral anterior chamber depth to the thickness of the adjacent cornea. This is commonly referred to as the Van Herick technique. According to him the depth can be divided into 4 grades. When the peripheral anterior chamber depth is less than one fourth of the corneal thickness, the anterior chamber angle may be potentially occludable.

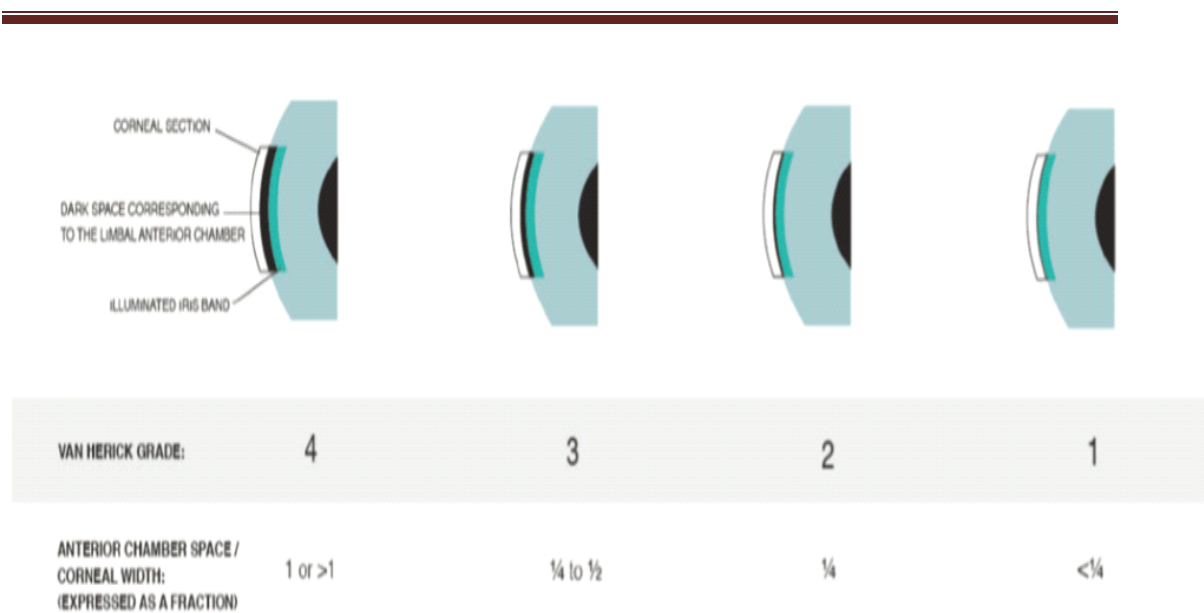


Figure 5: Slit-lamp examination of the peripheral anterior CHAMBER. (A) If the distance between the iris surface and the corneal endothelium is equal to the corneal thickness, the angles are likely to be deep. (B) Conversely, if the distance is less than one-fourth of the corneal thickness, the angles are likely to be narrow.

Gonioscopy

When the peripheral anterior chamber depth is thought to be shallow (i.e., less than one fourth of the corneal thickness by Van Herick slit-lamp examination), careful gonioscopic examination of the angle is required. This is best accomplished with a Zeiss four-mirror lens or similar goniolens. If 180 degrees or more of the angle is closed (i.e., trabecular meshwork is not visible), it constitutes the definition of an occludable angle, and it is important to use compression gonioscopy to determine whether the closure is appositional or synechial.

Numerous grading systems have been suggested in an attempt to correlate gonioscopic appearance with the potential for angle-closure. Scheie⁷ proposed

a system based on the extent of the anterior chamber angle structures that can be visualized .He observed a high risk of angle closure in eyes with grade III or IV angles. Shaffer⁶⁵ suggested using the angular width of the angle recess as the criterion for grading the angle and attempted to correlate this with the potential for angle-closure.

Shaffer’s gonioscopic classification

Angular Grade	Width (in degrees)	Grade	Clinical Interpretation
Wide Open Angle	45-35	4	Angle closure impossible in both Grades 3 and 4
Narrow Angle	35-20	3	Angle closure possible
Narrow Angle, extreme	20	2	Angle closure probable, eventually
Narrow Angle, slit	10 or less	1	Critically narrowed angle, quite possibly against the trabecular meshwork beyond Schwalbe’s line
Narrow angle, partial or complete closure	0	0	Angle closed in part or all of circumference

TABLE: 2 Shaffer’s Gonioscopic Classification (based on structures visible).

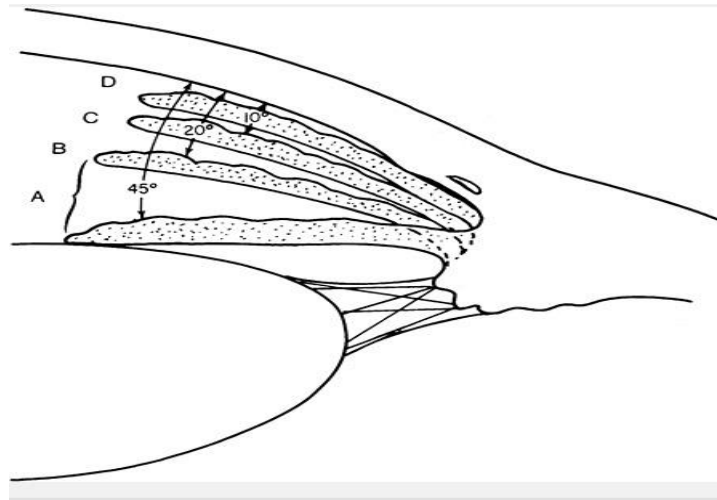


Figure 6: Shaffer's Gonioscopic Classification of the anterior chamber angle is based on the angular width of the angle recess. The angular width and clinical interpretation are given for each of the examples. A: Wide open (20 to 45 degrees): closure improbable. B: Moderately narrow (10 to 20 degrees): closure possible. C: Extremely narrow: closure possible. D: Partially or totally closed: closure present

CLINICAL FINDINGS DURING AN ACUTE ATTACK

The patient who presents during an acute angle-closure attack will typically have marked IOP elevation in the range of 40 to 60 mm Hg or more, with a profound reduction in central visual acuity. Digital palpation can reveal a very firm (i.e., rock-hard consistency) eye compared with the fellow eye, which feels much softer.

External Examination

Characteristic findings include conjunctival hyperemia, a cloudy cornea, and an irregular (usually vertically oval), mid-dilated, fixed pupil.

The pupillary change is thought to result from paralysis of the sphincter, which apparently is caused by a reduction in circulation induced by the elevated IOP and possibly by degeneration of the ciliary ganglion.

Slit-Lamp Examination

This step of the evaluation confirms the presence of the corneal edema. The corneal edema usually clears after the pressure is normalized, although this is not always the case. Specular microscopic examination has revealed significant corneal endothelial cell loss in these cases, which correlates with the duration of IOP elevation the degree of visual field loss, a large cup-disc ratio, and previous intraocular surgery.

The anterior chamber is shallow, but it typically is formed centrally with anterior bowing of the mid-peripheral iris, often making contact with peripheral cornea.

Aqueous flare is often present. Other findings may include pigment dispersion, sector atrophy of the iris, posterior synechiae, and glaukomflecken.

Gonioscopy

It is essential to confirm the diagnosis of angle-closure glaucoma by demonstrating a closed anterior chamber angle. If gonioscopy is not possible because of persistent corneal edema, gonioscopy of the fellow eye may provide useful information if it reveals an extremely narrow angle. Peripheral anterior synechiae may also be present, and documenting the presence and

extent of the synechiae is important in establishing the nature of the angle-closure glaucoma and in selecting the appropriate treatment

Fundus Examination

The optic nerve head may be hyperemic and edematous in the early stages of the attack. In a study of human eyes with a history of angle-closure glaucoma, pallor without cupping was seen in eyes after acute attacks, but pallor and cupping occurred in chronic cases. Central retinal vein occlusion may also occur during acute angle-closure glaucoma⁶⁶.

Visual Fields

Visual field changes associated with an acute elevation of IOP most often show nonspecific constriction. In one study of 25 patients with acute angle-closure glaucoma that had been surgically corrected, the most common field defect was constriction of the upper field, whereas another revealed nerve fiber bundle defects in 7 of 18 acute and 9 of 11 chronic cases⁶⁶.

MANAGEMENT:

a) PRIMARY ANGLE CLOSURE SUSPECT (PACS)

Provocative tests like prone dark room test and mydriatic provocative test is done to infer about the angle. A positive provocative test indicated that angle is capable of spontaneous closure. In such cases prophylactic treatment with laser known as Laser peripheral iridotomy is warranted and after that a periodic follow up should be advised and patient should be educated about the symptoms of the disease in case it progresses to angle closure.

b) PRIMARY ANGLE CLOSURE (PAC)

Basis for treatment:

It is directed towards three main goals:

- 1) Rapid breaking of the attack using medical, laser or surgical therapy.
- 2) Performance of laser or surgical iridectomy after acute attack has been subsided
- 3) Evaluation for the treatment of the fellow eye

Available Treatment Options

a) Medical (Pharmaceutical)

Pharmaceuticals that are used in the management of acute attack include

topical, oral, and intravenous agents. Topical agents include miotics (Pilocarpine), beta- adrenergic blockers, an alpha- adrenergic agonist (Apraclonidine), and steroids. Oral agents that may be used are carbonic anhydrase inhibitors (CAIs) and hyperosmotics. Hyperosmotics and CAIs may also be administered intravenously.

Beta-blockers- If the patient has no contraindications, any of the nonselective beta blocker may be used, with Timolol, 0.5% probably most utilized. Betaxolol 0.25% should be used in patients with pulmonary contraindications. beta blocker is one drop initially, re continued as one drop every 12 hours until LPI is formed

Alpha-adrenergic agonists- Approved in laser procedures to prevent IOP spike, Apraclonidine (1%) is an adjunct therapy in angle closure. It is an alpha-adrenergic agonist that lowers IOP by decreasing aqueous production. The usual dose, one to two

drops in the affected eye at the time of diagnosis, may be repeated once in 1 hour if necessary.

Oral carbonic anhydrase inhibitors- An oral CAI should be given immediately upon diagnosis when the patient is not nauseated. A 500 mg dose (two 250 mg tablets) of acetazolamide (Diamox) is most commonly used. The 500 mg Diamox Sequel should be avoided because it is a timed-release formulation, and, therefore, it has a slower onset of action. Acetazolamide should be avoided in patients with kidney problems for whom 100 mg of methazolamide (Neptazane) becomes the CAI treatment of choice. CAIs are sulfa- based drugs and should be avoided in allergic patients. When the patient is nauseous, 500 mg of intravenous acetazolamide should be administered. An antiemetic suppository may be used with oral medication to reduce nausea and avert the need for intravenous CAIs.

Oral hyperosmotic agents- The most effective means of lowering IOP during acute angle closure attacks are oral hyperosmotic agents. If the patient is not nauseated or vomiting, 50% glycerin (Osmoglyn) may be administered in a dose of 1.5ml/kg body weight. Because it is not metabolized, 45% isosorbide can be substituted in equal doses for glycerin in patients with diabetes mellitus.^{67,68,69,70} In recent years, the use of lasers has taken over as the procedure of choice in most case

b) Laser Treatment

Laser peripheral iridotomy-

Previously a study reported that approximately 30% of PACS eyes had plateaued iris prior to LPI, and this condition persisted in 75% of such eyes after LPI. Another study,

in an Asian cohort, found that 30% of PACG eyes previously treated with LPI⁷¹ had plateaued iris. This implies that a mechanism other than pupillary block may play a significant role in the occurrence and progression of angle closure. One non-pupillary block mechanism seen in PACS, PAC and PACG eyes with plateau iris is bunching of the peripheral iris resulting in closure of anterior chamber despite a patient iridotomy. The suggested mechanism of this effect is an anteriorly dislocated and/or large ciliary body that serves as contact between the iris and the angle. In such eyes, Laser peripheral iridotomy might help to eliminate appositional angle closure and widen ACA, because iridoplasty pulls the peripheral iris away from the angle.

General indications for laser peripheral iridotomy include the following: Acute and chronic angle closure, phacomorphic glaucoma and nanophthalmos. Further, the technique may be used as an adjunctive method to deepen the anterior chamber, facilitating selective laser trabeculoplasty. One histopathological study suggested that laser peripheral iridotomy not only induced short term thermal shrinkage of stromal collagen, but the contraction effect may persist long-term mediated by fibroblast like cells.

Conventional LPI used an argon laser to first create a contraction burn; the laser was activated at a setting of 200 to 250mw with spot size of 500micron meter for 0.6 seconds. In addition, a penetrating burn was achieved using argon laser at a setting of 1000mw with a spot size of 50-micron meter for 0.05 seconds. In LPI with iridoplasty the conventional procedure was followed by iridoplasty in the same session, during which the argon laser was used at a setting of 200 to 250 mW for 0.6 seconds, which created burn spots on the peripheral iris alongside the limbus

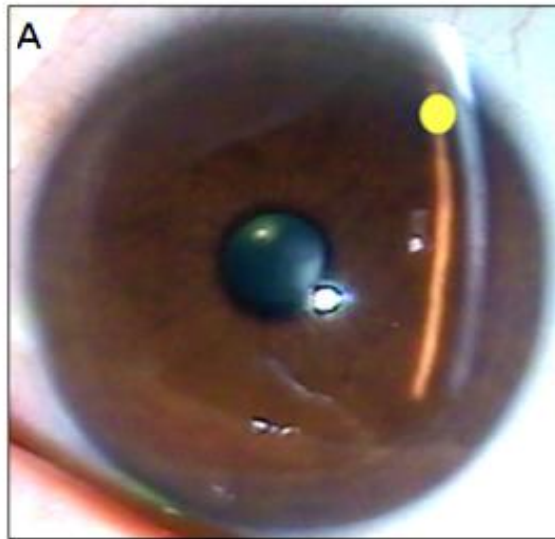


Fig 7: Conventional Laser peripheral iridotomy (LPI)

Complications following LPI are not uncommon; however, they are not usually sight-threatening. A rise in postoperative IOP may occur, but can be minimized by prophylaxis. Transient anterior uveitis is very common but typically resolves with topical steroid treatment. Blurred vision occurs frequently after LPI secondary to released pigment, cell and flare, or microhyphema. The resolution of blurred vision is usually rapid and spontaneous. Hemorrhaging, which can occur when the Neodymium:Yttrium-aluminum-garnet Nd:YAG laser is used for iridotomy, can usually be controlled by the application of slight digital pressure to the globe. There are no reports of serious complications related to the hemorrhaging. Retinal damage is a rare but potentially severe complication of LPI. Use of an iridotomy lens, careful focusing of the laser, and direction of the beam away from the fovea minimize this risk. The most common "serious" complication is closure of the iridotomy. Closure

rates following argon LPI's of up to 40 percent have been reported. Larger peripheral iridotomies with the argon laser and control of inflammation can minimize closure. Closure is very rare with the Nd:YAG laser, a leading reason many practitioners choose the Nd:YAG over the argon laser for LPIs.

c) Filtering Surgery: Trabeculectomy

Carain first described Trabeculectomy in 1980. It is indicated as a treatment for primary angle closure with peripheral anterior synechiae involving more than 270⁰, any POAG not controlled by medical treatment, congenital and developmental glaucoma and secondary glaucoma, refractive to medical therapy. In this a new fistula or channel is created for aqueous humour to flow. A traction suture (placed partial thickness through the peripheral clear cornea) is often used for adequate exposure of the surgical site (superior quadrants of the eye). A conjunctival peritomy is created to expose the superior bare sclera. This peritomy may be limbal based or fornix based. Gentle cautery is used to achieve hemostasis. A partial thickness scleral flap is created in the superior sclera, hinged at the limbus. There are multiple variations in shapes (rectangular, triangular, trapezoidal) and size of this flap. The scleral flap is dissected forward until the bluish gray zone at the limbus is exposed. Dissection of the subconjunctival space to provide a pathway for aqueous flow is then performed.

A paracentesis is created in the peripheral clear cornea prior to creating an ostomy into the anterior chamber from underneath the scleral flap. Viscoelastic material may be injected to stabilize the intraocular pressure as the ostomy is created to avoid anterior chamber shallowing. There are several ways to create the ostomy underneath the scleral flap. A blade is first used to enter the anterior chamber from

just behind the hinge of the scleral flap. The entrance into the anterior chamber is then enlarged using the blade, vannas scissors, and/or a Kelly punch device. Often, a peripheral iridectomy is created at this point, using forceps to pull the peripheral iris through the ostomy site, and scissors to create the iridectomy. In pseudophakic eyes, some surgeons omit this surgical step. Sutures (usually 9-0 or 10-0 nylon) are then used to close the scleral flap. The sutures may be placed in an interrupted manner, or releasable sutures may be placed. The flap should be closed tightly enough to allow the anterior chamber to remain formed, but loosely enough to allow for aqueous drainage at the edges of the scleral flap. The conjunctival peritomy is then closed using absorbable or nylon sutures. A subconjunctival injection of corticosteroids may be given at the end of the surgical procedure.

C) ABSOLUTE GLAUCOMA

It is a painful blind eye so various modalities that can be used for the treatment include, retrobulbar alcohol injection, cyclocryotherapy or cyclophotocoagulation each aiming at destruction of ciliary epithelium and in case pain is not relieved with conservative management enucleation can be considered

MATERIALS AND METHODS

MATERIALS AND METHODS

SOURCE OF DATA

Minimum of 56 eyes in suspects of primary angle closure visiting ophthalmology out patient department at R.L. JALAPPA HOSPITAL AND RESEARCH CENTRE, TAMAKA , KOLAR attached to SRI DEVARAJ URS MEDICAL COLLEGE between December 2014 and July 2015 were taken. These patients underwent LPI and were followed up for 1 year till august 2016.

SAMPLE SIZE CALCULATION

Sample Size – 56
Mean = 11.3
Standard Deviation = 0.6
Alpha Error At 1% and Power At 80%
11 As Null Hypothesis
5 % Drop Out Rate

STUDY DESIGN

This was a Prospective study.

INCLUSION CRITERIA:

Patients with no visibility of the posterior trabecular meshwork for at least 270 degrees [equivalent to Shaffer grade 0 or 1] with

- No synechial changes
- Normal intraocular pressure (IOP)
- Normal optic disc features

EXCLUSION CRITERIA:

- Secondary angle closure glaucoma
- Significant retinal pathology
- Previous intraocular surgery
- Any grade of cataract

METHOD OF COLLECTION OF DATA:

Fifty-six eyes fulfilling the criteria were included in this study. All the patients underwent detailed evaluation comprising of history and examination that included visual acuity by Snellen's chart, anterior segment examination with slit lamp biomicroscopy, applanation tonometry, non indentation gonioscopy using 3 mirror gonioscope, stereo-bio microscopic examination of optic disc using +90D lens, keratometry, visual fields and A-Scan biometry.

The patients were first graded on slit lamp examination using Van Herick's grading and patients with grade 0 or 1 then underwent non-indentation gonioscopy. The patients showing no visibility of posterior trabecular meshwork of more than 270 degrees that was equivalent to modified Shaffer's grade 0 or 1 were selected for the procedure.

The selected patients then underwent Laser Peripheral Iridotomy using ZEISS ND-YAG laser. Pilocarpine 2 percent was used for miosis. The procedure was performed under topical anesthesia by instilling the paracaine eye drops, using an Abraham

iridotomy lens and a coupling agent. 11'0' clock or 1'0' clock site was preferred, as both these sites, would be covered by upper eyelid and helps in preventing any post LPI diplopia to the patient. After focusing the Nd: YAG laser on the front surface of iris, in q switched mode energy 5 to 7mj with a run of 3 bursts per activation, with a total power of 15 to 21 mj per shot were used.

Patients were examined for 1 year according to following schedule:

Before the procedure, 1st week, 1 month, 6 month and 1 year after LPI. The parameters which were assessed and noted in the follow ups were, Intra ocular pressure, Anterior chamber depth, Anterior chamber angle, Axial length, Lens thickness, Best corrected visual acuity and PACS to PACG conversion.

An informed consent was obtained from the patient after explaining the complete procedure of examination prior to the procedure.

STATISTICAL ANALYSIS:

Data was compiled in Microsoft excel after coding and was analyzed using SPSS 20 version software. Frequencies and proportions and quantitative data represented qualitative data by mean and standard deviation. Chi-square test was used as test of significance for qualitative data. Independent t test to measure the mean difference. P value < 0.05 was considered as statistically significant.

OBSERVATIONS & **RESULTS**

RESULTS

A total of 56 eyes with occludable angle fulfilling all inclusion and exclusion criteria were offered laser peripheral iridotomy.

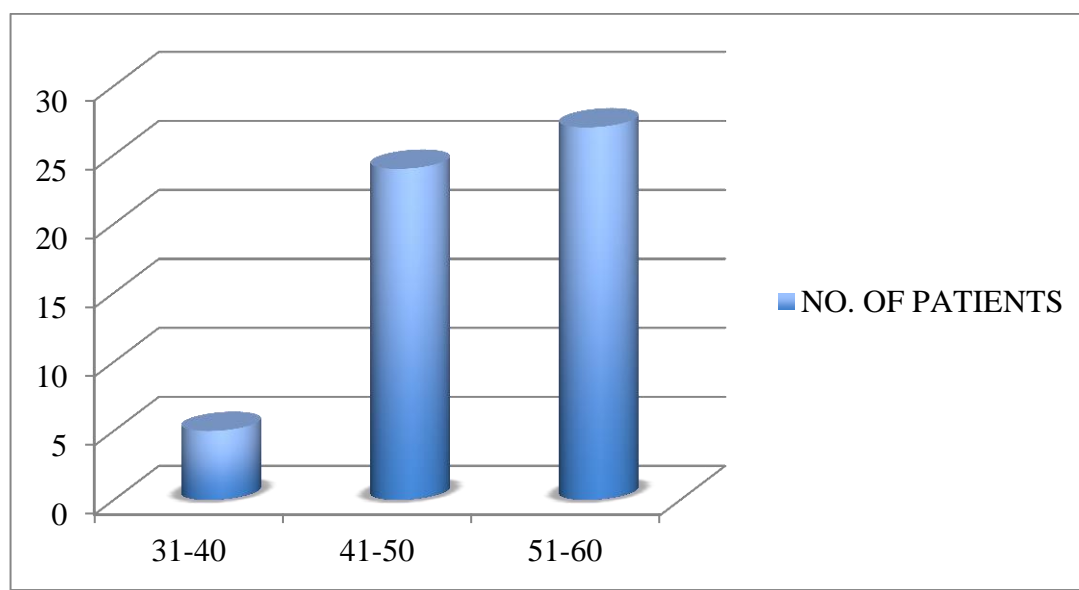
A) CHARACTERISTICS OF PATIENTS

1) AGE

In this observational clinical study, the mean age of the patients included in the study fell between 49.54 ± 6.05

Age in years	No. of patients	%
31-40	5	8.9
41-50	24	42.9
51-60	27	48.2
Total	56	100.0

Table 3: Age Distribution of Patients

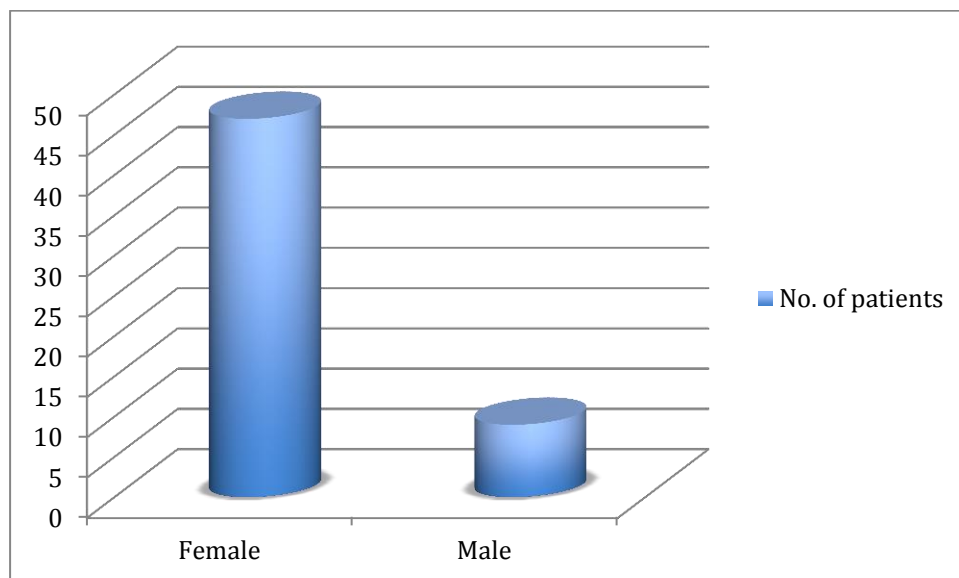


Graph 1: Age Distribution of Patients

2) GENDER

Gender	No. of patients	%
Female	47	83.9
Male	9	16.1
Total	56	100.0

Table 4: Gender Distribution of Patients Studied



Graph 2: Gender Distribution of Patients Studied

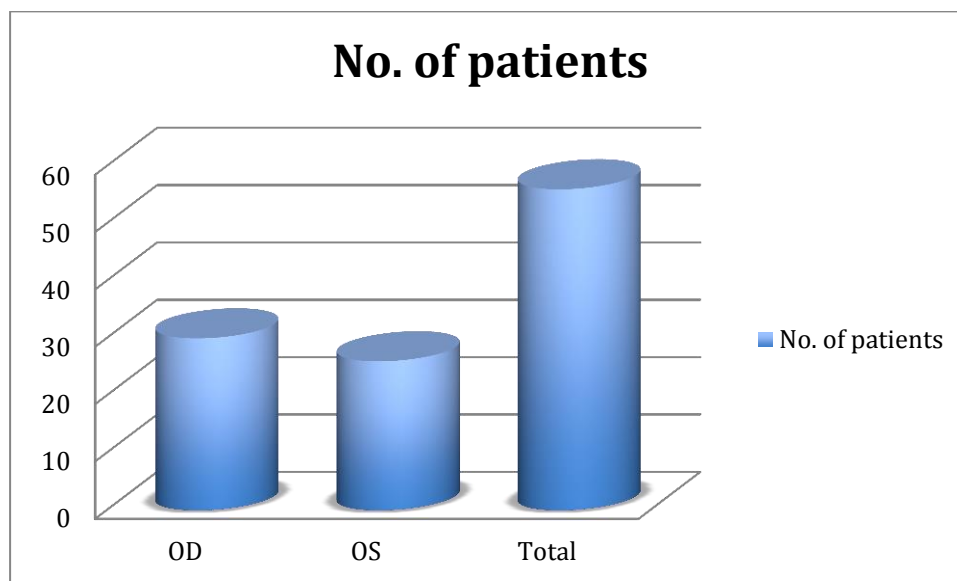
Majority of the patients were female that accounted to 83.9% of the total while male patients constituted only 16.1% of the total studied cases.

3) LATERALITY

Out of the total 56 eyes studied 53.6% eyes were right and 46.4% eyes were left

Eye involved	No. of patients	%
OD	30	53.6
OS	26	46.4
Total	56	100.0

Table 5: Eye Laterality of cases studied



Graph 3: Eye Laterality of cases studied

B) BEST CORRECTED VISUAL ACUITY

Best corrected distant V/A(LogMAR)	Min-Max	Mean ± SD
Before LPI	-0.10-0.20	0.03±0.06
1 week	-0.10-0.20	0.03±0.06
1 month	-0.10-0.30	0.03±0.07
6 months	-0.10-0.30	0.03±0.07
1 year	-0.10-0.90	0.08±0.18

TABLE 6: Best Corrected Distant V/A (LOGMAR)

BCVA in 10× log MAR scale was 0.03±0.06 at baseline for all eyes. At the last follow up, that was at 12 months, the baseline shifted to 0.08±0.18 (29.5%). 2 eyes lost 3 or more lines in the duration of 1 year.

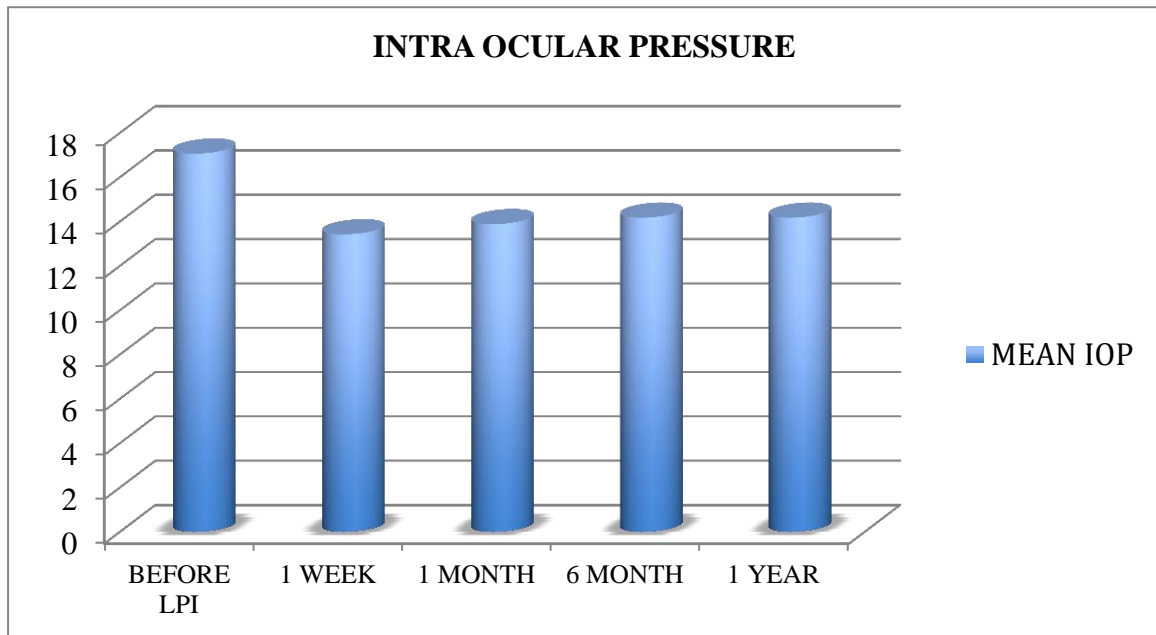
C) INTRAOCULAR PRESSURE

The iridotomy was patent in all except 2 eyes after the single laser treatment session. The average size of iridotomy was approximately 0.4mm. 2 patients were found to have non-patent iridotomy site after 1 month of follow up. These patients showed an increased IOP reading by 2 mm of Hg at 1 month follow up in comparison to 1 week follow up reading of IOP. A repeat laser was done and a patent iridotomy site was successfully created, and the data were collected 1 week after the repeated procedure.

An immediate pressure spike (IOP elevation of 5 mmHg or more 1 hour after LPI) was observed in 6 eyes, which accounted to 10.7% of the total studied cases. Intraocular pressure elevation was around 4 mm of Hg in 2 eyes and around 6 to 8 mm of Hg in 4 eyes. All patients with IOP elevation were treated with acetazolamide 250mg and apraclonidine 0.5% which brought IOP under control within next 24 hours.

Intra ocular pressure (mm of Hg)	Min-Max	Mean \pm SD	difference	t value	P value
Before LPI	14.00-20.00	17.07 \pm 2.02	-	-	-
1 week	10.00-20.00	13.43 \pm 2.55	3.643	8.725	<0.001**
1 month	10.00-22.00	13.89 \pm 3.27	3.179	6.510	<0.001**
6 months	10.00-24.00	14.18 \pm 3.23	2.893	5.058	<0.001**
1 year	10.00-28.00	14.18 \pm 4.06	3.013	5.015	<0.001**

TABLE 7: Intra Ocular Pressure (mm of hg)



Graph 4: Intra Ocular Pressure (mm of hg)

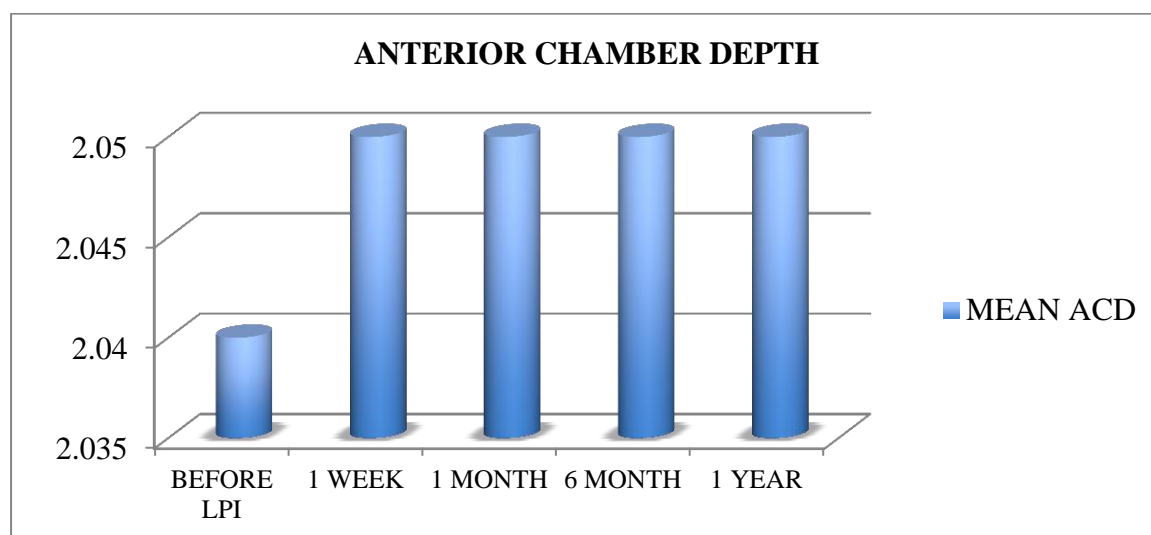
The mean IOP of the enrolled participants before LPI treatment was 17.07 ± 2.02 mm of Hg. After LPI, the IOP decreased by an average of 3 mmHg in treated eyes at 1 month follow up. In majority of the patients IOP remained under control even after 1 year of follow up. 2 eyes, which showed uncontrolled, rise in IOP, were the cases which progressed to PACG even after the procedure.

IOP evaluation using Goldmann's applanation tonometer showed significant decrease ($P < 0.0001$, paired t test) in cases studied, before and after the procedure.

D) ANTERIOR CHAMBER DEPTH

Anterior chamber depth (mm)	Min-Max	Mean \pm SD	difference	t value	P value
Before LPI	2.00-2.09	2.04 \pm 0.02	-	-	-
1 week	2.00-2.12	2.05 \pm 0.02	-0.011	-7.197	<0.001**
1 month	2.00-2.12	2.05 \pm 0.03	-0.009	-5.198	<0.001**
6 months	2.00-2.12	2.05 \pm 0.03	-0.009	-5.293	<0.001**
1 year	2.00-2.12	2.05 \pm 0.03	-0.009	-5.396	<0.001**

Table 8: Anterior Chamber Depth (mm)



Graph 5: Anterior Chamber Depth (mm)

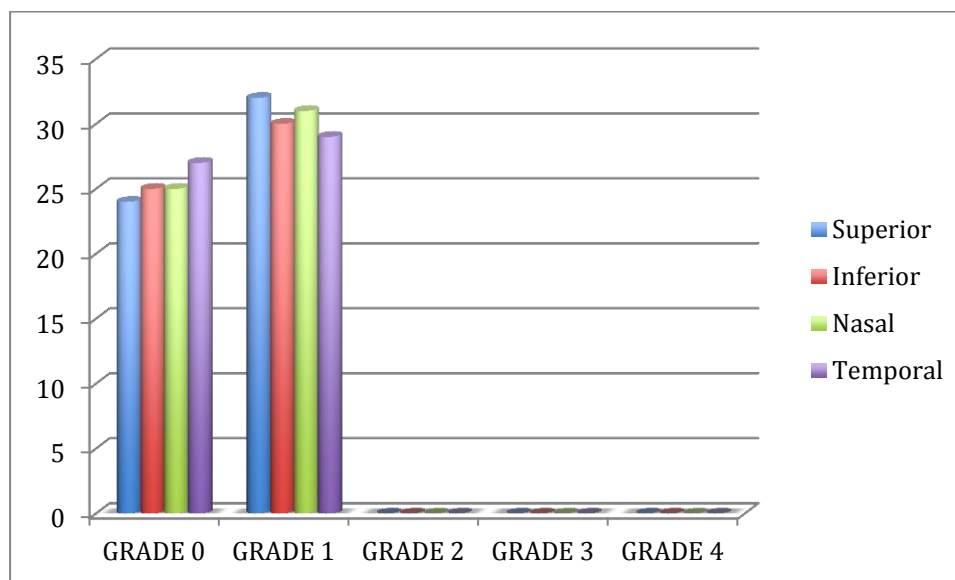
Peripheral ACD evaluation using van Herick method and A-scan biometry showed significant widening after LPI ($P < 0.001$; t paired test) between pre-LPI and the follow-up cases.

E) ANTERIOR CHAMBER ANGLE

The Shaffer angle width, analyzed using gonioscopy done by 3 mirror, increased significantly in all 4 quadrants especially both superior and inferior quadrants ($P < 0.001$, paired t test).

QUADRANT	GRADE 0	GRADE 1	GRADE 2	GRADE 3	GRADE 4
Superior	24	32	0	0	0
Inferior	25	30	0	0	0
Nasal	25	31	0	0	0
Temporal	27	29	0	0	0

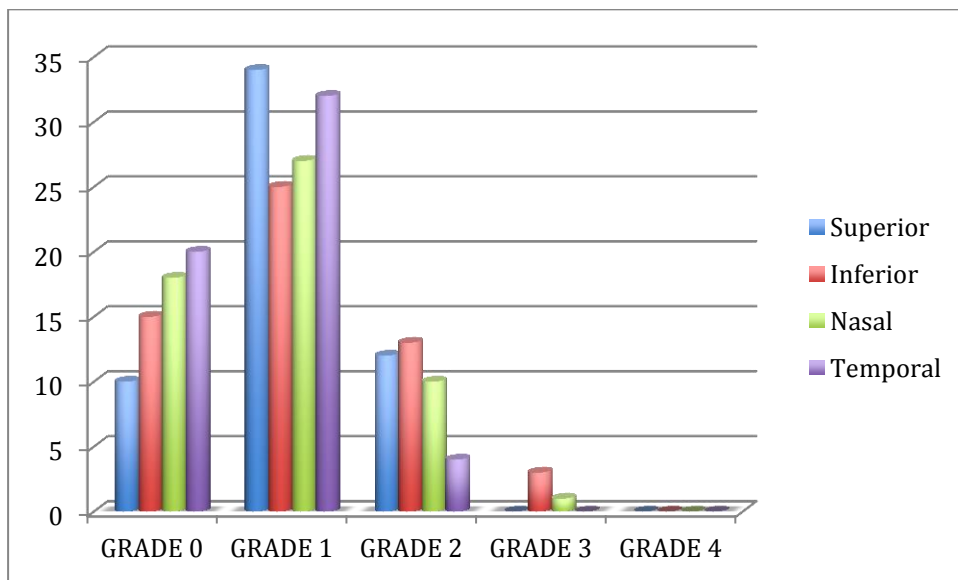
Table 9: Anterior Chamber Depth: An assessment before LPI



Graph 6: Anterior Chamber Depth: An assessment before LPI

QUADRANT	GRADE 0	GRADE 1	GRADE 2	GRADE 3	GRADE 4
Superior	10	34	12	0	0
Inferior	15	25	13	3	0
Nasal	18	27	10	1	0
Temporal	20	32	4	0	0

Table 10: Anterior Chamber Depth: An assessment after LPI



Graph 7: Anterior Chamber Depth: An assessment after LPI

Patients taken in the study fell in grade 0 or 1 before LPI in all the quadrants. There were no patients that fell in grade 4. After the procedure widening of angle was seen, especially in superior quadrant. Few patients from grade 0 moved to grade 1. After the procedure majority of the patients fell in grade 1. The widening of angle was statistically significant ($P < 0.005$, paired t test).

E) AXIAL LENGTH

Axial Length (mm)	Min-Max	Mean \pm SD	difference	t value	P value
Before LPI	22.12-22.81	22.43 \pm 0.17	-	-	-
1 week	22.12-22.81	22.42 \pm 0.16	0.003	1.791	0.079+
1 month	22.12-22.81	22.43 \pm 0.17	-	-	-
6 months	22.12-22.81	22.43 \pm 0.17	-	-	-

Table 11: Axial Length (mm)

The axial length, which was calculated using A-scan, did not show any significant change ($P > 0.079$, paired t test) in the value before and after LPI

F) LENS THICKNESS

Lens Thickness (mm)	Min-Max	Mean \pm SD	difference	t value	P value
Before LPI	4.36-4.90	4.67 \pm 0.14	-	-	-
1 week	4.36-4.92	4.68 \pm 0.14	-0.008	-1.846	0.070+
1 month	4.36-4.90	4.67 \pm 0.14	-	-	-
6 months	4.36-4.90	4.67 \pm 0.14	-	-	-
1 year	4.36-4.90	4.67 \pm 0.14	-	-	-

Table 12: Lens Thickness (mm)

Similar to axial length, lens thickness also did not show any significant change ($P > 0.070$, paired t test)

G) PACS PROGRESSION TO PACG

PACS TO PACG	Before LPI	1 week	1 month	6 months	1 year
PACS	56(100%)	56(100%)	56(100%)	56(100%)	54(96.4%)
PACG	0(0%)	0(0%)	0(0%)	0(0%)	2(3.6%)
Total	56(100%)	56(100%)	56(100%)	56(100%)	56(100%)

TABLE 13: PACS to PACG

Out of the 56 eyes 5 eyes developed PAC with synechial changes, out of which 2 eyes in 1year duration progressed to PACG. In these 2 eyes, both showed visual field and optic disc changes during the follow up period of the study.

Visual Fields	Before LPI	1 week	1 month	6 months	1 year
WNL	56(100%)	56(100%)	56(100%)	54(96.4%)	54(96.4%)
Visual field changes	0(0%)	0(0%)	0(0%)	2(3.6%)	2(3.6%)
Total	56(100%)	56(100%)	56(100%)	56(100%)	56(100%)

Table 14: Visual Fields

Fundus Changes	Before LPI	1 week	1 month	6 months	% change
WNL	56(100%)	56(100%)	56(100%)	56(100%)	54(96.4%)
Optic disc changes	0(0%)	0(0%)	0(0%)	0(0%)	2(3.6%)
Total	56(100%)	56(100%)	56(100%)	56(100%)	56(100%)

Table 15: Fundus Changes

DISCUSSION

DISCUSSIONS

In the present study, we aimed to investigate the efficacy of the LPI in the management of the subjects with PACS by assessing anterior chamber parameters and the progression of PACS to PACG within the follow up duration of 1 year. This study showed significant changes in ACD, ACA and IOP. However, the changes in axial length, lens thickness did not reach the significant level. Furthermore, LPI resulted in significant widening of the angles in 2 quadrants, superior and inferior based on the gonioscopy examination done using Zeiss 3-mirror lens. The present study denoted that there is significant decrease in the number of cases, which developed angle closure glaucoma in the duration of 1 year after the prophylactic treatment by LPI.

Study	Present Study	Alireza Esmail et al (2013)	Ricardo J. Cumba et al (2013)
No. of cases studied	56	48	79
Mean age in years	49.54±6.05	57.04±8.65	64.6 ± 12.5

Table 16: Age distribution of patients studied : Comparision with other studies

Mean age of the subjects in the present study was **49.54±6.05**, which was lower in comparision to other studies.

In **Alireza Esmail et al** study⁷² mean age was 57.04±8.65 while in **Ricardo J. Cumba et al**⁷³ Study the mean age was 64.6 ± 12.5.

Due to lower age group in present study, deterioration of vision due to any grade of cataract was not present. The variation in best-corrected visual acuity was accounted solely to angle closure glaucoma.

In present study we got a better analysis between the LPI and changes in the anterior chamber parameters unlike some of the other studies namely **Ricardo J Cumba et al**⁷³, as they included patients who had various grades of cataract and during the follow up period of the study, those patients underwent cataract surgery.

Study	Present Study	Alireza Esmail et al (2013)	Mingguang He et al(2005)
No. of cases	56	48	72
No. of Males	9(17.1%)	12(25%)	20(27.78%)
No. of Females	47 (83.9%)	36(75%)	52(72.22%)

Table 17 : Sex distribution among Pacs: Comparison with other studies

Females are more prone to angle closure glaucoma according to the various studies done worldwide.

The present study showed higher PACS in females, with **Male: Female ratio of 1: 5.22**, which is in concordance with other studies.

In our study we had 83.9% of patients as female which was similar to other studies like **Alireza Esmaeil et al (2013)**⁷² which had 75% females and **Mingguang He et al(2005)**⁷⁴ which had 72.22% patients as female

Study	Present Study	Ramani et al(2008)	Thomas et al
Mean follow up period	12 months	24 months	60 months

Table 18 : Follow up period: Comparison with other studies

The follow up period of our study was 12 month in comparison to other studies, which had been followed up for minimum of 2 years⁷⁵.

Some of the other studies like **Thomas et al**⁷⁶ had 5-year follow-up period. **Ye et al**⁷⁷ was a study done on chinese population in which follow up was done for 6 years.

Another study done on Eskimos⁷⁸, analyzed PACS progression to PAC over a 10-year follow-up period.

Study	Present Study	Mingguang He et al(2005)	Ricardo et al
Mean IOP before LPI(mm of Hg)	17.07±2.02	14.4	15.4
Mean IOP after LPI(mm of Hg)	14.18±4.06	11.3	11.35

Table 19 : Change in IOP: Comparison with other studies

The PACS patients in present study just like **Mingguang He et al**⁷⁴ and **Ricardo et al**⁷³ study did much better in IOP control after LPI. IN our study there was change in mean IOP of the enrolled participants by an average of 3mm of hg which was statistically significant ($P < 0.001$) and coincided with the previous finding of other studies like **Peng et al.**⁷⁹

Out of 56 eyes, which underwent LPI, 6 eyes showed a sudden spike at 2 hours after the procedure, all these patients were administered Apraclonidine 0.5% eye drops and acetazolamide tablets 250 mgs, which controlled IOP in 24 hours. This finding was consistent with study done by **Krupin et al**⁸⁰, which reported an IOP increase from 17.4±3.4 mmHg to 23.5±10.3 mmHg at 1 to 2 hours and then a decrease to 16.4±3.9 mmHg at 24 hours in European eyes.

In present study, 5 cases showed increase in IOP at 1 year follow up, out of these 2 cases had IOP above the normal limits, these values were not statistically significant.

These were the cases, which progressed to angle closure glaucoma. In these two cases, in spite of patent LPI site, IOP was not controlled even after using of 2 IOP lowering drugs and as a final outcome surgery was done to control the IOP. This coincides with the study done on patients of angle closure spectrum, by **Ricardo J Cumba et al**⁷³, which concluded that LPI alone does not prevent patients from requiring additional treatment or surgery.

In present study we concluded that LPI is effective way of keeping IOP under control in PACS cases.

Study	Present Study	Mingguang He et al(2005)	Ricardo et al
Mean ACD before LPI(mm)	2.04±0.02	2.05	2.06±0.19
Mean ACD after LPI(mm)	2.05±0.03	2.04	2.08±0.19

Table 20 : Change in ACD : Comparison with other studies

The results of present study showed that there was significant increase in ACD after the LPI. The table shows significant widening of ACD after LPI ($P<0.001$; t paired test) evaluated using A-scan biometry.

Previous studies reported inconsistent results for the changes in central ACD after the procedure.

Evaluation of peripheral ACD showed widening after LPI in all the follow-up groups up to 2 years in a study done by **Ramani et al**⁷⁵. An earlier study of acute angle

closure glaucoma patients showed similar result. As in previous studies, there was no significant variation in central ACD. Other follow-up studies, in PACS showed similar findings.

Mingguang He et al⁷⁴, a study done on Chinese population and another study **López-Caballero et al**⁸¹ study showed significant deepening of the ACD after LPI.

Li et al⁸² and **Antoniazzi et al**⁸³ study and **Ricardo et al**⁷³ study the increase in ACD did not reach the significant level.

STUDY	Present Study	Alireza Esmail et al	Mingguang He et al(2005)
% Shaffer’s Grade changed	59%	56.3%	72.4%
% Shaffer’s Grade Unchanged	41%	43.7%	20.3%

Table 21 : % Change in ACA: Comparison with other studies

Gonioscopy examination is done to visualize ACA and detect closed and most likely occludable angles. Gonioscopic angle grading system is reliable, but is subjective in nature that makes the comparison challenging and examiner dependent. In the present study, there was an overall increase in Shaffer angle grade, especially in superior and inferior quadrants.

In present study cases evaluated belonged to grade 0 and 1 before LPI. There were no cases in grade 4. After the procedure maximum patients were found to be in grade 1, there was statistically significant ($p < 0.004$) widening of angle after LPI

In the present study, the narrowest angle in pre-LI measurements by Gonioscopy was the superior quadrant and it also had the highest successful angle opening after the LPI. It is believed that the widening of the angle is due to an overall displacement of the iris after the LPI. As the superior angle was the narrowest in the beginning, higher degree of iris movement is expected in this quadrant compared to the other quadrants.

This finding correlates with the study done by **Alireza Esmacil et al**⁷², which showed the similar results related to inferior quadrant. Similarly study done by **Ramani et al**⁷⁵, also showed the widening of angle in post LPI patients in comparison to pre LPI.

Mingguang He et al⁷⁴ in their study also showed increase of angle width in 72.4% of the cases studied from grade 0 to grade 1

Kaushik et al⁸⁰ in their study had shown that there was variation in the ACA widening in the quadrant in which LPI was done compared to the quadrant opposite to LPI. In the present study, no such variation in the response of the widening of the ACA in any quadrants was found.

In comparison to the present study, a study done on Chinese population, the widening of angle was shown of higher magnitude. This difference between 2 studies could be due to higher severity of the disease in their study. Since in general populations, PACS commonly have wider angle compared to the PACG, we could expect more changes after the LPI in PACG subjects.

In present study, Ocular biometry parameters, namely, AXL and lens thickness , did not show significant variation before LPI and after 1-year follow-up.

This finding correlated to **Mingguang He et al**⁷⁴ study, which also showed no significant increase in axial length and lens thickness. In their study the mean difference of lens thickness and axial length was 0.10 and -0.03 respectively.

However, there was one study done by **Ramani et al**⁷⁴, the LT showed increase after LPI. Other than this study, there was no other study documenting the variation of LT

STUDY	PRESENT STUDY	RICARDO J CUMBA et al	RAMANI et al
% PACS TO PACG CONVERSION	3.5%	8%	28.9%

TABLE 22 : % PACS TO PACG CONVERSION COMPARISON WITH OTHER STUDIES

In present study we have come found that out of total 56 cases which were studied, 5 cases developed angle closure and out of those 5 cases, 2 cases developed angle closure glaucoma, which consituted 3.5% of the total cases studied. Both the cases had visual field and optic disc changes. These cases had increased IOP in 6 months, which was not controlled by LPI and was also not controlled by 2 IOP lowering drugs. These patients underwent additional filtering surgery for controlling of IOP.

These findings coincide with the study done by Ricardo J cumba et al⁷³, which showed that Fourteen eyes (17.7%) had glaucomatous progression during the course of follow up; out of which, 4 eyes demonstrated visual field progression only, 6 eyes optic disc progression only.

In another study done by **Ramani et al**⁷⁵, Fifteen eyes out of 52 eyes (28.9%) developed into PAC with synechial changes. None had acute angle closure attacks with symptoms or raised IOP within 2 years

In present study, this conversion was seen in a follow up period of 1 year, which was comparatively lower than the other studies like **Ricardo J Cumba et al**⁷³, the mean duration from initial PI to progression was 28.9 ± 18.3 months.

In study by **Ramani et al**⁷⁵, 5 developed within 6 months, 4 developed between 6 months and 1 year, 5 developed between 1 and 1.5 years, and 1 developed between 1.5 and 2 years.. No optic disc neuropathy was noticed till 2 years of follow-up

CONCLUSION

CONCLUSION

In our study we found that Laser peripheral iridotomy, is an effective procedure for preventing the conversion of Primary angle closure suspects to Primary angle closure glaucoma.

LPI acts as an alternative pathway for the flow of aqueous humour from posterior chamber to anterior chamber there by increasing anterior chamber depth and widening the angle, thus preventing angle closure attack and subsequent rise in IOP

We have come to a conclusion that eyes with shallow anterior chamber and narrow angles, which are prone for angle closure attack, especially in females above 40 years of age, a prophylactic LPI should be done.

SUMMARY

SUMMARY

- Glaucoma is a leading cause of irreversible blindness throughout the world. Worldwide, it has become the second most common cause of bilateral blindness; the objective of this study is to determine the effectiveness of LPI in PACS.
- In this observational study 56 eyes, which fit in the inclusion and exclusion criteria, were taken and given prophylactic treatment of LPI. Patients were assessed after 1 week, 1 month, 6 month and 1 year of the procedure
- Majority of the patient studied were female (83.9%)
- Mean age of the cases studied was 49.54 ± 6.05
- After the procedure increase in anterior chamber depth was with mean value of 2.05 ± 0.03 after 1 year of follow up.
- There was a significant decrease of IOP, which accounted to an average decrease of 3mm of hg after the procedure.
- In all the quadrants widening of angle with shift of at least 1 grade according to Shaffer's grading was seen after LPI
- There was no significant change in axial length and lens thickness noted before and after the procedure.
- Out of all the patients, 5(8.9%) had angle closure at the end of 6 month follow up and out of these 5, 2(3.5%) patients progressed to angle closure glaucoma with both visual field and optic disc changes at the end of 1 year follow up.
- From the observations of this study, all subjects above forty years especially females should be screened for narrow angle and if they are found to belong to PACS category then they should undergo LPI as a prophylactic treatment.

BIBLIOGRAPHY

BIBLIOGRAPHY

1. Amini H, Javadi MA, Yazdani S, Pakravan M, Karimian F, Rezaei A, et al. The prevalence of glaucoma in Tehran. *Iran J Ophthalmic Vis Res* 2011;2:93–100.
2. Wang YX, Xu L, Yang H, Jonas JB. Prevalence of glaucoma in north China: the Beijing Eye Study. *Am J Ophthalmol* 2010;150:917–924.
3. Thyelfors B, Nacgrel A-D, Pararajasegaram R. Global data on blindness. *Bull World Health Org* 1995; 73:115-121.
4. Vijaya L, George R, Paul PG, Baskaran M, Arvind H, Raju P, et al. Prevalence of open-angle glaucoma in a rural south Indian population. *Invest Ophthalmol Vis Sci* 2005; 46(12):4461-4467.
5. Quigley HA. Number of people with glaucoma worldwide. *Br J Ophthal* 1996; 80:389-393.
6. Shields MB. *Textbook of glaucoma*, Ed: 5th. Lippincott Williams and Williams;2005
7. Scheie HG. Width and pigmentation of the angle of anterior chamber. A system of grading by gonioscopy. *Arch ophthalmol* 1957;58:510-512.
8. Wilensky JT, Kaufman PL, Frolichstein D. Follow up of angle closure glaucoma suspects. *Am J Ophthalmol* 1993;115:338-346
9. Thomas R, Parikh R, George R, Kumar RS, Muliylil J. Five yer risk of progression of ocular hypetension to primary open angle glaucoma. A population based study. *Indian J ophthalmol* 2003;51:329-333
10. Snow JT. Value of prophylactic peripheral iridectomy on the second eye in angle-closure glaucoma. *Trans Ophthalmol Soc U K.* 1977;97:189–191.

-
11. D.S. Friedman, Who needs an iridotomy?. *Br J Ophthalmol* 2001;85 :1019–1021
 12. R.F. Lowe. Primary angle-closure glaucoma: prevention and early treatment. *Isr J Med Sci* 1972;8:1362–1365
 13. He M, Friedman DS, Ge J, Huang W, Jin C, Lee PS et al. Laser peripheral iridotomy in primary angle closure suspects: biometric and gonioscopic outcomes: the liwan study. *Ophthalmology* 2007 Mar;114:494-500.
 14. Kumar KR, Baskaran M, Ronnie JG, Vijaya. Follow up of primary angle closure suspects after laser peripheral iridotomy using ultrasound biomicroscopy and A-scan biometry for a period of 2 years. *J Glaucoma* 2009 Sep;18:521-527.
 15. Wilensky JT, Kaufman PL, Frohlichstein D. Follow up of angle closure suspects. *Am J Ophthalmol.* 1993;115:338–346.
 16. Gazzard G, Friedman DS, Devereux JG, Chew P, Seah SK. A prospective ultrasound biomicroscopy evaluation of changes in anterior segment morphology after laser iridotomy in Asian eyes. *Ophthalmology.* 2003;110:630–638.
 17. Marraffa M, Marchini G, Pagliarusco A, Perfetti S, Toscano A, Brunelli C, Tosi R, Bonomi L. Ultrasound biomicroscopy and corneal endothelium in Nd: YAG-laser iridotomy. *Ophthalmic Surg Lasers.* 1995;26:519–523.
 18. C.H. Hsiao, C.T. Hsu, S.C. Shen, H.S. Chen. Mid-term follow-up of Nd:YAG laser iridotomy in Asian eyes. *Ophthalmic Surg Lasers Imaging.* 2003;34: 291–298
 19. H.A. Quigley. Long-term follow-up of laser iridotomy. *Ophthalmology* . 1981;88: 218–224

-
20. N. Wang, H. Wu, Z. Fan. Primary angle closure glaucoma in Chinese and Western populations. *Chin Med J (Engl)*. 2002; 115:1706–1715
 21. Varma R, Ying-Lai M, Francis BA, et al. Prevalence of open-angle glaucoma and ocular hypertension in Latinos: the Los Angeles Latino Eye Study. *Ophthalmology*. 2004; 111(8):1439–48.
 22. Sakata K, Sakata LM, Sakata VM, et al. Prevalence of glaucoma in a south brazilian population: Projeto Glaucoma. *Invest Ophthalmol Vis Sci*. 2007; 48(11):4974–4979.
 23. Quigley HA, Broman AT. The number of people with glaucoma worldwide in 2010 and 2020. *Br J ophthalmol* 2002; 90(3):262-267.
 24. Dandona L, Dandona R, Srinivas M, Mandal P, John RK, McCarty CA, et al. Open-angle glaucoma in an urban population in southern India: the Andhra Pradesh eye disease study. *Ophthalmology* 2000; 107(9):1702-1709.
 25. Vijaya L, George R, Baskaran M, Arvind H, Raju P, Ramesh SV, et al. Prevalence of primary open-angle glaucoma in an urban south Indian population and comparison with a rural population. The Chennai Glaucoma Study. *Ophthalmology*. 2008; 115:648–654.
 26. Ramakrishnan R, Nirmalan PK, Krishnadas R, Thulasiraj RD, Tielsch JM, Katz J, et al. Glaucoma in a rural population of southern India: the Aravind comprehensive eye survey. *Ophthalmology* 2003; 110(8):1484-1490.
 27. Tuck MW, Crick RP. The age distribution of primary open angle glaucoma. *Ophthalmic Epidemiol* 1999 Mar; 6(1):84-85.
 28. Hu CN (1989) an epidemiologic study of glaucoma in Shunyi County, Beijing. *Zhonghua Yan Ke Za Zhi* 25:115–119.

-
29. Raviola G, Raviola E. Intercellular junctions in the ciliary epithelium. *Invest Ophthalmol Vis Sci* 1978; 17(10):958-981.
 30. Pederson JE, Gaasterland DE, MacLellan HM. Uveoscleral aqueous outflow in the rhesus monkey: importance of uveal reabsorption. *Invest Ophthalmol Vis Sci* 1977; 16(11):1008-1017.
 31. Inomata H, Bill A. Exit sites of uveoscleral flow of aqueous humor in cynomolgus monkey eyes. *Exp Eye Res* 1977; 25(2):113-118.
 32. Bill A, Phillips CI. Uveoscleral drainage of aqueous humour in human eyes. *Exp Eye Res* 1971; 12(3):275-281.
 33. Drance SM. Angle closure glaucoma among Canadian Eskimos. *Can J Ophthalmol* 1973;8:252-254.
 34. Arkill SM, Lightman DA, Sommer A, et al. The prevalence of glaucoma among Eskimos of Northwest Alaska. *Arch Ophthalmol* 1987;105:482-485.
 35. Aung T, Chew PT. Review of recent advancements in the understanding of primary angle-closure glaucoma. *Curr Opin Ophthalmol* 2002;13:89-93
 36. Perkins ES. Family studies in glaucoma. *Br J Ophthalmol* 1974; 58:529-535.
 37. Spaeth GL. Gonioscopy: uses old and new the inheritance of occludable angles. *Ophthalmology* 1978; 85:222-232
 38. George R, Paul PG, Baskaran M, Ramesh SV, Raju P, Arvind H, et al. Ocular biometry in occludable angles and angle closure glaucoma: a population based survey. *Br J Ophthalmol* 2003; 87(4):399-402.
 39. Iwase A, Suzuki Y, Araie M, et al. The prevalence of primary open- angle glaucoma in Japanese: The Tajimi Study. *Ophthalmology*. 2004; 111:1641–1648.

-
40. Hu Z, Zhao ZL, Dong FT, et al. An epidemiologic investigation of glaucoma in Beijing and Shun-yi County. *Chin J Ophthalmol*. 1989; 25:115–118.
 41. Meyerhof M. Ali at-Tabari's "Paradise of Wisdom," One of the Oldest Arabic Compendiums of Medicine. Cambridge: Cambridge University Press. 1921;12:37–40
 42. Armaly MF, Krueger DE, Maunder L. Biostatistical analysis of the collaborative glaucoma study-Summary report of the risk factors for glaucomatous visual-field defects. *Arch Ophthalmol*. 1980; 98:2163–2171.
 43. Rhee DJ, Katz LJ, Spaeth GL, Myers JS. Complementary and alternative medicine for glaucoma. *Surv Ophthalmol*. 2001; 46:43–55.
 44. Fleming C, Whitlock E, Biel T, Smit B. Primary care screening for ocular hypertension and primary open-angle glaucoma: Evidence Synthesis. Agency for Healthcare Research & Quality, US Preventive Services Task Force. 2005;1:12-15.
 45. Weinreb RN, Healey PR and Topouzis .Glaucoma Screening, WGA consensus series 5. Netherlands .Kugler Publications.2008.
 46. Central corneal endothelial cell counts in children. *Am Intra-Ocular Implant Soc J* 1979; 5:292-300
 47. Herndon LW, Choudhri SA, Cox T, et al. Central corneal thickness in normal, glaucomatous, and ocular hypertensive eyes. *Arch Ophthalmol*. 1997; 115:1137–1141.
 48. Copt RP, Thomas R, Mermoud A. Central thickness in ocular hypertension, primary open-angle glaucoma, and normal tension glaucoma. *Arch Ophthalmol*. 1999; 117:14–26.

-
49. Weizer JS, Stinnett SS, Herndon LW. Longitudinal changes in central corneal thickness and their relation to glaucoma status: an 8 year follow up study. *Br J Ophthalmol*. 2006; 99:732–736
 50. Hamilton KE, Pye DC, Aggarwala S. Diurnal variation of central corneal thickness and Goldmann applanation tonometry estimates of intraocular pressure. *J Glaucoma*. 2007; 16:29–35
 51. Brandt JD, Beiser JA, Kass MA, et al. Central corneal thickness in the ocular hypertension treatment study. *Ophthalmology*. 2001; 108:1779–1788
 52. Kass MA, Becker B. Genetics of primary open-angle glaucoma. *Sight Sav Rev*. 1978; 48:21–28.
 53. Armaly MF. Inheritance of dexamethasone hypertension and glaucoma. *Arch Ophthalmol*. 1967; 77:747–751.
 54. Nguyen TD, Chen P, Huang WD, Chen H, Johnson D, Polansky JR. Gene structure and proteins of TIGR, an olfactomedin-related glycoprotein cloned from glycocorticoid-induced trabecular meshwork cells. *J Biol Chem*. 1998; 273:6341–6350.
 55. Faucher M, Anctil JL, Rodrigue MA, et al. Founder TIGR/myocilin mutations for glaucoma in the Quebec population. *Hum Mol Genet*. 2002; 11: 2077–2090.
 56. Vincent AL, Billingsley G, Buys Y, et al. Digenic inheritance of early-onset glaucoma: CYP1B1, a potential modifier gene. *Am J Hum Genet*. 2002; 70(2):448–460.
 57. Aung T, Rezaie T, Okada K, et al. Clinical features and course of patients with glaucoma with the E50K mutation in the optineurin gene. *Invest Ophthalmol Vis Sci*. 2005; 46:2816–2822.

-
58. Wirtz MK, Samples JR, Kramer PL. Mapping a gene for adult-onset primary open-angle glaucoma to chromosome 3q. *Am J Hum Genet.* 1997; 60:296–304.
 59. Romunde H.M., Thepass G, Lemij H.G. Is hyperopia an important risk factor for PACG in the Dutch population? - A case control study. *Journal of ophthalmology.* 2013:25-30
 60. Curran EJ. A new operation for glaucoma involving a new principle in the aetiology and treatment of chronic primary glaucoma. *Arch Ophthalmol* 1920; 49:131-55.
 61. Banziger TH. The mechanism of acute glaucoma and the explanation for the effectiveness of iridectomy for the same. *Ber Dtsch Ophthalmol Ges* 1922; 43:43-48.
 62. Chandler PA. Narrow-angle glaucoma. *Arch Ophthalmol* 1952; 47:695-716.
 63. Panek WC, Christensen RE, Lee DA, et al. Biometric variables in patients with occludable anterior chamber angles. *Am J Ophthalmol* 1990;110:185-188
 64. Van Herick W, Shaffer RN, Schwartz A. Estimation of width of angle of anterior chamber: incidence and significance of the narrow angle. *Am J Ophthalmol* 1969; 68:626-629.
 65. Shaffer RN. Symposium: Primary glaucomas. III. Gonioscopy, ophthalmoscopy, and perimetry. *Trans Am Acad Ophthalmol Otol* 1960; 62:112-116
 66. Sonty S, Schwartz B. Vascular accidents in acute angle closure glaucoma. *Ophthalmology* 1981; 88:225-228.

-
67. Hoskins HD Jr, Kass MA. Becker-Shaffer's diagnosis and therapy of the glaucomas, 6th ed. St. Louis: CV Mosby, 1989:208-237
 68. Wollensak J, Zeisberg B. Pathophysiology, treatment, and prophylaxis of angle closure glaucoma. *Glaucoma* 1986; 8:3-11.
 69. Simmons RJ, Belcher CD, Dallow RL. Primary angle closure glaucoma. In: Tasman W, Jaeger EA, eds. *Clinical ophthalmology*, vol 3. Philadelphia: JB Lippincott, 1985; 53:1- 32.
 70. Stelmack T. Angle closure glaucoma. In: Lewis TL, Fingeret M, eds. *Primary care of the glaucomas*. Norwalk: Appleton & Lange, 1993; 347-362.
 71. Lee J.R.,Choi J.Y.,Kim Y.D.,Cho J. Laser Peripheral Iridotomy with Iridoplasty in Primary Angle Closure Suspect: Anterior Chamber Analysis by Pentacam *Korean J Ophthalmol.* 2011 Aug; 25(4): 252–256.
 72. Esmaeili A, Barazandeh B, Ahmadi S, Haghgi A, Hosseini S.M., Abolbashari F. Assesment of anterior chamber parameters after laser peripheral iridotomy in primary angle close suspect using pentacam and gonioscopy. *Int J ophthalmol.* 2013;6(5):680-684
 73. Cumba R.J., Nagi K.S.,Bell N.P.,Blieden L.S.,Chuang A.Z., Mankiewicz K.A. et al.Clinical outcomes of peripheral iridotomy in patients with the spectrum of chronic primary angle closure.*ISRN Ophthalmology* 2013:15-23.
 74. He M, Friedman D.S., Ge J, Huang W, Jin C, Lee P.S., et al Laser peripheral iridotomy in primary angle-closure suspects:Biometric and gonioscopic outcomes:The Liwan eye study. *Ophthalmology* 2007;114(3):494-500
 75. Kumar R.K., Baskaran M, Ronnie G,Vijaya L. Follow-up of Primary Angle Closure Suspects After Laser Peripheral Iridotomy Using Ultrasound Biomicroscopy and A-Scan Biometry for a Period of 2 Years. *Journal of*

-
- Glaucoma 2009;18(7):521-527
76. Thomas R, George R, Parikh R, et al. Five year risk of progression of primary angle closure suspects to primary angle closure: a population based study. *Br J Ophthalmol.* 2003;87:450–454.
77. Ye T, Yu Q, Peng S. Six year follow-up of suspects of primary angle-closure glaucoma. *Chin J Ophthalmol* 1998;34:167-169.
78. Wilensky JT, Kaufman PL, Frohlichstein D, et al. Follow up of angle closure suspects. *Am J Ophthalmol.* 1993;115:338–34.
79. Peng PH, Nguyen H, Lin HS, Nguyen N, Lin S. Long-term outcomes of laser iridotomy in Vietnamese patients with primary angle closure. *British Journal of Ophthalmology.* 2011;95(9):1207–1211
80. Krupin T. Stone R.A, Cohen B.H Kolker AE, Kass, M.A. Acute intraocular pressure response to argon laser iridotomy. *Ophthalmology.* 1985;92:922–926
81. López-Caballero C, Puerto-Hernández B, Muñoz-Negrete FJ, Rebolleda G, Contreras I, Cabarga C, Corral A. Quantitative evaluation of anterior chamber changes after iridotomy using Pentacam anterior segment analyzer. *Eur J Ophthalmol.* 2010;20(2):327–332
82. Li S, Wang H, Mu D, Fu J, Wang X, Wang J, Wang N. Prospective evaluation of changes in anterior segment morphology after laser iridotomy in Chinese eyes by rotating Scheimpflug camera imaging. *Clin Exp Ophthalmol.* 2010;38(1):10–14.
83. Antoniazzi E, Pezzotta S, Delfino A, Bianchi PE. Anterior chamber measurements taken with Pentacam: an objective tool in laser iridotomy. *Eur J Ophthalmol.* 2010;20(3):517–522.
-

ANNEXURES

ANNEXURE – I

PATIENT PROFORMA

NAME :

Age & sex :

HOSPITAL NO.

date:

Chief complaints:

HOPI:

Other significant history:

Anterior segment:

Posterior segment:

OCULAR EXAMINATION:

OD : OS:

Post LPI

Parameter studied	Before LPI	1Week	1 month	6 months
Uncorrected V/A				
Best corrected V/A				
Anterior Chamber Depth				
Intra ocular pressure				
Anterior Chamber angle				
Axial Length				
Lens Thickness				
Iris Profile				
Visual Fields				
Corneal Curvature				
Fundal Changes				
PACS to PACG				

Diagnosis:

Treatment:

Done by:

ANNEXURE II

INFORMED CONSENT

“EFFECTIVENESS OF LASER PERIPHERAL IRIDOTOMY IN PRIMARY ANGLE CLOSURE SUSPECTS VISITING TERTIARY CARE HOSPITAL”

This is a laser surgery used for people with narrow angle. The laser is used to make a hole in the iris (the coloured part of eye). The laser burn should let more fluid leak out through the drain in the eye. Furthermore, it will hopefully prevent scar formation between the iris and cornea, which can lead to progression of the glaucoma.

There are some individuals who respond well to this and others do not respond to the surgery at all. The type of narrow angle and the basic make up of the eye determines your response.

The laser machine looks similar to the examination microscope that the doctor use to look at your eyes during each visit. The laser itself makes a little noise and flashes about as bright as the flash of the camera. Almost everybody has the procedure comfortably and without pain. Some individuals feel a little pressure during the laser. The procedure usually takes about ten to twenty minutes.

You may need drops before and after the laser. This is because pressure in eye can go up after the laser treatment. This is the greatest risk of this procedure. If it does occur, you may require medication to lower the pressure, which will be administered in office. Rarely pressure goes very high and does not come down with medication. In

such a case you will require surgery to control the pressure.

Most people notice some blurring in vision after the laser. This clears within a few hours in most individuals.

You will need drops to use after the procedure for the eye to heal correctly. You will probably use the new drop for about a week.

Other risks from this procedure include inflammation in the eye, cataract formation, bleeding (usually a small amount but can be a large amount), double vision, scar formation between iris and lens of the eye(synechia) that prevents pupil from moving correctly, late closure of iridotomy that requires repeated laser surgery and rarely damaged to cornea.

Subject's name and signature /thumb impression

Date:

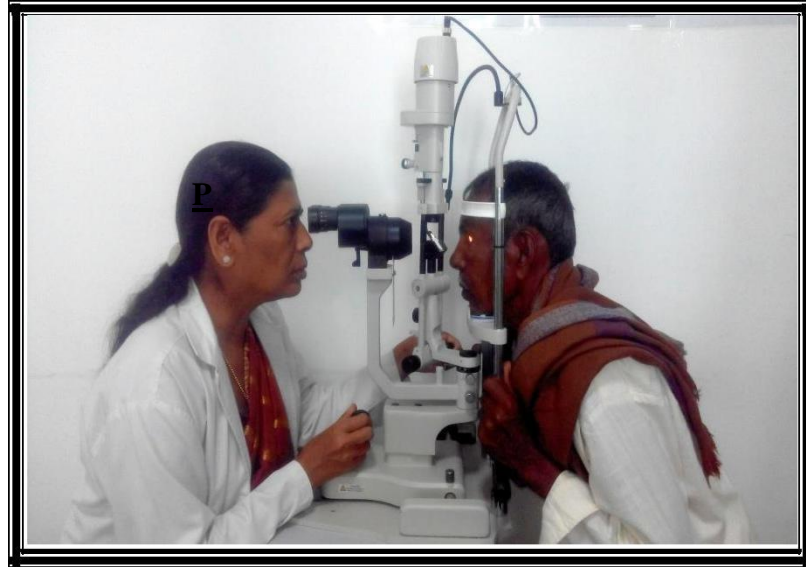Name and signature of witness

Date:

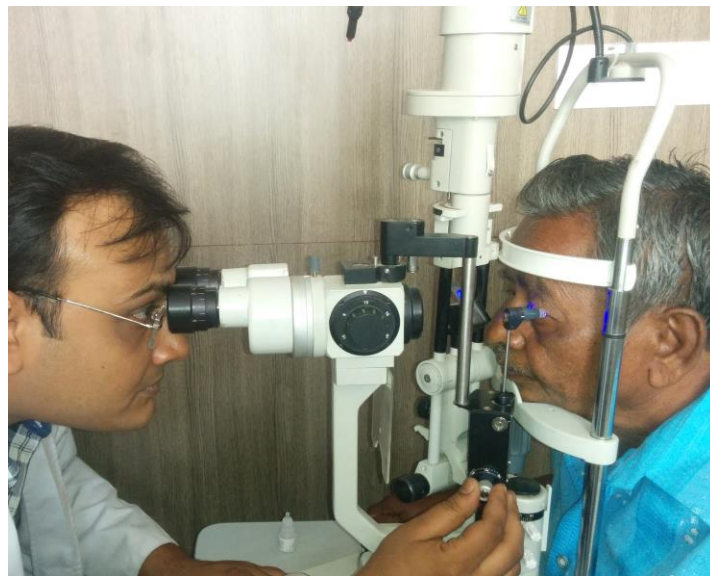Name and signature of person obtaining consent

Date:

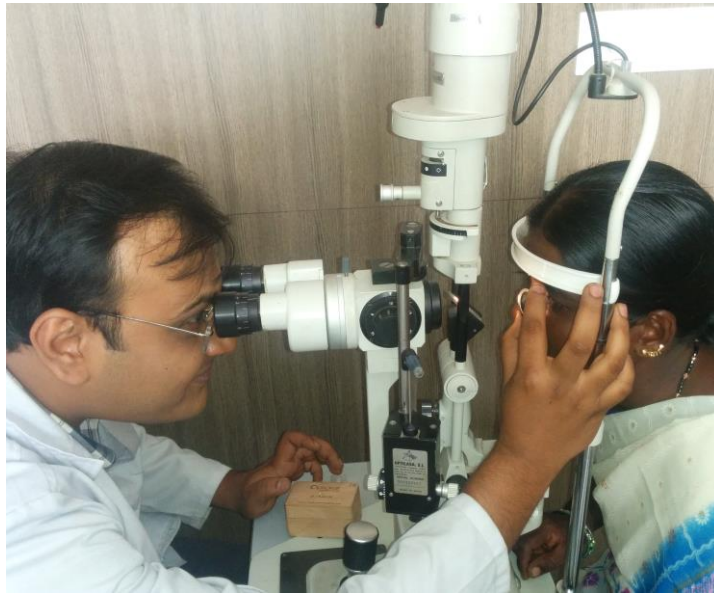ANNEXURE III -PHOTOGRAPHS



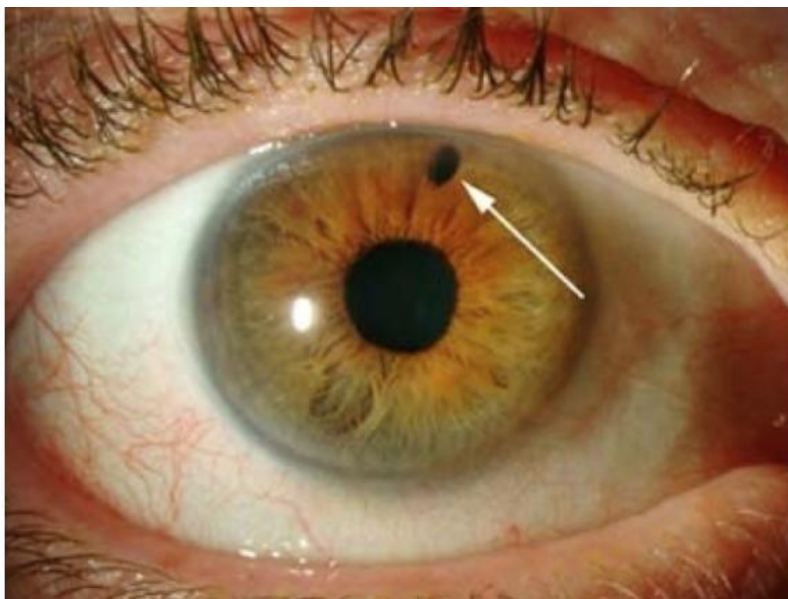
PHOTOGRAPH 1: SLIT LAMP EXAMINATION



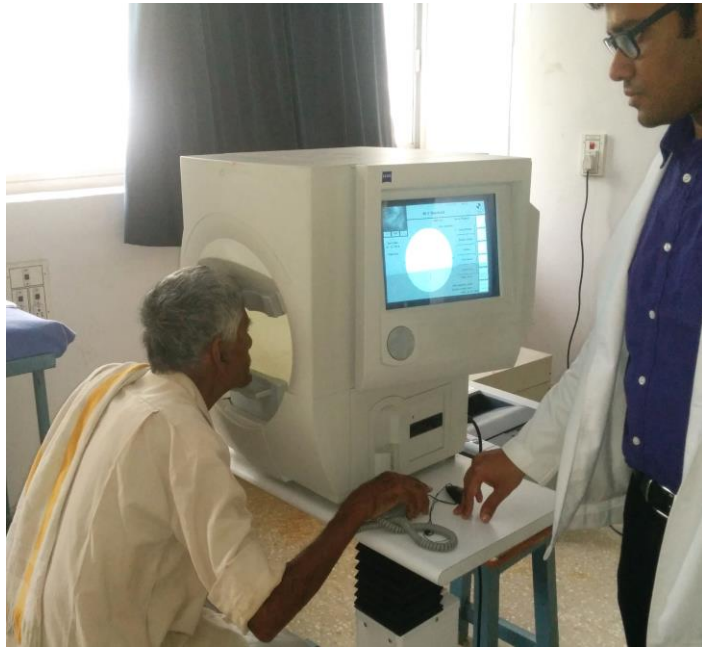**PHOTOGRAPH 2: IOP MEASUREMENT BY GOLDMANN'S
APPLANATION TONOMETER.**



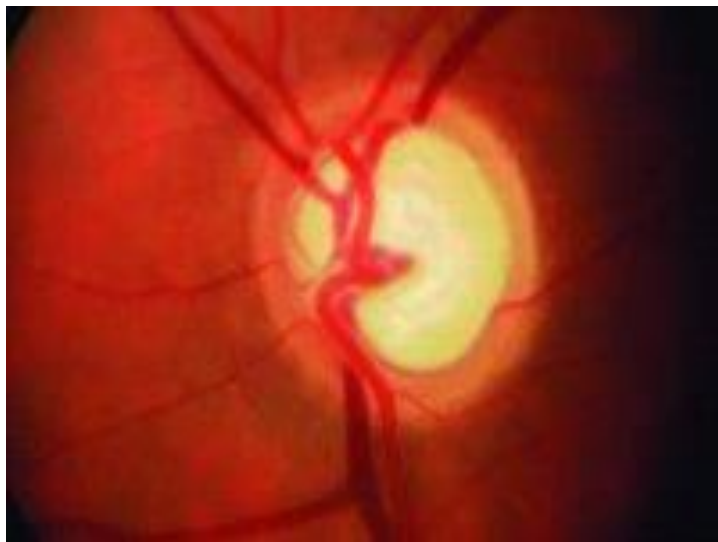PHOTOGRAPH 3: GOINOSCOPY BY 3 MIRROR GONIO LENS.



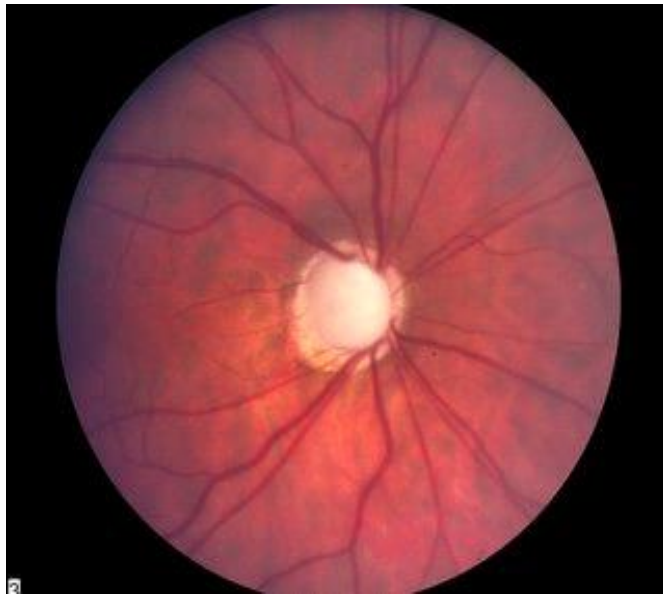PHOTOGRAPH 4: PATENT IRIDOTOMY SITE AFTER LPI




PHOTOGRAPH 5: VISUAL FIELDS TESTING BY HUMPHREYS FIELD ANALYZER.



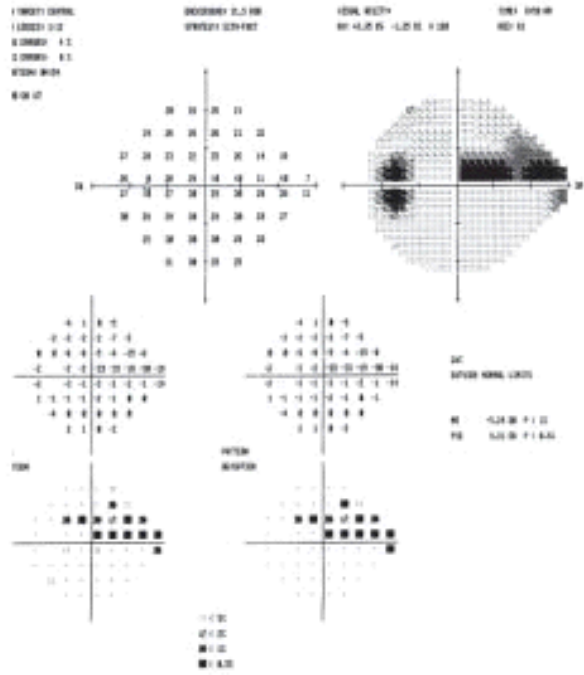
PHOTOGRAPH 6: GLAUCOMATOUS DISC CUPPING



PHOTOGRAPH 7: NEURO-RETINAL RIM THINNING WITH NERVE FIBRE LAYER DEFECT



PHOTOGRAPH 8: NORMAL VISUAL FIELD



PHOTOGRAPH 9: GLAUCOMATOUS VISUAL FIELD DEFECT

ANNEXURE III - KEY TO MASTER CHART

- Sl. No. >> Serial Number.
- PACS >> Primary angle closure suspect.
- PAC >> Primary angle closure.
- PACG >> Primary angle closure glaucoma.
- UCVA >> Uncorrected Visual acuity (distant vision).
- BCVA >> Best corrected Visual acuity (distant vision).
- WNL >> Within normal limits.
- OD >> Oculus Dexter (Right eye).
- OS >> Oculus sinister (Left eye).

