

Accidental Decapitation; a Case Report

Umesh-Babu R¹, Kiran J^{1*}

¹ Department of Forensic Medicine and Toxicology, Sri Devraj Urs Medical College, Kolar, Karnataka, India

ARTICLE INFO

Article Type:
Case Report

Article History:
Received: 9 June 2014
Revised: 1 Sep 2014
Accepted: 5 Sep 2014

Keywords:
Decapitation
Accident
Death

ABSTRACT

Background: Decapitation of bodies is a rare event in industrial accidents and accounts for about 0.1% of forensic autopsies. Decapitation has been reported in cases of suicidal, homicidal, and accidental deaths, and there are several examples of autopsy findings that are indicative of each mode of death.

Case Report: We report a case of an accidental decapitation of a worker in an automated wood laminating industry. Based on the circumstances at the site, the police presupposed foul play. The scene investigation revealed that the worker had attempted to adjust the alignment of hot pressed wood manually which suddenly started to move and the worker was struck between the laminating machine and the moving board at the level of his neck which caused decapitation of his neck.

Conclusion: Examination revealed that the neck was severed at the level of the second and third cervical vertebrae. This case was unusual as the mechanism for the decapitation was a blunt force.

Copyright©2015 Forensic Medicine and Toxicology Department. All rights reserved.

► *Implication for health policy/practice/research/medical education:* Accidental Decapitation

► *Please cite this paper as:* Umesh-Babu R, Kiran J. *Accidental Decapitation; a Case Report. International Journal of Medical Toxicology and Forensic Medicine.* 2015; 5(1): 36-8.

1. Introduction:

Decapitation of bodies is a rare event in industrial accidents and accounts for about 0.1% of forensic autopsies (1). Decapitation has been reported in cases of suicidal, homicidal, and accidental deaths, and there are several examples of autopsy findings that are indicative of each mode of death (2-5). Industrial accidents are a frequent occurrence in many countries. It is estimated that unsafe work conditions is

one of the leading causes of death and disability among India's working population. These deaths are needless and preventable. Unlike growth rates and GDP figures that are flaunted every quarter, the figures of dying and ailing workers who make this growth possible are never recorded or spoken about. The only way to get an idea of the scale of the problem is from data released by the International Library Organization (ILO), which estimates that around 403,000 people in India die every year due to work-related problems (6). There are no reliable figures for occupational diseases either. The ILO arrives at these figures by extrapolating them from developed countries like

Corresponding author: Kiran J, MD, Department of Forensic Medicine and Toxicology, Sri Devraj Urs Medical College, Kolar, Karnataka, India
E-mail: drkiranj@yahoo.com

Denmark where every accident and disease is reported. However, there is no sufficient official statistical data about industrial fatalities in India. In this article, we reported a decapitation case resulting from an industrial accident, and the decapitation mechanism is discussed in light of the published data. Reconstruction of the sequence of events by comparing wound morphology and the tool possibly involved in the infliction of injury, including consideration of biomechanical and technical aspects, is one of the classical tasks of the medico-legal expert (7). He also needs to know the criminalistic findings to determine whether the incident in question occurred through the action of another person or by accident. Not infrequently, autopsy reveals surprising findings, as demonstrated by this case of lethal injury caused by automated moving wooden board.

2. Case report:

A 35-year-old male worker of a wood lamination industry died while trying to adjust the struck lamination board which was subjected to a press machine. The victim did not follow the safety precaution prescribed for operating an automated lamination procedure. He tried to adjust it manually and the wooden board struck the victim in a great velocity when the victim's head and neck were level with the moving board and was decapitated. At the scene, the blood stains were adherent to the press machine with torn pieces of the victim's shirt and a slice of his neck structures were still lying on the press machine (Fig. 1a). The investigation

revealed that the victim's head and upper trunk was in contact with the hot press machine and was charred. The decapitated body of the victim was on the ground. There was a pool of blood on the ground. The total height of the victim was 162 cm, the length of the victim's head was 21 cm, and the distance between the ground and the running wooden board was 140 cm. In the external examination, the head was separated from the body between the second and third cervical vertebrae (fig. 1b). On internal examination, all internal organs were pale owing to massive external bleeding. There was blood in the trachea and oesophagus. The toxicological analysis was negative. Histopathology of the vital organs was also negative for any natural diseases that would have contributed for the accident.

3. Discussion:

Decapitation has been used for execution throughout the world, and is still used for enactment of the death penalty in some countries. Complete and sole decapitation without any further mutilation of the victim connected with violent homicides is, relatively rare. Antemortem decapitation must be considered highly indicative of a homicide (4). Suicide by decapitation is unusual. Most suicides involving decapitation involve the deceased placing his or her head on a train or tramline, resulting in severing of the head by a moving engine (7). Rarely, a victim may construct a device such as a guillotine to specifically achieve suicidal decapitation rather than relying on train trauma (3). Less-common suicidal

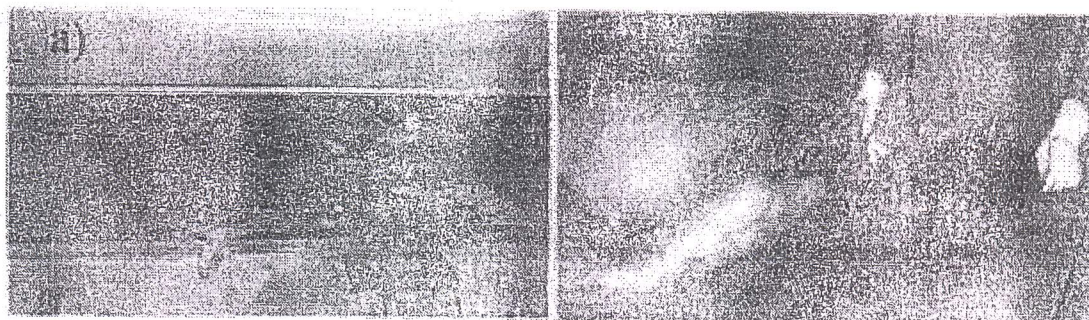


Fig. 1. a) The victim's scene.; b) Separated head from the body

decapitations result from hanging or ligatures attached between the neck of the driver of a car and a stationary object⁸. Distinguishing suicide from an unintentional death can be difficult in these circumstances; however, decapitation by a train has been found to be indicative of suicide, whereas multiple injuries from blunt trauma caused by a moving train are more often an accident (5). Accidental decapitations can also result from traffic accidents, or occupational accidents. Decapitation may be associated with failure to use seat belts, fast driving speeds, and road barriers. Unrestrained children may also be at risk for decapitation from airbags. Decapitation by industrial trauma can occur at any age, and is often associated with heavy machinery in workshops or farm equipment. The wooden board has caused the death in the present case which is of two inches thick and unlikely to cause decapitation unless it is moving with a great velocity. The decorative wood lamination system uses a heat application to bond either pre-coated or plain papers and incorporates a heated press to create the ultimate hot press

system. Contact with this has produced charring of the head and upper part of the trunk.

References

1. Demerci S, Dogan KH, Erkol Z, Gunaydin G. Accidental Decapitation, a case report, *Am J Forensic Med Pathol*. 2009;30(3):270-2.
2. Rothschild M, Schneider V. Decapitation as a result of hanging. *For Sci Int*. 1999;106:55-62.
3. Sharrock K. Suicidal decapitation by guillotine. *Am J For Med Pathol*. 2002;23(1):54-6.
4. Turk E, Puschel K, Tsokos M. Features characteristic of homicide in cases of complete decapitation. *Am J For Med Pathol*. 2004;25(1):83-6.
5. Cina SJ, Koeplin JL, Nicholas C. A decade of train pedestrian fatalities, the Charleston experience. *J For Sci*. 1994;39(3):668-73.
6. <http://infochangeindia.org/status> of occupational safety and health in India.
7. Betz P, Eisenmenger W. Unusual suicides with electric saws. *For Sci Int*. 1995;75(2-3):74-9.
8. Byard W, Gilbert JD. Characteristic features of death due to decapitation. *Am J For Med Pathol*. 2004;25(2):129-30.