

## A CASE OF LEPTOSPIROSIS WITH ERYTHEMA NODOSUM AND REACTIVE ARTHRITIS DURING THE FIRST TRIMESTER OF PREGNANCY

SHIJU K SLEEBA\*, RAVEESHA A, SRINIVASA S.V

Department of Internal Medicine, Sri Devraj Urs Medical College, Kolar, Karnataka. Email : sleebea\_shiju@yahoo.co.in

Received: 16 April 2013, Revised and Accepted: 22 April 2013

### ABSTRACT

Leptospirosis is a zoonosis and occurs in endemic as well as epidemic forms in many parts of India. Manifestations may range from asymptomatic infection to fulminant fatal disease with myositis, conjunctivitis, hepatic, renal, cardiac and neurological involvement and hemorrhagic manifestations. A 30 years old lady in her first trimester of gestation presented with fever, multiple painful erythematous swellings over the front of both legs and swelling associated with pain of left ankle joint for 1 week. On evaluation she had erythema nodosum over the anterior aspect of both lower extremities and reactive arthritis of left ankle joint. Leptospira serology for Immunoglobulin M was positive. She was started on intravenous ceftriaxone 1 gm twice daily. After 7 days of treatment, erythema nodosum and reactive arthritis subsided. Erythema nodosum and reactive arthritis which are rare manifestations of leptospirosis have occurred together in a patient during the first trimester of pregnancy makes this case worth presenting.

**Keywords:** Leptospirosis, Erythema Nodosum, Reactive Arthritis, First Trimester of Pregnancy, Kolar, Karnataka, India

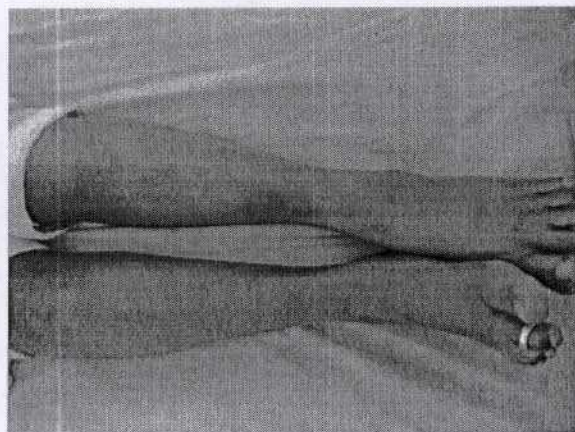
### INTRODUCTION

Leptospirosis, caused by leptospira is an aerobic, coiled, highly motile, Gram-negative spirochete with internal flagella. Leptospirosis occurs in endemic and epidemic forms in many parts of India. Outbreaks have been reported from Maharashtra, Delhi, Tamil Nadu, Orissa, Gujarat and Karnataka.<sup>[1]</sup> Leptospira exist in some animal species like rats without producing any disease; such animals may shed leptospira in urine for prolonged periods.<sup>[2]</sup> After they are shed from the host, the organisms survive in moist warm soil for several weeks. They enter a new host through abrasions in the skin or through intact mucous membrane. Clinical manifestations occur due to direct tissue invasion, cytokine-mediated capillary and cellular damage and immunological mechanisms later in the disease.<sup>[2]</sup> Upto 40 percent of individuals exposed to contaminated water develop asymptomatic subclinical infection.<sup>[2]</sup>

### CASE PRESENTATION

A 30 years old lady in her first trimester of pregnancy presented with fever and multiple painful swellings over both her legs for 1 week. She also had pain with associated swelling of left ankle joint. There was a gradual progressive increase in swelling of the left ankle joint. She then developed severe calf muscle pain and headache. She was residing in an area where rainfall is common and gives history of contact with contaminated surroundings where rats are common. Occasionally she walks without footwear in and around her house.

Physical examination revealed fever of 100 degree fahrenheit; multiple tender erythematous nodules were present over the anterior aspect of both lower extremities (Fig 1). On examination of left ankle joint, there was local rise of temperature, tenderness and restriction of the following movements - plantar flexion, dorsiflexion, inversion and eversion. Laboratory findings included - Total leukocyte count - 10,800 cells/mm<sup>3</sup>, Haemoglobin - 10.7gm/dl, RBC- 3.77 million/mm<sup>3</sup>, Platelet count - 369 x 10<sup>9</sup>/liter, Serum creatinine- 0.97mg/dl, Blood urea- 11mg/dl, SGOT-13 IU, SGPT-12 IU, ANA - Negative, Mantoux test -Negative, Dengue IgM negative, Malaria rapid card test was negative, C- reactive protein - 96 mg/dl, RA factor - negative,



**Figure 1: Erythema Nodosum over anterior aspect of both legs with swelling of left ankle joint**

Venous Doppler of both lower limbs showed no evidence of deep venous thrombosis. In Urine routine test there was no albumin or white blood cells or casts. Obstetric scan showed a single intra uterine gestation with good cardiac activity. Leptospira serology for Immunoglobulin M using ELISA method was positive. Blood culture and sensitivity demonstrated no growth of pathogenic organism. Modified faine's criteria for leptospirosis - SCORE (A+B+C) was 32 which lead to the diagnosis of Current leptospirosis.<sup>[3]</sup> Treatment was started with intravenous ceftriaxone 1 gm twice daily. Physiotherapy including wax bath and warm water exercises were performed on left ankle joint. After 7 days of treatment erythema nodosum and reactive arthritis subsided. The pain and restriction of movements at the left ankle joint resolved. She was able to walk freely with minimum restriction of movements and was discharged after the 9<sup>th</sup> day of admission.

## DISCUSSION

Clinical manifestations like erythema nodosum and reactive arthritis occurring together in an adult with leptospirosis are rare manifestations of the disease.<sup>[4,5]</sup> Reactive arthritis and antiphospholipid syndrome are rare immune mediated manifestations of leptospirosis. Antibodies generated in response to leptospiral infection may cross react with host antigens and could lead to an inflammatory response. They are likely to be the result of immunologic cross reactivity.<sup>[4]</sup> In a review of 15 patients with documented leptospirosis late in pregnancy, Shaked et al found that eight women had abortions, two delivered healthy babies, four delivered babies who had signs of active leptospirosis and in one case the clinical outcome was not stated.<sup>[4]</sup> Chedraui and San Miguel reported a case of leptospirosis in a 28 week pregnant patient.<sup>[4]</sup> Goehenour et al described in leptospiral infections that pretibial fever which is a relatively mild form of infection can occur with a rash like erythema nodosum.<sup>[6]</sup> In the present case, the lady in her first trimester of pregnancy with leptospirosis had rare manifestations of the disease like erythema nodosum and reactive arthritis.

Conclusion: A 30 years old lady in her first trimester of gestation erythema nodosum over the anterior aspect of both legs and reactive arthritis of left ankle joint. Erythema nodosum and reactive arthritis which are rare manifestations of leptospirosis have occurred together in this patient during the first trimester of pregnancy makes this case worth presenting.

## REFERENCES

1. Karnad DR. Leptospirosis. In: Shah SN, Anand MP, editors. API Textbook of Medicine. 8th Ed, Mumbai: The Association of Physicians of India; 2009, 83-85.
2. Bal AM. Unusual clinical manifestations of leptospirosis. J Postgrad Med. 2005; 51:179-83.
3. Shivakumar S, Shareek PS. Diagnosis of Leptospirosis utilizing modified Faine's criteria. J Assoc Physician India 2004; 52:678-9.
4. Pappas G, Akritidis N, Christou L, Mastora M, Tsianos E. Unusual causes of reactive arthritis: Leptospira and Coxiella burnetii. Clin Rheumatol. 2003 Oct; 22(4-5):343-6.
5. J M Buckler. Leptospirosis presenting with erythema nodosum. Arch Dis Child. 1977 May; 52(5): 418-419.
6. Goehenour W.S., Smadel J.E, Jackson E.B, Evans L.B, and Yager R.H. Leptospirosis etiology of Fort Bragg fever. Public Health Reports (Washington).1952; 67:811-813.