

RECURRENT BILATERAL BELL'S PALSY- A RARE CASE REPORT AND REVIEW OF LITERATURE A CASE REPORT

Kumar.S*, V. Lakshmaiah M.N. Chandrashekar

Sri Devaraj Urs Medical College & Research Centre, Tamaka, Kolar-563101, Karnataka, India

*Corresponding Author: kumarsrinivasan67@gmail.com

This article is available online at www.ss-journals.com

ABSTRACT

Bell's palsy is a benign lower motor neuron facial nerve disorder. Recurrent unilateral Bell's palsy is found in about 7% of the facial palsy cases. Alternating bilateral recurrent Bell's palsy is relatively uncommon. A review of recent medical literature revealed very few case reports of bilateral recurrent Bell's palsy, with none found in Asian neurology medical literature. We report a case of recurrent alternating bilateral Bell's palsy (3 episodes) in a male patient aged 34 years, was treated conservatively and recovered completely. He is symptom free on follow up till date. We present this case because of its rarity.

Keywords: Alternating recurrent Bell's palsy, Lower motor neuron Palsy

1. Introduction:

Bell's palsy is regarded as a benign common neurological disorder. It has an acute onset and is almost always a mononeuritis.¹ Recurrent unilateral Bell's palsy is found in about 7% of cases of facial palsy.² Bilateral recurrent Bell's palsy is rare and its prevalence is 10-15% as reported in older medical literature.² Recent data has shown complete resolution of symptoms within the first two months of onset in about 70-80% of cases leaving another 20-30% of patients with varying degrees of residual facial nerve dysfunction.^{1,3} Autosomal dominant or recessive inheritance, Diabetes and Hypertension are some of the factors which may predispose to multiple or recurrent attacks of Bell's palsy.^{4,5}

We report such a case of bilateral alternating recurrent Bell's palsy in a male patient who recovered completely without any residual facial nerve dysfunction. Our patient did not have any predisposing factors either.

2. Case Report:

A patient aged 36 years, hailing from Kolar, a police constable by profession presented with symptoms of deviation of the angle of the mouth to the left, inability to close the left eye completely with drooling of the saliva from the left angle of the mouth since one day (FIG-2). There was no history suggestive of any chronic illness in the past like Hypertension or Diabetes.

Fig 1a: HRCT of the Temporal bone showing normal mastoids



Fig- 1b:- HRCT of the Temporal bone showing normal mastoids.

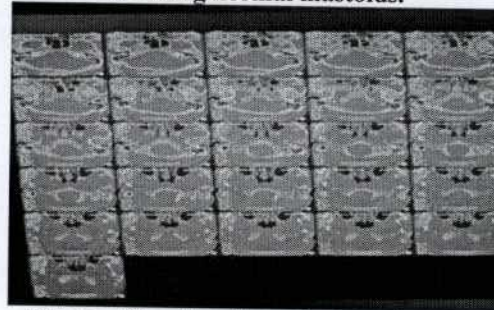
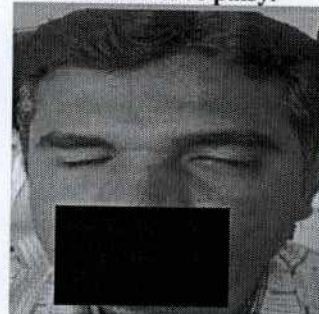


Fig- 2 :- Showing the patient having Left Facial Nerve palsy.



The patient was hospitalised previously for similar complaints for three times. Earlier in the month of September in 2001, patient had sought a Physician's opinion for the same complaints as mentioned above. There was complete recovery by ten days, after he had received a course of steroids and Antiviral drugs with Physiotherapy. Again in the year 2006, during the month of September, he had developed similar problem for the second time. But, at that time patient had experienced deviation of the angle of the mouth to the right, incomplete closure of the right eye and he was managed for a Right Facial Nerve Palsy.

During the third episode of similar complaints he presented to us. On examination he had a neuro deficit of lower motor neuron facial nerve palsy of grade V House - Brackman. All other clinical parameters were within normal limits. The patient had no family history of similar complaint.

With a diagnosis of bilateral recurrent facial nerve palsy the patient was admitted in our hospital. Routine baseline investigations were all within normal limits. MRI Brain was found to be normal. The opinion of the Otolaryngologist was also sought, who advised a HRCT of the Temporal bone that revealed normal petrous temporal bone, normal middle ear cavity and normal Mastoids (FIG-1). The Ophthalmologist performed the Schirmer's test (> 20mm in 2 minutes), which was found to be normal.

The patient was placed on a short course of steroids and antiviral drugs. The patient showed improvement by about 80% after eight days of hospitalisation with the above management along with facial muscle physiotherapy. He was discharged with the advice of tapering the dose of steroids and to continue regular physiotherapy. At follow up after a week following discharge the patient had complete recovery.

The patient is on regular follow up at our outpatient department and he has no residual neuro deficits of the facial nerve till date.

3. Discussion:

Facial palsy is a very common neurological condition. Majority of cases are labelled as Bell's palsy. Most of these reported cases in clinical practice involve a single episode.^{1,4}

However recurrent ipsilateral or alternating contralateral facial nerve palsy is seen in approximately 10-15% of patients.⁶ Recurrent Facial palsy is associated with a strong family history.^{7,8} In our case, there was no family history.

According to Pitt's *et al.*, patients having a third recurrence of bell's palsy is 3% and that with a fourth recurrence is 1.5%, in his retrospective study of 140 patients.⁹ In our patient he had a third recurrence within an interval of about ten years. There are several published reports regarding recurrence with each pregnancy among the women.¹⁰

Hypertension and diabetes are the other predisposing factors for recurrent attacks. Our patient did not have either of it.

A narrowed facial canal diameter may also be a predisposing factor in a similar family.¹¹ In our patient there was no family history and HRCT of the temporal bone showed no abnormalities.

Bell's palsy is classified into five categories as per the study conducted by Yanagihara *et al.*¹² They are as follows-

- a) Unilateral nonrecurrent.
- b) Unilateral recurrent.
- c) Simultaneous bilateral.
- d) Alternating bilateral.
- e) Recurrent bilateral.

Our patient can be grouped under 'Category e' (recurrent bilateral). Recurrent bilateral bell's palsy carries a good prognosis, with no residual facial nerve deficit with timely treatment. This patient experienced three such episodes of alternating bilateral facial palsy and recovered within a short duration of 10 days, during each such episode.

Bell's palsy has a controversial history from its etiology and natural history to its management. Bell's palsy is no longer considered idiopathic and is believed to result from a viral insult.¹³ Our patient received a full course of Antiviral drugs along with steroids with complete recovery which could explain the possibility of the palsy was due to virus.

A coincidental finding from reported cases of recurrent Bell's palsy suggest that the

patient's left facial nerve involvement was more prone for recurrence.¹⁴ Although there are literatures reporting an approximately equal frequency of involvement on either side of the face.¹⁶

Conclusion:

Alternating recurrent Bells palsy has a good prognosis with complete recovery when the patients are treated adequately in time and complemented with physiotherapy.

References

1. Ngow H.A, Wan Khairina W.M.N, Hamidon B.B: Recurrent Bell's palsy in a young woman; *Singapore Medical Jour.* 2008;49(10):e278.
2. N. Stahl, T. Ferit: Recurrent bilateral facial palsy; *The Jour.of Laryngology & Otology* 1989, 103:117-119.
3. Katusic S.K, Beard C.M, Weiderholt W.C, Bergstrath, Kurland L.T; Incidence, clinical findings & prognosis in Bell's palsy; *Annals of Neurology* 1986;20 :622-627.
4. Cawthorne .T, Haynes .D.R: Facial palsy; *Br Med Jour.* 1956;2:1197-2000.
5. Hageman G, Loppel P.F, Jansen E.N.H, Roseboom A.R: Familial alternating Bell's palsy with dominant inheritance; *Eur. Neurol.* 1990;30:310-313.
6. B.Scola Yurrita, C. Ramirez Calvo, E.Scola Peigo; Idiopathic Recurrent facial palsy; *Acta Otorrinlaringol Esp* 2004;55; 343-345.
7. Broddie H.G: Recurrent Bell's palsy; *J.Laryngol. Otol* 1973; 86; 1117-1120.
8. Hallmo P, Iverland H.H, Mair IVVS: Recurrent facial palsy; *Arch. Otorhinolaryngol* 1983; 237; 97-102.
9. Pitts D.B, Adour K.K, Hilsinger R.L :Recurrent Bell's palsy, analysis of 140 patients; *Laryngoscope* 1988; 98: 535-540.
10. Walling A.D: Bell's palsy in pregnancy and the puerperium., *J.Family Pract.* 1993;36:559-563.
11. English J.B, Stammel E.W, Bernat J.L: Recurrent Bell's palsy; *Neurology* 1996;47; 604-605.
12. Noaki Yanagihara, HIRAMA Mori, Tesuo Kozawa: *Archives of Otolaryngology*, Vol.110 No.6, June 1984; 374-377.
13. Murakami S, Mizibuchi. M, Nakashiro Y et al.; Bell's palsy and Herpes Simplex virus, identification of viral DNA in endoneurial fluid & muscle; *ANN. Int. Med.* 1996,124;27-30.
14. Burgess R.C, Michaels L, Bale J.F Jr., Smith R.J; PCR amplification of herpes simplex viral DNA from the geniculate ganglion of a patient with Bell's palsy. *Annals of Otol. Rhinol. Laryngol* 1994; 775-779.
15. House J.W, Brackmann D.E; Facial nerve grading system. *Otolaryngol. Head Neck Surg* 1985; 93; 146-147.
16. Wg.Cdr.H Swami, Wg. Cdr. A Dutta, S.Nambiar; Recurrent Bell's palsy; *MJAFI* 2010; 66;95-96.

