

PUB: 07/2012



Case Report

Twin reversed arterial perfusion (TRAP) Sequence: (Acardius Amorphous) a case report and review of literature

Shashidhar B^a, B N kishore kumar^b, R. Sheela^c, R. Kalyani^d, N. Anithae, Prem Sai Reddy^e

^aAssistant Professor, OBG, Sri Dev Raj Urs Medical College, Kolar, Karnataka

^bProf and HOD, Radiology, Sri Dev Raj Urs Medical College, Kolar, Karnataka

^cProf and unit chief, OBG, Sri Dev Raj Urs Medical College, Kolar, Karnataka

^dProfessor, Pathology, Sri Dev Raj Urs Medical College, Kolar, Karnataka

^ePost graduate, Radiology, Sri Dev Raj Urs Medical College, Kolar, Karnataka

ARTICLE INFO

Keywords:

Twin reversed arterial perfusion
Acardius Amorphous
para biotic twin

ABSTRACT

Acardiac twinning is a rare congenital anomaly of monozygotic twin pregnancy characterized by formation of a malformed fetus with an absent or rudimentary (but nonfunctional) heart. Acardiac twinning, often results from abnormal placental vascular anastomoses. This leads to twin reversal arterial perfusion with complex pathophysiology. We report a case of acardiac-acephalus twins and briefly review the literature.

© Copyright 2010 BioMedSciDirect Publications IJBM - ISSN: 0976:6685. All rights reserved.

1. Introduction

Multiple pregnancy accounts for 1.5% of all pregnancies, complicated by congenital malformations twice as often as with singletons. TRAP sequence is known as acardius or chorioangiopagus parasiticus, it is a rare complication of monochorionic twins. TRAP sequence is an extremely rare anomaly with an overall incidence of 1 per 35,000 births, amounting to an average risk of 1% among monozygotic twins[1]. The risk of recurrence was estimated 1:10,000 [2, 3]. TRAP sequence is characterized by a structurally normal pump twin perfusing an anomalous recipient twin via an artery-to-artery anastomosis in a reverse direction [4]. The anomalous foetus is either acardiac or has severely anomalous cardiac structure[5].

2. Case Report

We here by present a case of 28 year old third gravidae with no living babies referred to labour room with a history of delivering first baby and transverse lie of second twin with hand prolapse. Fetal heart rate was not localized for the second twin. She underwent an emergency caesarean section with extraction of anomalous second twin. The intact placenta was monochorionic diamniotic in type and weighed 500 grams. The pump twin baby girl weighed 2.3 kgs. The baby was observed in the neonatal intensive care unit for 2 days and shifted to mothers side. On care ful

examination the amorphous baby with abnormal cephalic pole and acephaly. A tuft of hair was seen at the cephalic pole with abnormally placed upper limbs, right upper and lower limb were mal developed. Insertion of umbilical cord was seen below the left upperlimb bud. Left lowerlimb was partially developed. Amorphous twin was evaluated by infantogram. CT, and MRI scans. Careful autopsy was negative for any of the intra abdominal or thoracic organs and absence of cardiac structures.

3. Discussion

TRAP sequence is a rare complication of monochorionic multiple pregnancy. It is classified according to the degree of cephalic and truncal maldevelopment. The first type is acardiac-acephalus, where no cephalic structures present. The second is acardius-anceps where some cranial structure and or neural tissue present. The third is acardius-acornus with cephalic structure but no truncal structures present. The fourth type is acardius-amorphous with no distinguishable cephalic or truncal structure[6]. The first cases of acardia were reported by Benedetti in 1533 and Benedictus in 1539, and later by Geoffroy in 1836.

Several theories had been postulated to explain TRAP sequence. The most accepted theory is that artery-to-artery anastomosis between the monochorionic twins in the first trimester is the fundamental event in development TRAP sequence[7]. This abnormal circulation may result in early tissue hypoxia with resultant disruption of development of the cardiovascular system and a cascade of disruption of organ development in the recipient twin. Because the blood first perfuse the lower segment of the anomalous twin, the lower limbs and scrotum receive comparatively more oxygen than the upper

* Corresponding Author: Dr. Shashidhar B
Assistant Professor, OBG,
Sri Devraj Urs Medical College
Kolar, Karnataka, India. 563101.
E-Mail: Shashi180808@gmail.com

segment of the body[8,9]. The anomaly is fatal for the recipient twin. The pump twin may develop heart failure because of an increased cardiac demand. Numerous obstetric complications are associated with TRAP syndrome such as hydrops fetalis, polyhydramnios, umbilical cord accidents, preterm delivery or fetal death of the pump twin. The prominent features of the recipient twin are: total or partial absence of cranial vault, holoprosencephaly, absent facial structures, anophthalmia, microphthalmia, cleft lip, cleft palate, absent or rudimentary limbs, diaphragmatic defects, absent lungs and heart, esophageal atresia, ventral wall defects, ascites, absent liver and gallbladder, edema of the skin and single umbilical artery[10,11.]

Many authors have reported pregnancy outcomes which seem to be influenced by the weight of the acardiac fetus compared to that of the pump fetus Twin Weight Ratio (acardiac/pump, TWR). When TWR exceeds 50%, the prognosis of the normal fetus is worse. On the other hand, if the weight of the acardiac fetus is less than 25% compared to the pump fetus, the prognosis is better [12]. Moore et al. reported that cardiac failure occurred in 53% of cases. The risk of cardiac failure is also related to the TWR: 25% of pump fetuses with a TWR greater than 50% will develop cardiac failure, whereas this risk is nearly zero if the TWR is less than 50%.[12].

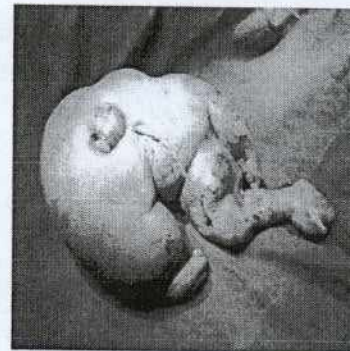Ishimatsu et al suggested acardiac twin should be suspected in all monochorionic, malformed fetuses with cystic hygroma, generalized edema, and an absent cardiac pulsation with a nonfunctioning heart. Similarly, an ultrasonography finding of twins revealing discordant or grotesque malformation along with reverse flow in the umbilical artery is usually diagnostic of an acardiac twin[13]. Sherer and colleagues reported the use of the Doppler velocimetry of the umbilical cord in the TRAP syndrome, showing a markedly abnormal peak systolic-to-end diastolic velocity ratio[14].

Risk for cardiac insufficiency in the pump twin increases proportionally to the relative increase in weight of recipient-to-pump twin. Risk for congestive heart failure increases to 94% as the acardiac twin achieves a size more than half the size of the pump twin. At this juncture, some form of minimally invasive intervention is warranted to occlude vascular supply to the acardiac twin through cord occlusion techniques or intrafetal ablation. Cord occlusion has been attempted by embolization, cord ligation, laser coagulation, bipolar diathermy, and monopolar diathermy, while intrafetal ablation has been performed with alcohol, monopolar diathermy, interstitial laser, and radiofrequency.[14] With radiofrequency ablation, greater than 90% survival can be achieved in monochorionic diamniotic pregnancies complicated by TRAP sequence. An exact preoperative evaluation of the vascular flow including Doppler sonography is, however, mandatory.

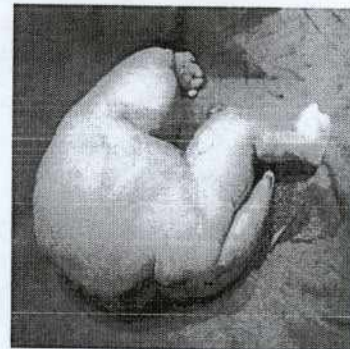Tan and Sepulveda recommended that intra-fetal ablation is the treatment of choice for TRAP sequence because it is simpler and more effective in prolonging pregnancy than cord occlusion[14]. On the other hand, Hecher et al found that fetoscopic laser coagulation of placental anastomosis or the

umbilical cord of the acardiac twin was successful in 82% by laser alone and in a further 15% by laser coagulation in combination with bipolar forceps. The success rate is better in the early second trimester and less successful in the third trimester because the umbilical cord is more edematous with higher content of Wharton's jelly[15].

Fig"1. Anterior view of amorphous twin showing partially

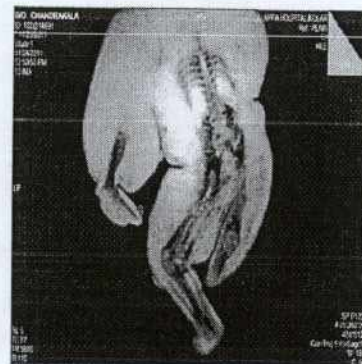


Fig"2. Posterior view

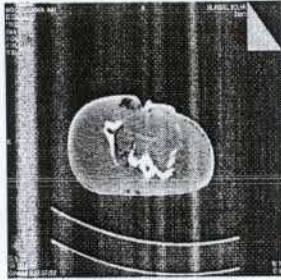


Developed upper and lower limb, with umbilical cord attachment, left upper limb bud can be seen. tuft of hair can be seen at the cranial end

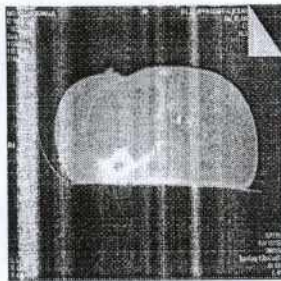
Fig 3. MRI : show absent head, cervical spine, No identifiable organs in thorax, abdomen and pelvis.



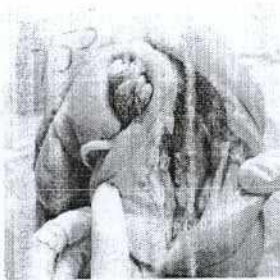Fig"4. CT of thorax : Thick soft tissues, Absent scapula on left side No identifiable cardiac chambers.



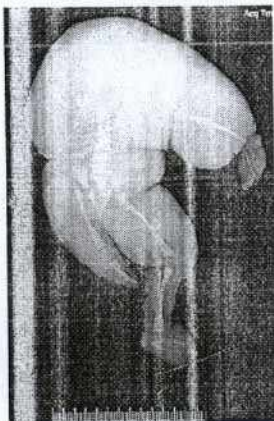Fig"5.: CT Thorax: No identifiable organs in thorax



Fig"6.:Autopsy,absence of intra abdominal or intrathoracic organs



Fig"7: Infantogram ; Shows absence of bony cranium, cervical spine. Thoracic and lumbar spine poorly developed. Bony pelvis malformed . Left upper limb is absent. Right upper limb poorly developed with rudimentary hand. Right lower limb show deformed foot with Oligodactyl. Left lower limb show Amputation at below knee (Phocomelia)



4.Conclusion

Twin-Reversed Arterial Perfusion (TRAP) sequence is a rare complication of monochorionic multiple gestation. Accurate antenatal diagnosis is essential to improve the prognosis of this rare entity. Though many patients can benefit from conservative treatment, minimally invasive treatment modalities for the vascular anastomosis improve the outcome of the pump twin.

4.References

- [1] Sogaard K, Skibsted L, Brocks V. Acardiac twins: pathophysiology, diagnosis, outcome and treatment. Six cases and review of the literature. *Fetal Diagn Therapy*. 1999;14:53-59.
- [2] Nevils BG, Maciulla JE, Izquierdo LA, et al. Twin, Acardiac, Anceps. *The Fetus* 1993; 3: 15-7.
- [3] Leite JMB, Couto JCF. Twin, Acardiac at 24 Weeks. <http://www.thefetus.net> Accessed on 01.01.2010.
- [4] Van Allen MI, Smith DW, Shepard TH. Twin-Reversed Arterial Perfusion (TRAP) Sequence: A Study of 14 Twin Pregnancies with Acardius. *Semin Perinatol* 1983; 7: 285-93
- [5] Sepulveda W, Sfeir D, Reyes M, et al. Severe Polyhydramnios in Twin Reversed Arterial Perfusion Sequence: Successful Management with Intrafetal Alcohol Ablation of Acardiac Twin and Amino Drainage. *Ultrasound Obstet Gynecol* 2000; 16: 260-3.
- [6] Mohanty C, Mishra OP, Singh CP, et al. Acardiac Anomaly Spectrum. *Tetralogy* 2000; 62: 356-9.
- [7] Gembruch U, Viski S, Bagamery K, et al. Twin Reversed Arterial Perfusion Sequence in Twin- to-Twin Transfusion Syndrome after the Death of the Donor Co-Twin in the Second Trimester. *Ultrasound Obstet Gynecol* 2001; 17: 153-6.
- [8] Luiz N. TRAP Syndrome. *Indian Pediatr* 2003; 40: 683-4.
- [9] Weiss B, Peltz R, Chayen B, et al. Tailored Management of Twin Reversed Arterial Perfusion (TRAP) Sequence. *Ultrasound Obstet Gynecol* 2004; 23: 451-5.
- [10] Gibson JY, D'Cruz CA, Patel RB, et al. Acardiac Anomaly: Review of the Subject with Case Report and Emphasis on Practical Sonography. *J Clin Ultrasound* 1986; 14: 541-5.
- [11] Izquierdo L, Smith J, Gilson G, et al. Twin, Acardiac, Acephalus. *Fetus* 1991; 1: 1-3.
- [12] Moore TR, Gale S, Benirschke K: Perinatal outcome of forty-nine pregnancies complicated by acardiac twinning. *Am J Obstet Gynecol* 1990;163:907-912.
- [13] Ishimatsu J, Nakanami H, Hamada T, Yakushiji M. Color and pulsed Doppler ultrasonography of reversed umbilical blood flow in an acardiac twin. *Asia Oceania J Obstet Gynaecol*. 1993;19:271-275.
- [14] Tan TYT, Sepulveda W. Acardiac twin: A systematic review of minimally invasive treatment modalities *Ultrasound Obstet Gynecol*. 2003;22:409-419
- [15] Hecher k, Hackelot BJ, Ville Y. Umbilical Cord Coagulation by Microendoscopy at 16 Week's Gestation in An Acardiac Twin. *Ultrasound Obstet Gynecol* 1997; 10: 130-2.

