

PUB: 9/5/2013

International Journal of Biomedical And Advance Research

ISSN: 2229-3809 (Online)

Journal DOI: [10.7439/ijbar](https://doi.org/10.7439/ijbar)

CODEN: IJBABN

Case Report**Management of a neglected femoral neck fracture – A case report and review of literature**Nagakumar J. S¹, Pagadpally Girish^{2*} and B. S. Nazeer³¹MS Ortho, Associate Professor, Department of Orthopedics, Sri Devaraj Urs Medical College, Kolar, Karnataka, India²(MS Ortho), Post Graduate, Department of Orthopaedics, Sri Devaraj Urs Medical College, Kolar, Karnataka, India³MS Ortho, Professor, Department of Orthopedics, Sri Devaraj Urs Medical College, Kolar, Karnataka, India***Correspondence Info:**

Dr. Pagadpally Girish

(MS Ortho),

Post Graduate,

Department of Orthopaedics,

Sri Devaraj Urs Medical College, Kolar, Karnataka, India

Email: girishpagadpalli@yahoo.in**Abstract**

Femoral neck fractures are less frequent in children. A neglected femoral neck fracture is one where there has been a delay of more than 30 days to seek medical attention from the time of injury¹. It is one of the most challenging problems encountered by orthopaedic surgeons especially in young adults and children. Avascular necrosis (AVN) is a severe complication following a neglected fracture neck of femur in children with a reported incidence of <15 %. We report a case of a young girl presenting with neglected displaced fracture neck of femur that was successfully managed by initial immobilisation with skeletal traction followed by a closed reduction and internal fixation using dynamic hip screws. No clinical or radiological signs of avascular necrosis were observed in the 1 year of follow-up. Remarkable post-operative improvement in the symptoms and decrease in the limp was noted. Patient had no hip pain or discomfort. Accurate anatomical reduction and internal fixation are crucial to reduce the incidence of avascular necrosis after femoral neck fracture. Internal fixation with dynamic hip screws is a reliable method with decent long-term functional outcomes even in children.

Keywords: (AVN) Avascular necrosis, Femoral neck, Neglected fracture**1. Introduction**

Neglected femoral neck fractures are challenging to treat in young adults (age <60). While there is no defined lag period for such a fracture to be called "neglected," Myers et al¹ introduced the term to indicate a delay of 30 days or more from the injury to seek medical help. Attempts to preserve the femoral head in a young active patient are of at most importance. We report a case of a 13 year old girl with neglected displaced fracture neck of femur successfully managed by closed reduction and internal fixation using dynamic hip screws. Multiple methods have been used with varying success for the management of neglected femoral neck fractures. The guidelines for management are still evolving. Surgeons should acclimatise to methods to recognise, manage, and prevent complications for improved results.

2. Case Report

A 13 year old girl presented to the emergency department of our hospital with inability to walk and pain in her right

hip following a history of fall from a height of around 10 feet before 2 years ago. Patient received first aid in a govt. primary health centre and was further treated in a private nursing home for about 3 months following trauma. On ambulation after 3 months of complete bed rest, patient developed a painful limping gait. She did not receive any treatment for the same till 4 more months after which she was treated conservatively by a quack for pain and deformity by local massages. However, the symptoms did not improve. Patient had pain and limp for another 6 months for which she was inspected in a rural health camp conducted by our hospital and was referred here for further management of fracture neck of right femur. Patient was immobilised on proximal tibial skeletal traction for a week and following that on distal femoral traction for 10 days. Patient was taken up for the surgery on 11th day and closed reduction and internal fixation (CRIF) was done using dynamic hip screws (DHS). Patient was ambulated on 6th post-operative day. There were no post-operative complications. Significant decrease in the pain and limp was noted. Patient was discharged on post op day 10 and regular monthly follow ups were done as an outpatient basis. Patient recovered well. No clinical or radiological signs of avascular necrosis were observed in the 1 year of follow-up. Remarkable post-operative improvement in the symptoms and decrease in the limp was noted. Patient had no hip pain or discomfort.

After 15 months of fracture fixation patient's pain subsided and radiograph at 18 months showed full union. The patient at this moment was asymptomatic, had good range of motion around hip and knee and had no shortening.

Fig.1. AP x-rays of hip joint at the time of presentation

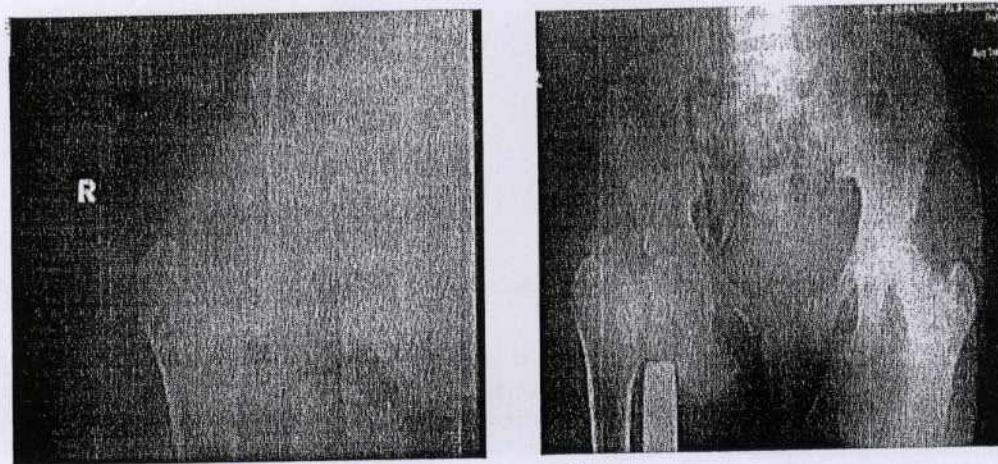


Fig. 2. Pre-operative x ray

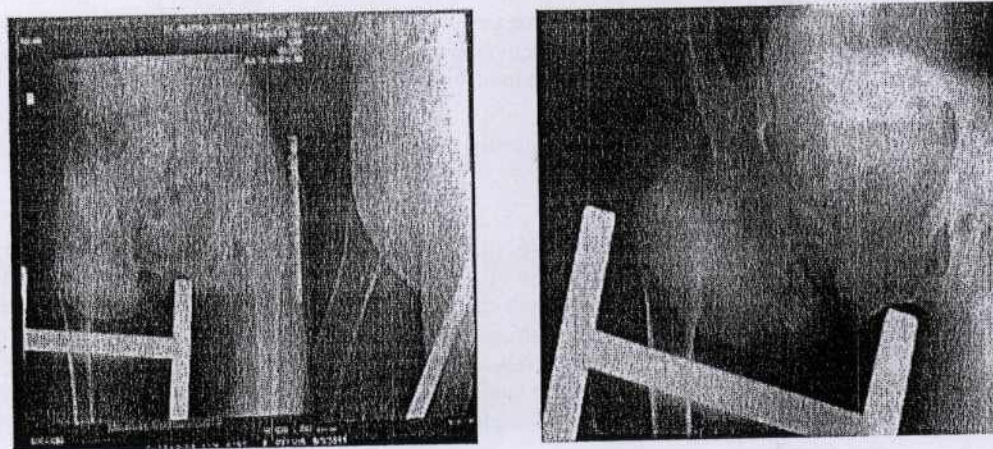


Fig. 3. Post operative x ray AP view showing internal fixation and reduction with DHS.

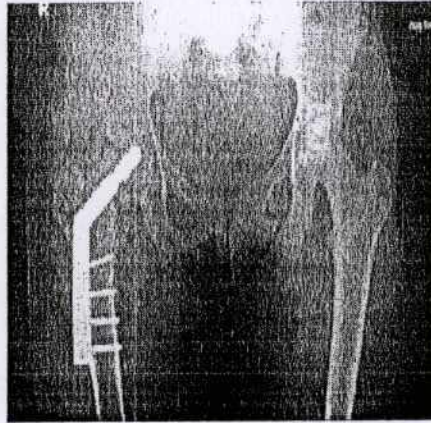

Fig. 4. X ray after 6 months of follow up

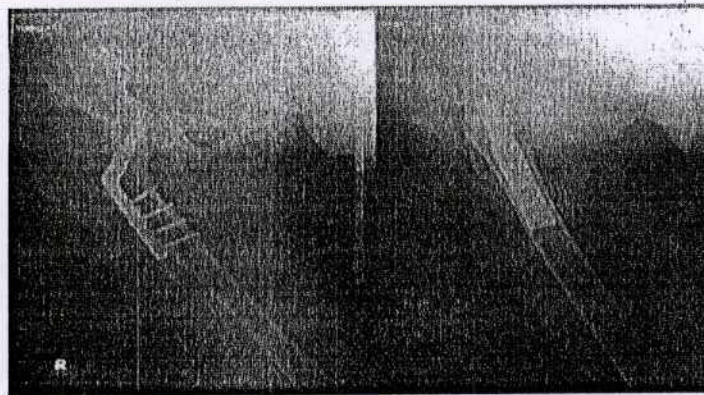
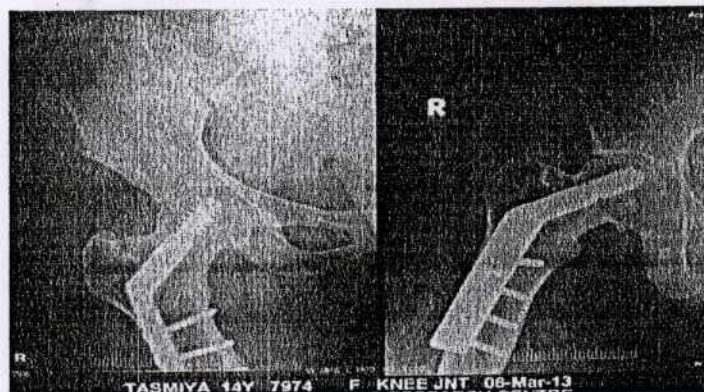


Fig. 5. X ray after 12 months of follow up



3. Discussion

Femoral neck fracture is a rare entity in children occurring mainly with high velocity trauma. The management guidelines still continue to be evolving. In the early 20th century, these were managed primarily with closed reduction and immobilization in POP hip spica in abduction and internal rotation. High incidence of non-union, pressure sores and respiratory complications led to the exploration of new methods of internal fixation and introduction of the Smith Peterson

nail. Developing concepts of fixation under compression led to the use of cancellous partially threaded screws and placement over preliminary wires led to the introduction of cannulated variety of screws. These are preferred in the adults. Smooth pins (Moore or Knowles pins) are the choice of treatment for children².

The presentation and the complications at different age groups vary extensively. While fixation failures are common in elderly with osteoporotic bones, marked displacement of fragments, posterior comminution and disruption of blood supply result in a higher incidence of avascular necrosis (AVN) in young adults and children. Fracture type, displacement, age, and treatment are all statistically significant independent predictors of AVN. Older children are 1.14 times more likely to develop AVN for each year of increasing age. Types I to III fractures are 15, 6, and 4 times, respectively, more likely to develop AVN than type IV fractures³. In children, the growth plate needs to be secured by using implants which would minimize damage without compromising on the stability of reduction and internal fixation.

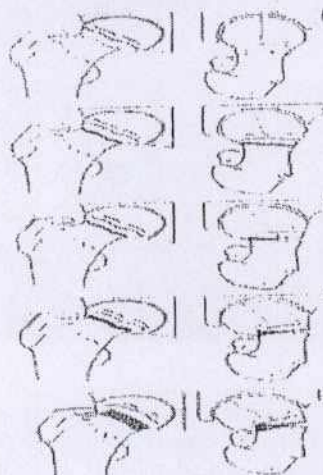
The blood supply to the femoral head is from three main arteries, i.e., medial femoral circumflex, lateral femoral circumflex and obturator through the intracapsular terminal branches running parallel to the neck. Any femoral neck fracture disrupts the terminal blood vessels producing AVN. The fracture is intra-articular and is exposed to a very high degree of shearing strain. These fractures are associated with the complications of fracture displacement or re-displacement after reduction and fixation, non-union and avascular necrosis⁴. Studies have suggested that the greater the degree of initial fracture displacement the greater the risk is for these fracture healing complications to occur^{5,6}. Accurate reduction and internal fixation are obligatory requirements to anticipate fracture healing.

Although no difference in the AVN rates has been reported in patients operated by closed or open reduction, the treatment results may often vary. The outcome is further complicated if superimposed with a delay in presentation by few weeks or months, after receiving manipulative treatments from "Quacks" in the form of massages. Presentation may be with a poorly reduced and ineffectively stabilized fracture as is in our case. The patient presented to us after a delay of two years with a neglected displaced fracture neck of femur that was ineffectively treated by local quacks. Although, primary radiological examination did not reveal features of any AVN, amplified fracture gap due to femoral neck resorption and displacement of proximal fracture fragment was noted.

Delayed and neglected presentations have diverse outcomes. The guidelines for assessment and management such fractures are still to be established. The emphasis is always on femoral head preservation especially in children. In the elderly, however, options comprise arthroplasty, cemented to uncemented fixation, and Bipolar to total joint replacement.

The management of femoral neck fractures in children is challenging especially that of a neglected fracture. The key factors in treating femoral neck fractures seem to be early diagnosis, early surgery, anatomic reduction, capsular decompression and stable internal fixation². In the present case, attempts were made to achieve a stable internal fixation using dynamic hip screws for early functional outcome and to primarily reduce the complications of a neglected displaced femoral neck fractures.

Figure 1: Degrees of displacement of intracapsular fractures showing the increasing angulation that occurs on the lateral radiograph³



Femoral neck fractures can present as undisplaced to fully displaced, with a progressive increase in incidence of complications with increasing displacement. Consideration of fracture displacement should be based on both antero-posterior and lateral radiographs⁷. In our case, analysis of the displacement of the fracture was made pre operatively by both AP and lateral rays. Serial x rays both AP and lateral views were taken for post-operative follow up at regular visits.

The goals of treatment vary in elderly and young adults. In the elderly patient, the treatment focuses on mobility with weight bearing as tolerated and minimizing complications of prolonged bed-rest. In symptomatic patients preferred treatment is endoprosthesis replacement. The standard treatment for displaced fracture of neck of femur in young adults is internal fixation, aimed at salvaging the femoral head, preventing osteonecrosis and non-union. Arthroplasty procedures are not ideal given the younger age and high functional levels. Anatomic reduction and stable internal fixation are of utmost importance for a good outcome. Fixation methods differ. In children and young adults, femoral head salvage is almost always indicated⁸. Replacement of cancellous screws with a larger screw may be considered in the absence of misalignment, shortening, loss of reduction and avascular necrosis⁹. We used dynamic hip screws to achieve reduction as the femoral neck was partially resorbed and the fracture gap was wide.

The role of proper reduction along with operating experience with the implant has been well established. DHS implant in case of proper reduction of the fracture this implant allows immediate full weight bearing without any risk of early dislocation. In addition to the great primary stability, the major advantage of the dynamic hip screw (DHS) is the easy to place single leading wire which has to be situated correctly in each plane as opposed to the three leading wires when using cannulated screws. The latter can only very rarely be placed in parallel direction in every plane. Those screws often converge or diverge and consequently lose mechanical grip and rotation stability. Moreover simple screws lack the locking plate feature with the plate including a sliding sleeve fixed to the diaphysis of the bone, preventing varus displacement of the fracture¹⁰. Intramedullary implants jeopardise the femoral head perfusion and pose a risk for reperfusion because of greater volume at the proximal end. Also, they do not provide mechanical pliability for intracapsular fractures¹⁰. Cannulated screws are now universally used for the fixation of femoral neck fractures. They provide better fixation than pins which are known to have a significantly lower rate of nonunion and infection than the sliding screw-plate.¹¹

4. Conclusion

The incidence of neglected fracture neck of femur is declining with improving healthcare facilities in developing countries especially in India. High-energy trauma, road traffic accidents and falls from heights are the most common causes accounting for this type of injury in young adults and children. The treatment strategy aims at achieving accurate anatomical reduction with stable internal fixation to reduce the incidence of fracture healing complications like avascular necrosis and nonunion. In children femoral head salvage should be considered. Dynamic hip screw is reliable method with noble long-term functional outcomes. Efforts should be made to achieve better results. Internal fixation of the fracture in combination with the use of osteo-inductive materials may be a new lead to further enhancement of the results. With apt treatment, timely return to function can be accomplished.

References

1. Meyers MH, Harvey JP, Moore TM. Treatment of displaced subcapital and transcervical fractures of the femoral neck by muscle-pedicle-bone graft and internal fixation. A preliminary report on one hundred and fifty cases. *J Bone Joint Surg Am* 1973;55:257-274.
2. Sandhu HS, Dhillon MS, Jain AK. Femoral neck fractures. *Indian J Orthop* 2008 Jan-Mar; 42(1): 1-2.
3. Moon ES, Mehlman CT. Risk factors for avascular necrosis after femoral neck fractures in children: 25 Cincinnati cases and meta-analysis of 360 cases. *J Orthop Trauma* 2006; 20(5) : 323-9.
4. Linton P. On the different types of intracapsular fractures of femoral neck: a surgical investigation of origin, treatment, prognosis and complications in 365 cases, *Acta Chir Scand* 1944;90:1-122.
5. Alho A, Benterud J G, Ronningen H, Hoiseth A. Prediction of disturbed healing in femoral neck fracture: radiographic analysis of 149 cases, *Acta Orthop Scand* 1992;63: 639-644.
6. Garden RS. Stability and union in subcapital fractures of the femur. *J Bone and Joint Surgery* 1964;46:630-647.
7. Lawrence CR, Parker MJ. Complication Rates Relating to the Degree of Displacement of Femoral Neck Fractures: a

- Clinical Study of 878 Internally Fixed Intracapsular Fractures. *J of Orthop Trauma* 2011;(1):6.
8. Butt MF, Dhar SA, Gani NU, Farooq M, Mir MR, Halwai MA, Kangu KA, Mir BA, Kawoosa A. Delayed fixation of displaced femoral neck fractures in younger adults. *Injury* 2008; 39:238-243.
 9. Jackson M, Learmonth I D: The treatment of non union after intracapsular fracture of the proximal femur. *Clinical orthopedics and related research* 2002;399:119-128.
 10. Lein T, Bula P, Jeffries J, Engler K, Bonnaire F. Fractures of femoral neck. *Acta Chirurgiae Orthopaedicae et traumatologiaecechosl* 2011; 78:10-19.
 11. Christie J, Howie CR, Armour PC. Fixation of displaced subcapital femoral fractures. Compression screw fixation versus double divergent pins. *J Bone Joint Surg Br* 1998; 70: 199-201.