

Total hip arthroplasty in idiopathic chondrolysis of the hip: A case report

Anvesh Kondlapudi, Anil Kumar. S. V, Manohar. P. V and Samarth Arya *

Department of Orthopaedics, R.L. Jalappa Hospital and Research Centre, Tamaka, Kolar, India

***Correspondence Info:**

Dr. Samarth Arya,
Jr. Resident,
Department of Orthopaedics,
R.L. Jalappa Hospital and Research Centre, Tamaka, Kolar, India
E-mail: samarth.arya@gmail.com

Abstract

Chondrolysis of the hip is defined as an extensive loss of articular cartilage of the femoral head and acetabulum. A 14-year-old girl presented to our institute with pain of insidious onset in the right hip, associated with a limp since 18 months. On examination, all movements of the right hip were restricted and painful. Radiograph of the affected hip showed deformed femoral head with definite joint space narrowing and regional osteoporosis. Patient was diagnosed to have Idiopathic Chondrolysis of Hip and uncemented total hip replacement was done. We conclude that this case report enriches the existing data regarding the treatment options for idiopathic chondrolysis of hip in a young patient

Keywords: chondrolysis, osteoporosis, spondyloepiphyseal dysplasia

1.Introduction

Chondrolysis of the hip is defined as an extensive loss of articular cartilage of the femoral head and acetabulum. Chondrolysis of the hip associated with slipped upper femoral epiphyses is well recognised[1]-[6] and its association with trauma and prolonged immobilization has been described.[4][7] Idiopathic chondrolysis of the hip was described by Jones in 1971[8] and sporadic reports have since been made.[9]-[13] Total hip arthroplasty in young adults is done in conditions like osteonecrosis, secondary osteoarthritis, JRA, idiopathic chondrolysis, osteogenesis imperfecta/protrusio (1%), and spondyloepiphyseal dysplasia.[14]

2. Case report

The patient was a 14-year-old who was admitted in our institute on 20 July 2013. She was a healthy girl with no significant previous illnesses and gave history of trivial fall 18 months back. Her presenting symptoms were pain of insidious onset in the right hip, associated with a limp since 18 months and she was not able to squat. On examination she

appeared well. All movements of the right hip were restricted and painful. She had a fixed flexion deformity of 20° with further flexion of 40°. There was no external rotation, and internal rotation was limited to 30°. She also had a fixed abduction deformity of 20° and further free abduction upto 45°.

Laboratory investigations showed hemoglobin of 12 gm/dl and the leucocyte differential count was normal; serum platelet concentration was normal. There was a slightly raised erythrocyte sedimentation rate (ESR) which was reported as 34 mm/1st h. Rheumatoid factor, antistreptolysin O (ASO) antibody titres, sickle cell test, and thalassaemia screen were normal. A skin Mantoux test was normal.

Radiograph of the affected hip showed deformed femoral head with definite joint space narrowing (Fig. 1) and possibly some slight cortical haziness. There was regional osteoporosis. Tomographic studies confirmed the joint space narrowing and there was no definite bone destruction.

Patient was initially posted for open synovial biopsy to rule out infectious pathology

which eventually came as negative for infection. After that she was posted for uncemented total hip replacement (Fig. 2) 6 days later. Intra operatively there was no synovial hypertrophy, fibrous ankylosis with extensive cartilage destruction was noted. Post operatively skin traction was applied for 2 weeks following which she was ambulated.

Passive mobilization exercises were started from post day 1 and active exercises were started from post op day 7. Patient was followed up at 1, 2, 6 months post operatively and harris hip score was recorded at each follow up and They were found to be as follows: 81(good), 89 (good) and 94 (excellent).

Figure 1: Radiograph of the affected hip

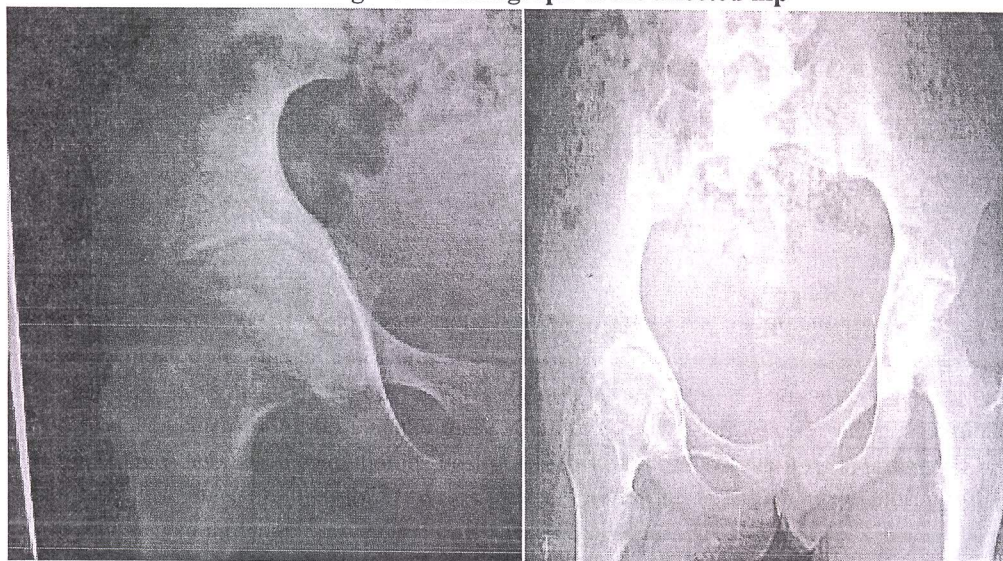
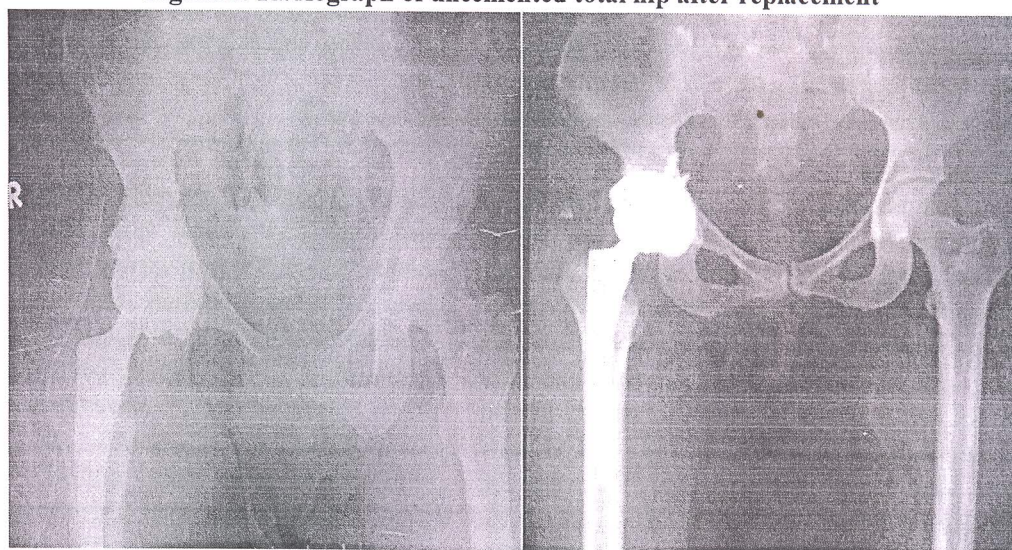


Figure 2: Radiograph of uncemented total hip after replacement



3. Discussion

Chondrolysis of the hip is defined as an extensive loss of articular cartilage of the femoral head and acetabulum. Patients affected by idiopathic chondrolysis of the hip most frequently consult because of pain in the hip and / or the knee[14] during initial stages and limp with loss of hip movements in later stages of the disease. Until today no specific diagnostic criteria exist. In daily clinical practice the diagnosis is made by exclusion of other, more common causes of acute or chronic monoarticular hip pain.

All biochemical and microbiological tests have to stay within normal limits. This includes

inflammatory parameters, bacterial serology, rheumatic antibodies (antinuclear antibodies, rheumatoid factor), cultures of joint fluid aspiration, synovial biopsy.

Monarticular hip arthritis in adolescence presents a challenge to the diagnostician. Clinical evaluation, radiological appearances and joint tissue biopsy are the cornerstone of a firm diagnosis. Various differential diagnoses includes: trauma, slipped upper femoral epiphysis, septic arthritis, tuberculosis, Perthes disease, pigmented villonodular synovitis, synovioma and other neoplasm, monarticular rheumatoid arthritis.

Despite the fact that the outcomes for patients with idiopathic chondrolysis of the hip vary, the disease process appears to have two distinct stages in most patients. The acute stage commences with the onset of the condition and typically lasts for 6 to 16 months. The patient presents with an insidious onset of pain and decreased motion of the hip caused by an inflammatory response. Radiographically, there is concentric narrowing of the articular space, caused by loss of articular cartilage in the femoral head and acetabulum. As the synovial inflammation decreases toward the end of the acute stage, there is an increase in fibrous tissue deposition. The acute stage is followed by the chronic stage, which lasts from 3 to 5 years and follows a less predictable course than the acute stage. At the end of the chronic stage, the affected hip will manifest one of three possible outcomes: (a) the involved hip may continue to deteriorate to a painful and malpositioned ankylosis; (b) the involved hip may become stiff and ankylosed in a position that limits function but causes minimal pain; and (c) the involved hip may show resolution of pain, improved motion, and partial or complete return of joint space, as evidenced by radiographs[15].

Various treatment options available for idiopathic chondrolysis of hip are Nonsurgical treatment include nonsteroidal antiinflammatory medications, aggressive physical therapy, periodic traction with bed rest, and prolonged protected weight bearing. In 1985, Hughes reported the use of continuous passive motion in the acute stage of idiopathic chondrolysis of the hip in one patient, in whom a good range of hip motion was maintained even during the acute stage.

Surgical treatment includes soft tissue releases, excision arthroplasty, Wagner resurfacing arthroplasty, total hip arthroplasty and arthrodesis.

Since our patient presented at a very late stage of the disease with a non functional ankylosed painful hip we went ahead with total hip arthroplasty for the affected hip. And following the surgery, the patient had a very good functional outcome as determined by the serial Harris hip score measurement. We conclude that this case enriches the

existing data regarding the treatment options for idiopathic chondrolysis of hip in a young patient

References

- [1] Waldenstrom J. On necrosis of the joint cartilage by epiphyseolysis capitis femoris. *Acta Chir Scand* 1930; 67:939-46.
- [2] Cruess R L. The pathology of acute necrosis of cartilage in slipping of the capital femoral epiphysis. A report of two cases with pathological sections. *J Bone Joint Surg* 1963; 45A:1013-24.
- [3] Hartmann J T, Gates D J. Recovery from cartilage necrosis following slipped capital femoral epiphysis. A seven year study of 166 cases. *Orthop Rev* 1972; 1: 33-7.
- [4] Jacobs B. Chondrolysis after epiphyseolysis. In: Instruction course lectures. St Louis CV Mosby, *The American Academy of Orthopaedic Surgeons*. 1972; 21: 224-6.
- [5] Lowe H G. Necrosis after slipped capital femoral epiphysis. A report on sex cases with recovery. *J Bone Joint Surg* 1970; 52B:108-18.
- [6] Maurer R C, Larsen I J. Acute necrosis of cartilage in slipped capital femoral epiphysis. *J Bone Joint Surg* 1970; 52A: 39-50.
- [7] Heppenstall R B, Marvel J P Jr, Chung S M K, Brighton C T. Chondrolysis of the hip. *Clin Orthop* 1974; 103: 136-42.
- [8] Jones B S. Adolescent chondrolysis of the hip joint. *S Afr Med J* 1971; 45: 196-202.
- [9] Duncan J W, Schrantz J L, Nasca R J. The bizarre stiff hip, possible idiopathic chondrolysis. *JAMA* 1979; 231: 382-5.
- [10] Moule N J, Golding J S S R. Idiopathic chondrolysis of the hip. *Clin Radiol* 1974; 25: 247-51.
- [11] Wenger D R, Michelson M R, Ponseti I V. Idiopathic chondrolysis of the hip. Report on two cases. *J Bone Joint Surg* 1975; 57A: 268-71.
- [12] Sivananthan M, Kutty M K. Idiopathic chondrolysis of the hip. Case report with a review of the literature. *Aust N Z J Surg* 1977; 47: 229-31.
- [13] Bleck E E. Idiopathic chondrolysis of the hip. *J Bone Joint Surg* 1983; 65A: 1226-75.
- [14] François J, Mulier M. Idiopathic chondrolysis of the hip: A case report. *Acta Orthop. Belg.*, 2007, 73, 653-657.
- [15] Morrissy, Raymond T, Weinstein, Stuart L: Lovell & Winter's Pediatric Orthopaedics, vol 2, 6th ed. Lippincott; 2006: 1146-1149.