

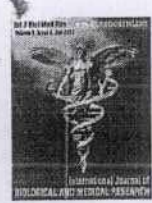PUB: 127/2012



Contents lists available at BioMedSciDirect Publications

International Journal of Biological & Medical Research

Journal homepage: www.biomedscidirect.com



Case Report

Familial fanconi's anemia with bowed and dysplastic right ulna bilateral thumb aplasia: a case report

Krishnappa J*, Krishna Swamy, Kadandale JS*, Dhananjaya C.D*

* Dept. of Pediatrics, R.L. Jalappa Hospital and Sri Devaraj Urs Medical College, Tamaka, Kolar, Karnataka

* Centre for Human Genetics, Tech Park, Electronic City, Bangalore.

ARTICLE INFO

Keywords:

Fanconi anemia
Growth failure
Hyperpigmentation

ABSTRACT

We report a case of Fanconi anemia who presented with growth failure (short stature), bone marrow failure (pancytopenia- aplastic anemia), bilateral absent thumbs, absent right radius, bowed and dysplastic right ulna, café-au-lait spots, hyperpigmentation, and absent left kidney. Fanconi anemia (FA) is a rare autosomal recessive disorder. It is the most commonly inherited constitutional aplastic anemia (1). Patients of FA typically have short stature, hyperpigmentation, skeletal malformations, progressive pancytopenia, increased risk of malignancy (2). Fanconi cells are characterized by chromosomal hypersensitivity to cross linking agents and the resulting increase in chromosomal breakage provides basis for the diagnostic test (3). Palliative therapy consists of treatment with androgens or oxymetholone and steroids. Corrective therapy is bone marrow transplantation and recent modalities of therapy include gene therapy using lenti virus or retro virus as vectors.

© Copyright 2010 BioMedSciDirect Publications IJBMR -ISSN: 0976:6685. All rights reserved.

1. Introduction

In 1927, Fanconi described 3 siblings with growth retardation, hyperpigmentation and other skeletal deformities associated with pancytopenia [1]. Fanconi anemia is usually diagnosed in childhood and rarely in infants [2]. FA is one of the most extensively investigated autosomal recessive genetic disorders associated chromosomal breakage (instability) syndromes (Bloom's syndrome, Ataxia Telangactasia, Werner syndrome...) in which spontaneous chromosome breakages were observed [3,4].

Fanconi anaemia (FA) is an autosomal recessive disease characterised by congenital abnormalities, defective haemopoiesis, and a high risk of developing acute myeloid leukaemia (AML) and certain solid tumours. Chromosomal instability, especially on exposure to alkylating agents, may be shown in affected subjects and is the basis for a diagnostic test. [5]. FA can be caused by mutations in at least seven different genes. Interaction pathways have been established, both between the FA proteins and other proteins involved in DNA damage repair; such as ATM, BRCA1 and

BRCA2, thereby providing a link with other disorders in which defective DNA damage repair is a feature. The incidence of FA is approximately three per million and the heterozygote frequency is estimated at 1 in 300 in Europe and the United States. FA has been reported in many ethnic groups and founder mutations have been described in Ashkenazi Jews, who have an approximate carrier frequency of 1 in 89, and Afrikaners where the carrier frequency was estimated at 1 in 83 [6]. Fanconi anaemia is a heterogeneous genetic disorder presenting with a variety of congenital defects but invariably results in defective haemoptoiesis which is the major cause of morbidity and mortality [7].

2. Case Report

A 5 years old female child, third child of non-consanguineous parents presented with easy fatigueability and pallor of 3 months duration. The patient received haematinics in different local hospitals. The child's first sibling was known to have died of similar illness.

On examination, child was conscious and active. Anthropometric measurements indicate growth retardation ; weight- 7 kg, height- 82cms, head circumference- 42cms, chest circumference- 42cms, mid arm circumference- 11.5cms (all parameters are < 3rd percentile). The child had a pulse rate of 110/ min, respiratory rate of 25/ min, BP of 90/50 mm Hg with normal temperature. Patient had microcephaly, small face and small eyes. Multiple café-ul-lait spots present over the back, abdomen and thighs of varying sizes.

* Corresponding Author : Dr. J. Krishnappa

Associate professor, Pediatrics

RLJH, Kolar, Karnataka

Ph: 9448587233

E-Mail: drjkgowda@gmail.com

© Copyright 2010 BioMedSciDirect Publications. All rights reserved.

The skeletal malformations include, short right forearm, absence of right radius with curved and dysplastic right ulna and absence of both the thumbs. A grade 2 systolic murmur (haemic murmur) was heard over the pulmonary area, there was no hepatosplenomegaly. Ultrasound examination revealed absent left kidney.

Laboratory investigations revealed- Hb of 2.0g/dl, TLC- 2,800 cells/cmm, RBC- 2.1 mill/cmm, platelet count of 30000 cells/cmm

All cell lines were decreased indicating pancytopenia and bone marrow failure. Peripheral blood smear indicated dimorphic blood picture. A provisional diagnosis of constitutional pancytopenia- fanconi's anemia was made in view of growth retardation, café-au-lait spots, musculoskeletal abnormalities, absent left kidney and bone marrow failure.

Radiography of skeletal system revealed absence of right radius, bowed and dysplastic right ulna, absence of both thumbs.

2.1. Chromosomal analysis

Mitomycin C induced chromosomal breakage study of cultured peripheral blood lymphocytes from this patient revealed a female 46XX chromosome complement with radial arrangements of chromosomes and multiple chromosomes/ chromatin breaks with a mean chromosomal breakage frequency of 1.28 breaks per cell (normal range 0.00-0.36). (chromosomes involved in breakage : 1p&q, 2p&q, 3p&q, 4p,5q, 6p&q, 10q, 11p&q, 12p&q, 13p, 17q, 18q,Xq)

This patient is being administered Nandrolone deconate 2mg/kg once a week with low dose prednisolone, blood transfusions as indicated including supportive care.

3. Discussion

Fanconi's anemia is a rare genetic disorder with an incidence of 1 per 350,000 births and higher frequency in Ashkenazi jews and African population in South Africa (1).The disease is named after the Swiss paediatrician Guido Fanconi who originally described the disorder in three brothers, in 1927. Fanconi's anemia is remarkable, its phenotype heterogeneity, which includes bone marrow failure and a variety of congenital malformations. Fanconi's anemia has been found in a variety of ethnic groups. It is characterized by pancytopenia, progressive aplastic anemia, diverse congenital malformations which include skeletal malformations, hyperpigmentation, urogenital, renal and cardiac anomalies. Our case had growth failure, skeletal malformations, café-au-lait spots, bone marrow failure and absence of left kidney.

The hematological disorders resulting from bone marrow dysfunction (thrombocytopenia, leucopenia and anemia) usually appear around a mean age of 7 years, but they can arise very early at birth or even more rarely around 40 years of age. These patients are prone to develop different types of cancers, commonly leukemia (AML), less commonly liver tumors, cancers of mouth, tongue, throat, genitals and brain tumors. Fanconi's anemia is specifically diagnosed by chromosomal breakage test. These

genetically determined disorders are collectively called chromosome breakage syndromes or DNA repair disorders. They are characterized by a susceptibility to chromosomal anomalies with a higher frequency of aberrations, spontaneous or induced by exposure to cross linking (clastogenic) agents like Mitomycin-C and Di-epoxybutane that damage DNA [5].

One of the defining characteristics of fanconi's anemia is hypersensitivity to cytotoxic and clastogenic effects of DNA cross-linking agents, such as mitomycin C, diepoxybutane etc. There are at least 13 different gene pairs (complementation groups) responsible for fanconi's anemia. The first line of treatment includes androgens like oxymetholone and nandrolone with low dose prednisolone and haematopoietic growth factors, but only 50-75% respond and its temporary. A more permanent cure is stem cell transplantation. The success of bone marrow transplantation depends on matched sibling donors. Gene therapy using lenti virus and retro virus is a promising experimental therapy. Pre natal diagnosis is possible to examine the sensitivity to DNA cross linking agents of amniotic cells taken from heterozygous mothers. Genetic counseling as per standard established for all autosomal diseases.

FA with bowed and dysplastic ulna reported to be less frequent among the affected patients, further investigations on immortalizing cells from the patient for molecular biological studies to prove the defects in DNA repair enzymes is in progress.

Table 1. Fanconi anemia – Chromosomal instability*

FA patient group	Chromosomal instability (% cases)
Classical FA	33 (17)
Somatic mosaicism FA	9 (4)
FA without clinical features	25 (13)
Suspected FA without classical FA Phenotype and chromosomal breakage	128 (66)
TOTAL	195

*Korgaonkar S, Ghosh K, Vundinti BR [8].

Fig. 1. Proband (5 yrs old) showing grown retardation, and limb anomalies (bowed, Ulna, radial aplasia, bilateral thumb aplasia).

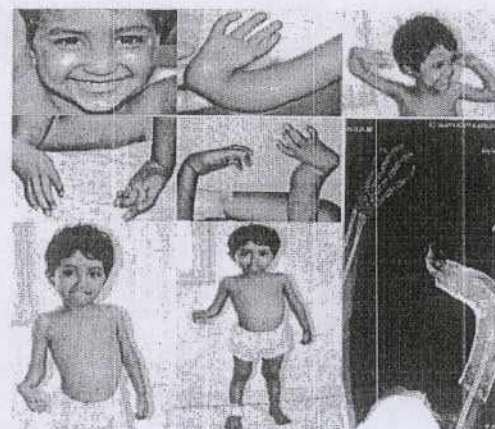

Fig. 2a Karyotype showing chromosome breakage (chromatid breaks, gaps)

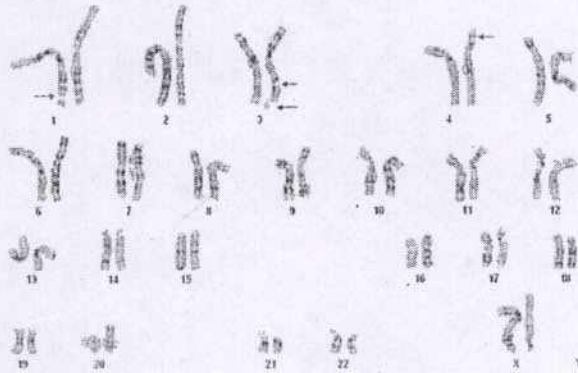
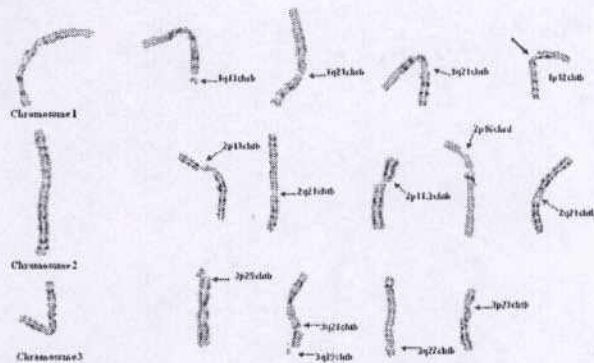


Fig. 2b. Chromosome showing chromosome breakage induced by Mitomycin-C



4. References

- [1] Fanconi G. Familial constitutional panmyelocytopenia: Fanconi anemia (FA) I. Clinical aspects, Seminars in Hematology. 1967; 4: 233-240.
- [2] German J. Neoplasia and chromosome breakage syndrome: German J. In: Chromosome mutation and neoplasia. AR. Liss New York, 1983, pp. 99-134.
- [3] Saalci MS, Tonomura A. A high susceptibility of Fanconi anemia to chromosome breakage by DNA cross linking agents. Cancer Res. 1978; 33: 1829-1836.
- [4] Glanz A, Fraser FC. Spectrum of anomalies in Fanconi anemia. J Med Genet 1982; 19: 412-416.
- [5] McKusick VA. Mendelian inheritance in man. Johns Hopkins University Press, Baltimore. 1988; 930-932.
- [6] Rosendorff et al. Fanconi anemia - another disease of unusually high prevalence in the Afrikaans population of south Africa. Am J Med Genet. 1987; 27: 793-797.
- [7] Tischkowitz MD, Hodgson SV. Fanconi anaemia - A review. J Med Genet 2003; 40: 1-10.
- [8] Korgaonkar S, Ghosh K, Jijina F, Vundinti BR. Chromosomal breakage study in children suspected with Fanconi anemia in the Indian population. J Pediatr Hematol Oncol. 2010 Nov; 32(8): 606-610.
- [9] Korgaonkar S, Ghosh K, Vundinti BR. Clinical, genetic and cytogenetic study of Fanconi anemia in an Indian population. Hematology. 2010 Feb; 15(1): 58-62.

