

GASTROCNEMIUS - ACHILLES TENDON: A HUMAN ANATOMICAL VARIATION

Gurucharan Singh, Vijay Prakash Agrawal*, M Basavarajappa, M Manohar

Department of Plastic surgery, Sri Devraj Urs Medical College, Tamaka, Kolar-563101, Karnataka, India

E-mail of Corresponding Author: vijugunnu@gmail.com

Abstract

Gastrocnemius muscle forms the belly of the calf. It arises by two heads. Each head is attached to either condyles of the femur by strong flat tendons and to the subjacent part of the capsule of the knee joint. Normally the upper third and part of the middle third is fleshy and then it becomes tendinous, uniting with the tendon of soleus, to form the tendo-achilles. The tendo-achilles is the thickest and strongest tendon in the human body measuring 15cm in length. It begins near the middle of the leg and gets attached to the posterior, mid level of the calcaneum.

We are reporting new anatomical variations ie.

1. Lateral and medial heads of Gastrocnemius are fleshy in its entire length.
2. Fleshy fibres of the lateral and medial heads are discrete and attach directly to the posterior aspect of the calcaneum.
3. Total absence of the achilles tendon.

At the outset these findings have clinical relevance because it has been suggested that the absence of a well developed achilles tendon in the African apes would preclude them from effective running. Bilateral achilles tendon vibration in the absence of vision has a major impact on postural orientation. Secondly the routine procedure of flap cover for the middle third soft tissue defects of the leg is the usage of soleus muscle flap. To add to the armamentarium of flap cover for middle third defects of the leg, gastrocnemius muscle flap is used as it was found to be fleshy throughout.

Keywords: Gastrocnemius muscle, Human anatomical variation, middle third defect, muscle flap, Achilles tendon

1. Introduction

Gastrocnemius and soleus muscles make up the three headed triceps surae. The large size of these two muscles is a human characteristic related to upright stance and bipedal locomotion. These muscles help in lifting, propelling and accelerating the weight of the body when walking, running, jumping or standing on the toes.

The Achilles is the tendinous expansion of two muscles gastrocnemius and soleus. It is the thickest and strongest tendon in the body. The tendon spreads out at its lower end becoming thicker and narrower as it descends until it becomes essentially round in cross section superior to the calcaneum and its narrowest part is 4 cm above the insertion and inserts centrally on the posterior surface of the calcaneal tuberosity. The calcaneal tendon spirals 90° during its descent so that the gastrocnemius fibers attach laterally and the soleus fibers medially. This arrangement is thought to be significant to the tendons elastic ability to absorb shock and recoil. It is covered by fascia and stands out prominently behind the bone; the gap

between the two is filled with areolar and adipose tissue. The tendon can receive a load stress of 3.9 times the body weight during walking and 7.7 times the body weight when running as reported by Giddings *et al*¹.

2. Case study

A 26year old male presented in the casualty department of R. L. Jalappa hospital in a state of shock. He had the following injuries as a consequence of road traffic accident.

1. Compound comminuted fracture of the left tibia.
2. Compound segmental fracture of the left fibula.

Resuscitative measures were executed. Emergency wound debridement, stabilization of the fracture segments and external fixators were applied. Subsequently the case was referred to the plastic surgery department for wound cover. Examination revealed,

1. Exposed fractured segments of the left tibia in its middle third with external fixator. (Figure 1)

100

THE HISTORY OF THE UNITED STATES

OF THE UNITED STATES OF AMERICA
FROM THE FIRST SETTLEMENTS TO THE PRESENT TIME
BY JAMES M. SMITH

THE HISTORY OF THE UNITED STATES
OF THE UNITED STATES OF AMERICA
FROM THE FIRST SETTLEMENTS TO THE PRESENT TIME
BY JAMES M. SMITH

THE HISTORY OF THE UNITED STATES
OF THE UNITED STATES OF AMERICA
FROM THE FIRST SETTLEMENTS TO THE PRESENT TIME
BY JAMES M. SMITH

THE HISTORY OF THE UNITED STATES
OF THE UNITED STATES OF AMERICA
FROM THE FIRST SETTLEMENTS TO THE PRESENT TIME
BY JAMES M. SMITH

THE HISTORY OF THE UNITED STATES
OF THE UNITED STATES OF AMERICA
FROM THE FIRST SETTLEMENTS TO THE PRESENT TIME
BY JAMES M. SMITH

THE HISTORY OF THE UNITED STATES
OF THE UNITED STATES OF AMERICA
FROM THE FIRST SETTLEMENTS TO THE PRESENT TIME
BY JAMES M. SMITH

THE HISTORY OF THE UNITED STATES
OF THE UNITED STATES OF AMERICA
FROM THE FIRST SETTLEMENTS TO THE PRESENT TIME
BY JAMES M. SMITH

THE HISTORY OF THE UNITED STATES
OF THE UNITED STATES OF AMERICA
FROM THE FIRST SETTLEMENTS TO THE PRESENT TIME
BY JAMES M. SMITH

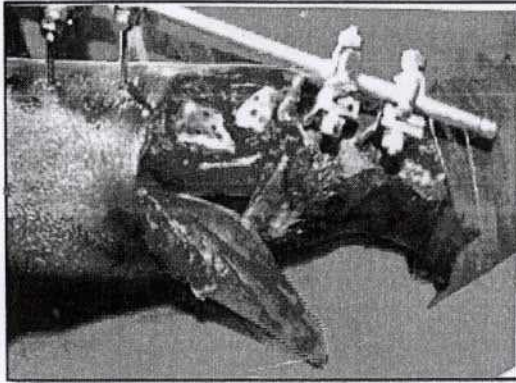


Figure 1 - Medial aspect of the left leg showing the exposed fractured segments and tunneled medial head of the gastrocnemius

2. Skin was necrosed over the lateral aspect of the left leg.

PLAN

1. Excision of the necrosed portion of the skin.
2. Soleus muscle flap cover for the middle third defect with split skin graft.

On the operating table the necrosed portion of the skin over the lateral aspect of the left leg was excised and the cleavage between the gastrocnemius and soleus was obtained. Surprisingly the whole of the gastrocnemius its medial and lateral heads were muscular and were found to attach directly to the calcaneum, Achilles tendon was absent. Re examination was done and the findings were confirmed. (Figure 2)

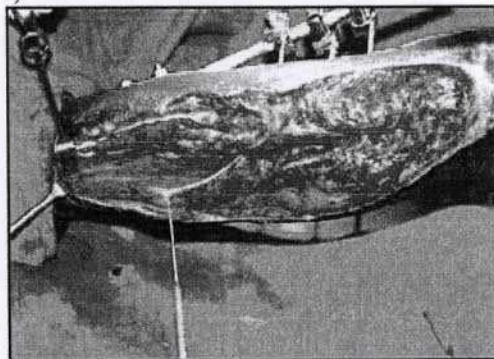


Figure 2 - Lateral view of left leg after excising the necrosed tissue showing the fleshy bellies of gastrocnemius throughout

Plan was changed. The medial head of the gastrocnemius was cut at its insertion, tunneled and covered over the fracture segments and skin grafted. (Figure 3 and Figure 4)

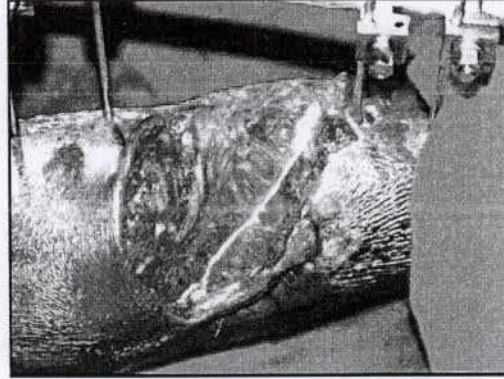


Figure 3 - gastrocnemius muscle flap over the fractured segments

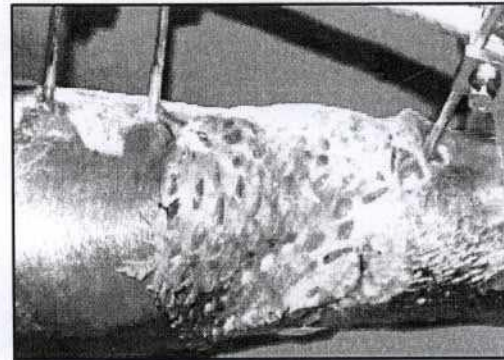






Figure 4 - Subsequent Skin grafted

3. Discussion:

In view of the phylogenetic history and its development in humans, the gastrocnemius has been considered a muscle of the fibular side of the leg.

Macalister ² reported the variations of gastrocnemius as follows;

1. Gastrocnemius may have a sesamoid bone in its medial head;
2. Or in its lateral head-this more common;
3. Or the two heads are separable further down than usual;
4. Or their tendon is perfectly separate from that of the soleus for a few inches;
5. The lateral head may have a few lower fibers attached to the external lateral ligament (ligamentum calcaneofibulare, ligamentum talofibulare anterius and ligamentum talofibulare posterius);
6. Or to the posterior ligament of Winslow (ligamentum collateral fibulare);
7. A third head may be found from the middle of the popliteal triangle of the femur, and with a second slip from the posterior



ligament of Winslow (ligamentum collaterale fibulare);

8. Or it may arise from the line leading from the medial condyle to the linea aspera, an inch (2.54cm) above the medial head-this ended in a short tendon, which crossed the popliteal nerve, and inserted into the convergence of the two heads;
9. It may arise from a tendinous arch from the same ridge, higher up, which extends over the femoral vessels;
10. Or from the medial border of the long head of the biceps forming a bicipiti accessories, similar to that of the lion, and many mammals;
11. Or from the fascia of the leg;
12. An intermediately arising third head, like 7. Above, may be inserted with the lateral head;
13. Hyrtl describes an instance of this third head separate for a considerable extent;
14. The entire muscle may be bilaminar;
15. The lateral head may be entirely tendinous.

Absence of the lateral head of gastrocnemius has been reported by Shepherd³. The third head is the most common variation of the gastrocnemius and has been extensively studied over a period of 200 years. Kelch⁴ is generally cited as the first to report the third head. The third head commonly joins the medial head of gastrocnemius and regardless of whichever head it joins has an overall frequency of 2.9-5.55%. A third head joining the medial head of gastrocnemius is most commonly cited as causing clinical problems like intermittent claudication, arterial stasis, aneurysm, venous stasis and impaired nerve function because of involvement of neurovascular bundle in the popliteal fossa as reported by Hamming⁵. The same findings have also been illustrated by Frey⁶, who also described twelve varieties in the third head of gastrocnemius.

The Achilles tendon is short or absent in great apes, but long in arboreal gibbons and humans. It provides elastic energy storage in hopping, walking and running. Computer models suggest that this energy storage in Achilles tendon increases top running speed by >80% and reduces running costs by more than three quarters. It has been suggested that the absence of a well developed Achilles tendon in the non human African apes would preclude them from effective running, both at high speeds and over extended distances as reported by Sellers *et al*⁷.

Conclusion

In this case, we are reporting new variations of the gastrocnemius muscle. We believe that these variations have not been reported earlier.

1. The lateral and medial heads are fleshy in its entire length.
2. Fleshy fibers of the lateral and medial heads are discrete and attach directly to the posterior aspect of the calcaneum.
3. Total absence of the tendinous portion.

Having noted these variations, we bypassed the conventional usage of soleus muscle flap cover for mid third defects in the leg and used the gastrocnemius muscle with split skin graft for cover.

References:

1. Giddings VL, Beaupre GS, Whalen RT *et al*. Calcaneal loading during walking and running. *Med Sci sports exerc.* 2000;32(3):627-634. PMID 10731005
2. Macalister, A. observations on muscular anomalies in human anatomy. Third series with a catalogue of the principal muscular variations hitherto published. *Trans .Roy. Irish Acad. Sci.* 1875; 25: 1-130.
3. Shepherd, F.J. Notes of abnormalities observed in the dissecting - room of. McGill University, from October, 1875, to May, 1879. *Canada Med. Surg. Journal.* 1880; 1:71-93
4. Kelch, W.G. Beitrage zur pathologischen anatomie, abweichung des biceps femoris. C.Salfeld, Berlin 1813; 8, s.42, art.36
5. Hamming, J.J. Intermittent claudication at an early age, due to an anomalous course of the popliteal artery. *Angiology* 1959; 10:369-371
6. Frey, H. Der musculus triceps surae III der primatenreihe. *Gegenbaurs Morphol. Jahrbuch.* 1913; 47: 162-189
7. Sellers WI, Patahy TC, Carvaggi P *et al* evolutionary Robotie Approaches in primate gait analysis *Int J primatol* 2010; 31:338

The following information was obtained from the records of the Department of the Interior, Bureau of Land Management, for the period 1900 to 1909. The information is presented in the form of a table, showing the number of acres of land in each of the following categories: (1) land in the public domain, (2) land in the hands of private individuals, (3) land in the hands of corporations, and (4) land in the hands of the Government. The table is divided into two parts, one for the years 1900 to 1905, and another for the years 1906 to 1909. The first part shows the number of acres of land in each category for each year, and the second part shows the total number of acres of land in each category for the entire period. The information is presented in the form of a table, showing the number of acres of land in each of the following categories: (1) land in the public domain, (2) land in the hands of private individuals, (3) land in the hands of corporations, and (4) land in the hands of the Government. The table is divided into two parts, one for the years 1900 to 1905, and another for the years 1906 to 1909. The first part shows the number of acres of land in each category for each year, and the second part shows the total number of acres of land in each category for the entire period.