

# Multiple Pin Wheel Flaps and Its Modification in Special Areas of the Scalp

Gurcharan Singh, Nikhil S Shetty

## ABSTRACT

Closure of the defects in special areas of the scalp, such as forehead, above the ear and occipital protuberance produces distortion of the hairline, lifting of the eyebrow, lengthy scars and distortion of the ear. The treatment of this distortion presents a challenge, for which we had a very favorable response with modification of the original four flap closure in a pinwheel fashion as described by TR Vecchione.

In our series of eight cases, five flaps were marked at various convenient degrees instead of four flaps as originally described. In scalp defects in and around the hairline the length of the five flaps results in a smaller scar, without changing the hairline, lifting the eyebrow or distorting the position of the pinna.

**Keywords:** Special areas of the scalp, Four flap, Modification, Favorable response.

**How to cite this article:** Singh G, Shetty NS. Multiple Pin Wheel Flaps and Its Modification in Special Areas of the Scalp. *Int J Head Neck Surg* 2012;3(2):73-75.

**Source of support:** Nil

**Conflict of interest:** None

## INTRODUCTION

TR Vecchione described multiple pinwheel flaps for closure of the scalp defects based on the principle of closure by combination of multiple Limberg flaps.<sup>1</sup> The four flap closure in a pin wheel fashion can be used anywhere over the scalp, since the mobility and blood supply are relatively uniform.<sup>2</sup> Lateral movement and rotation are the basis of the surgical procedure, where in four flaps are rotated at 0°, 90°, 180° and 270° on the excised circle.<sup>3,5</sup>

The length of the flaps is twice the diameter of the excised lesion.<sup>4,5</sup> In special areas such as forehead, above the ear and occipital protuberance, this procedure produced distortion of the hairline, eyebrow, ear and lengthy scars. The treatment of this distortion presents a challenge, for which we had a very favorable response with modification of the original procedure.

## MATERIALS AND METHODS

In this series instead of four, five flaps were marked on the excised defect at various convenient degrees. Length of the flaps were reduced to the diameter of the defect or modified further, reducing the scar over the forehead, in front and above the ear, and over the occipital region. In these patients the scars were smaller in length and cosmetic results were better.

In case 1, a 40 years old female sustained injuries in road traffic accident with loss of scalp tissue over the forehead near the hairline (Fig. 1). To prevent long scars, distortion of the hairline and elevation of the eyebrow, five pin wheel flaps were marked, raised and wound cover achieved (Fig. 2).

In case 2, a 60 years old male treated for encephalopathy was referred to plastic surgery department for the management of occipital pressure sore (Fig. 3). Five pinwheel flaps were marked, raised and wound cover achieved (Fig. 4).

In case 3, a 50 years old male referred from the ENT department after excising the necrosed scalp tissue and draining of the abscess above the left ear (Fig. 5). The underlying bone was exposed. Five pinwheel flaps were marked at convenient degrees, raised and wound cover achieved without distorting the position of the pinna (Fig. 6).

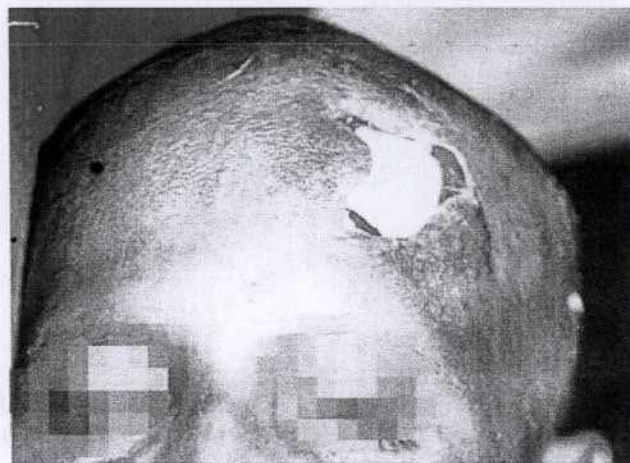

Fig. 1: Post-traumatic soft tissue loss over the scalp

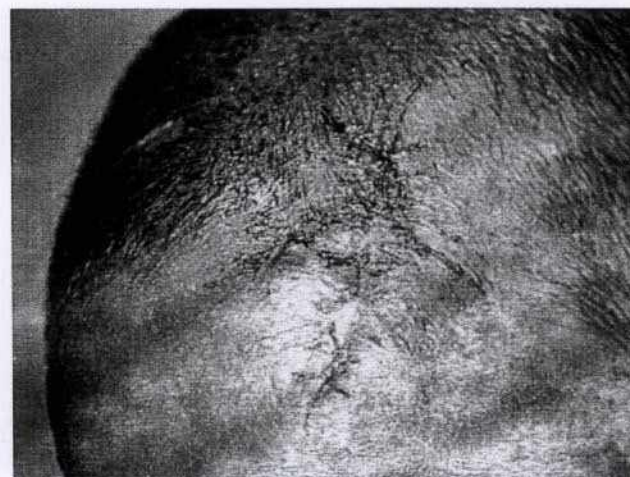

Fig. 2: Outcome after using modified multiple pin wheel flap



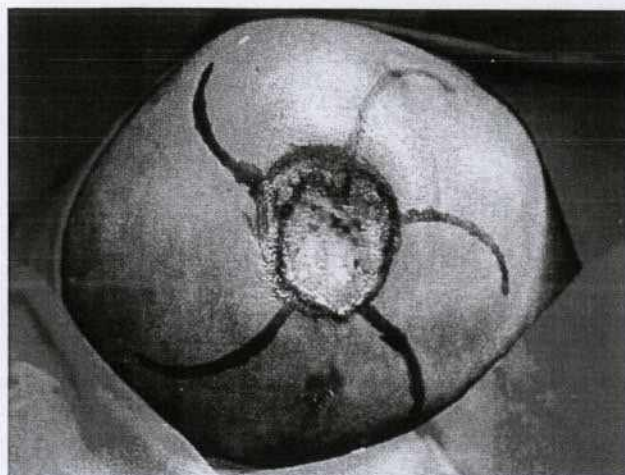


Fig. 3: Tissue loss over the occipital region due to pressure sore

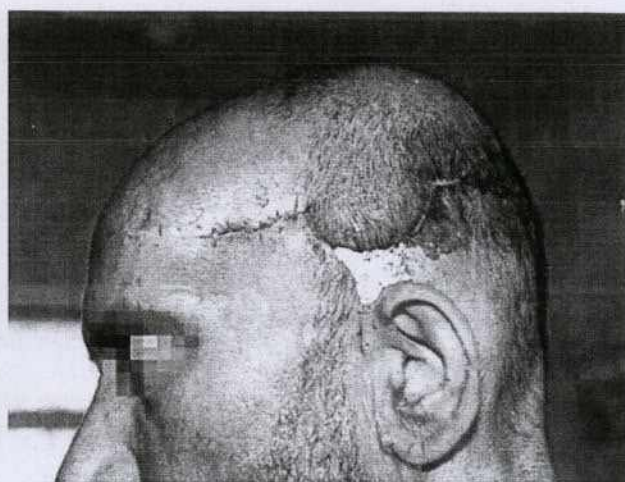


Fig. 5: Soft tissue loss following cellulitis and wound debridement

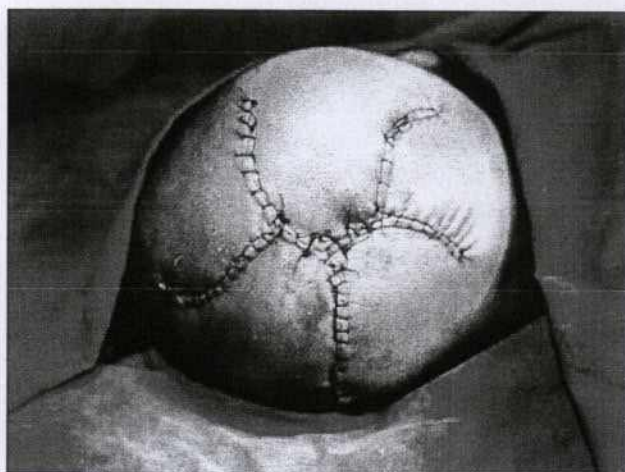


Fig. 4: Complete wound cover achieved after surgical repair

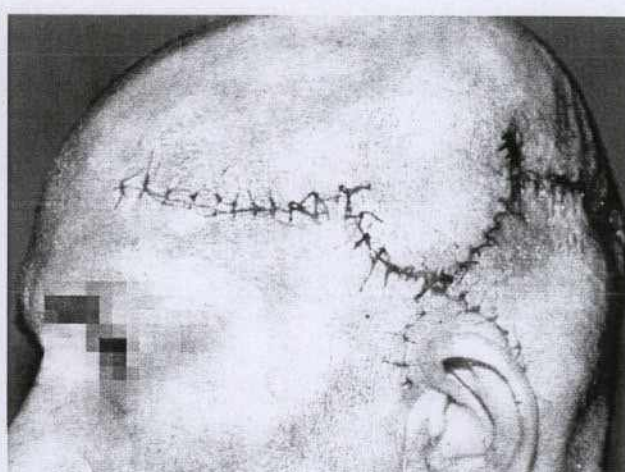


Fig. 6: Closure of the defect done along with proper cosmesis

## DISCUSSION

Scalp injuries and their management have been perplexing. A poorly designed scalp closure with excessive tension in time yields a wide, atrophic and unsightly scar. In many patients, this complication proves refractory to corrective surgical attempt. Scalp flaps whenever possible, should be local flaps because of the singularity of the hair bearing surface. With people becoming more conscious about looks, cosmetic appearance has been given utmost importance in trauma care too. Skin expanders are currently quite popular and effective in correcting scalp defects. However, this requires two stages. Massive defects may require the use of distant skin but a compromised esthetic result is inevitable. The rigidity of the scalp does not lend itself to some of the more popular and useful flaps. Hence, one is limited to transposition, interpolation or rotation design.<sup>6</sup> A pinwheel flap recruits more tissue thereby spreading tension over a greater area. TR Vecchione's application of four Limberg flaps in a pinwheel fashion pattern is a marvellous

achievement; where in no extra tissue is brought from other parts of the body (Fig. 7).<sup>7</sup>

## Other Methods

Bardach modification of the curved tripod flap confirms the value of this flap in scalp reconstruction. The main advantages of this method are the natural appearance of the final result due to preservation of hair orientation, and the uniform distribution of the wound-closure tension over a wide peripheral area of the scalp, although extensive undermining is generally required.<sup>8</sup>

The forehead and scalp constitutes a single anatomic unit differentiated only by the location of the hairline. Preservation of this hairline in a normal configuration is of primary consideration because it creates the frame of the upper face in the frontal and temporal areas. Disruption and asymmetry of this frame is to be avoided. However, in special areas five flap modification gives a better outcome than Bardach and Vecchione's procedure. In scalp defects



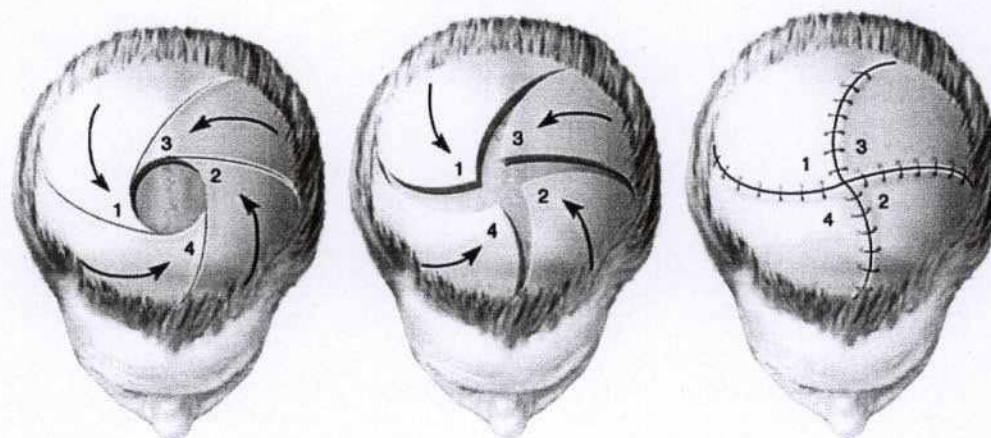


Fig. 7: TR Vecchione's pin wheel flap

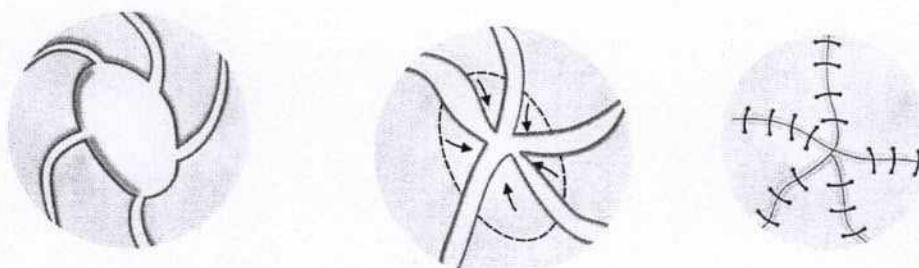


Fig. 8: Modification of pin wheel flap

in and around the hairline the length of the five flaps results in a smaller scar, without changing the hairline or lifting the eyebrow. In scalp defects over the occipital protuberance this modification gave us a favorable response relatively free of the above complications. In Vecchione's procedure flaps need to be raised at  $0^\circ$ ,  $90^\circ$ ,  $180^\circ$  and  $270^\circ$  which might not be practically feasible at times in special areas of the scalp where a better cosmetic appearance is required. But a five flap modification does not adhere to any rigid protocol and thereby can be used with ease in special areas of the scalp for a better cosmetic outcome (Fig. 8).

## REFERENCES

1. Strauch B, Vasconez LO, Findlay EJH. Grabbs's encyclopedia of flaps (3rd ed). Lippincott-Raven. Philadelphia 2009:7-8.
2. Limberg AA. Design of local flaps. Modern trends in plastic surgery (2nd ed). London; Butterworth 1996.
3. Lister GD, Gibson T. Closure of rhomboid skin defects: The flaps of Limberg and Dufourmental. Br J Plastic Surg 1972;25:300.
4. Brobyn T, Cramor L, Hulnick S, Rodsi M. Facial resurfacing with the Limberg flap. Clin Plast Surg 1976;3:481.

5. Limberg AA. Mathematical principles of local plastic procedures on the surface of human body. Leningrad: Medgis 1946.
6. Jervis W, Salyer KE, Vargas-Busquets MA, Atkins RW. Further application of the Limberg and Dufourmental flaps. Plast Reconstr Surg 1974;54:335.
7. Seline PC, Siegle RJ. Scalp reconstruction. Dermatol Clin 23 2005:13-21.
8. Michaelidis IG, Stefanopoulos PK, Papadimitriou GA. The triple rotation scalp flap revisited: A case of reconstruction of cicatricial pressure alopecia. Int J of Oral and Maxillofacial Surg 2006; 35(12):1153-55.

## ABOUT THE AUTHORS

### Gurcharan Singh

Professor and Head, Department of Plastic Surgery, Sri Devaraj URS Medical College, Kolar, Karnataka, India

### Nikhil S Shetty

Resident, Department of General Surgery, Sri Devaraj URS Medical College, Kolar, Karnataka, India

**Correspondence Address:** Shivaprabha Near Mahalingeshwara Temple Pumpwell, Kankanady, Mangalore-575002, Karnataka, India  
e-mail: dr\_shettynikhil@yahoo.co.in

