



Review article

Benign Intra Scrotal Cystic Lesions

B N Kishore kumar^{*1}, Premsai Reddy², Kirana Mai³

¹Professor & HOD, ^{2&3}Post Graduate Resident, Department of Radio Diagnosis

Sri Devaraj URS Medical College, Kolar, Karnataka.

ABSTRACT

Benign intrascrotal lesions are common in clinical practice and recognition is important to avoid surgical intervention. We summarize important ultrasound features of benign intrascrotal lesions including intratesticular lesions (tunica albuginea cysts, testicular simple cysts, epidermoid cysts, cystic ectasia of the rete testis, intratesticular varicocele, abscess and paratesticular lesions (cystadenomas, spermatoceles, hydroceles, varicoceles).

The sonographic appearance of hydrocele are fluid collections confined to antero lateral portions of scrotum. Hematocele and pyoceles are less common and contain internal echoes and loculations. Both epididymal cysts and spermatoceles have similar sonographic features. Spermatoceles are usually noted in head of epididymis where as epididymal cysts arise from throughout the length of epididymis. An intratesticular spermatocele communicates with the seminiferous tubules, whereas simple ectasia of the rete testis does not do so directly. The sonographic appearance of epidermoid cysts varies with the maturation, compactness, and quantity of keratin present. An abnormal rind of parenchyma with increased echogenicity usually surrounds these lesions.

The sonographic findings of intratesticular varicocele are similar to those of extratesticular varicocele and include multiple anechoic, serpiginous, tubular structures of varying sizes. Papillary cystadenomas of epididymis may be seen in patients with Von Hippel Lindau disease. Improvements in high resolution of US technology allow subtle differences between scrotal lesions. This review provides the reader with a better understanding of cystic lesions that occur in the scrotum.

KEYWORDS: Benign intrascrotal lesions, Sonographic findings

INTRODUCTION

Ultrasonography is the modality of choice for assessment of scrotal lesions with detection sensitivity of nearly 100%. It has accuracy of 98% to 100 % in differentiating intra testicular and extra testicular pathology. Extratesticular lesions

are more common than intratesticular ones, and more than 95% of intratesticular lesions are malignant.[1] Ultrasonography is associated with a high rate of false-positive findings for malignant testicular neoplasms, which are usually treated by means of radical orchiectomy.[2]

Non neoplastic cystic lesions represent a subset of intratesticular lesions of which the majority are benign. It is important for the practicing radiologist to recognize this benign subset to prevent unnecessary surgical exploration.

US Anatomy

Relevant anatomic characteristics at ultrasonography are important for understanding the origin and anatomic location of cystic lesions of scrotum. The tunica vaginalis, a fascia that surrounds the testicle, has a visceral layer and an outer parietal layer. A small amount of fluid is normally present between these layers.

The tunica albuginea, a fibrous layer deep to the tunica vaginalis, closely invests the testicle. Multiple thin septations arise from posterior surface of the tunica albuginea which extend into the interior of the gland, forming an incomplete septum known as the mediastinum testis. In approximately 50% of cases, vessels can be identified within the mediastinum testis by means of color Doppler US.[3] Septa extend from the tunica albuginea, dividing the testis into lobules. The lobules contain seminiferous tubules, which open via the straight tubules into dilated spaces called rete testes within the mediastinum. Rete testes in turn communicate via efferent ductules with the epididymal head the ducts of which continue as the vas deferens in the spermatic cord. The epididymis is a curved structure lying postero lateral to testis. It is composed of a head, body, and tail. The knowledge of arterial supply is

important. Testis is supplied by deferential, cremasteric and testicular arteries.

Cysts of Tunica Albuginea

They are located within tunica. They are usually located on the anterior or lateral aspect of the testis. They are usually asymptomatic. The cysts vary in size from 2 mm to 5 mm in diameter[4]. At ultrasonography tunica albuginea cysts meet all the criteria of a simple cyst. They can be uni- or multilocular. Sometimes the differentiation of a tunica albuginea cyst from an intratesticular simple cyst or a tunica vaginalis cyst is difficult. (Fig 1A)

Simple Cysts

Simple cysts are detected incidentally. Their size is variable and can range from 2 mm to 20 mm in diameter. Simple cysts have an imperceptible wall with anechoic center.[5] The cysts are usually solitary, but they can be multiple. (Fig 1B) Simple cysts can occur anywhere in the testis but are often near the mediastinum testis. Hamm et al reported high incidence of cysts near mediastinum testis which support the theory that they originate from rete testis possibility due to post traumatic or post inflammatory stricture formation.[6] Simple cysts require no treatment. Cystic teratomas may manifest as a cystic mass; however, their usual appearance is that of an inhomogeneous mass containing cystic and solid areas of various sizes[7], which helps differentiate them from simple cysts.

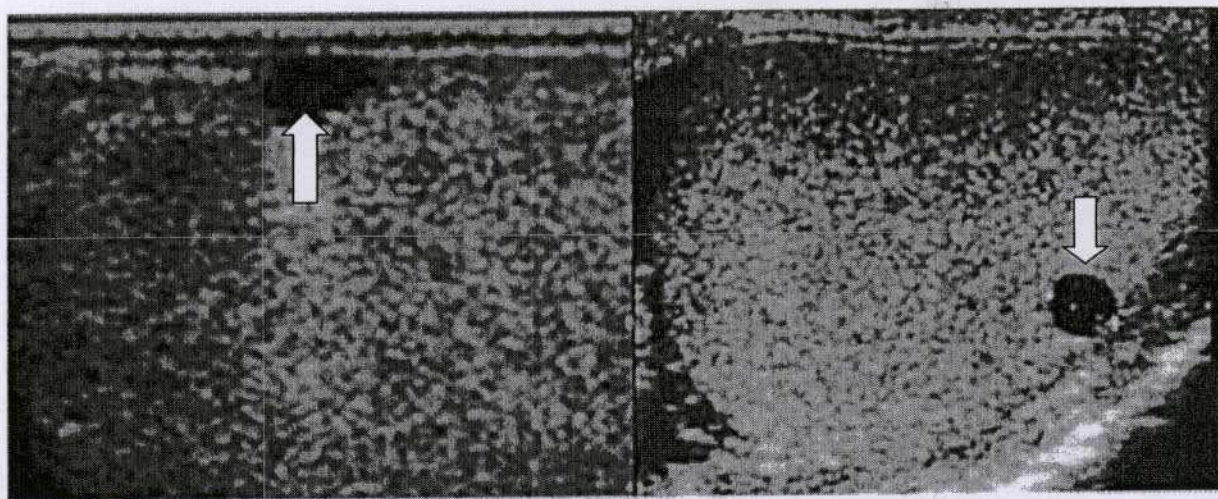


Figure 1. A) Tunica albuginea cyst: Longitudinal scan shows a well-defined cystic lesion in the anterior and upper portion of the testis .B) Simple intratesticular cyst in a 41-year-old man.

Epidermoid Cysts

Is a benign tumor of germ cell origin that are also known as keratocysts, epidermoid cysts range in diameter from 10 mm to 30 mm. They are non-tender and usually palpable. The cyst is filled with flaky cheesy white keratin. The US appearance varies with the maturation, compactness, and quantity of keratin present within the epidermoid cyst. The classic appearance is concentric rings of alternating echogenicity[8]. They generally present as a well defined hypoechoic solid mass with echogenic capsule (Fig 2A). These cysts do not show blood flow at Doppler US examination. The constellation of an echogenic ring configuration, negative tumor marker status, and avascularity helps differentiate testicular epidermoids from other germ cell tumors[9]. If the diagnosis of an epidermoid is suspected at preoperative US, the lesion can be enucleated and frozen sections obtained to confirm the diagnosis. This procedure avoids the need for orchiectomy.

Cystic ectasia of the Rete Testis

This benign condition, also known as tubular ectasia is usually associated with epididymal obstruction secondary to inflammatory or traumatic lesions. It results from partial or complete obliteration of the efferent ductules, which causes ectasia and eventually, cystic transformation. These cysts can be identified at sonography as fluid filled tubular structures (Fig 2B). They are frequently bilateral but is often asymmetric. The location of the lesion in or adjacent to the mediastinum testis and the presence of epididymal cysts are characteristic. There is no flow on colour doppler.

The key to the diagnosis of this condition is the elongated shape that replaces the mediastinum. These features aid in distinguishing cystic transformation of the rete testis from cystic malignant testicular tumors (which can occur anywhere in testicular parenchyma).[10] Teratomas are the most frequent to manifest as cystic masses; however, a cystic tumor is rare, and when present, cystic tumors do not meet all the criteria of a simple cyst. Usually, an abnormal rind of parenchyma with increased echogenicity surrounds cystic malignant tumors.

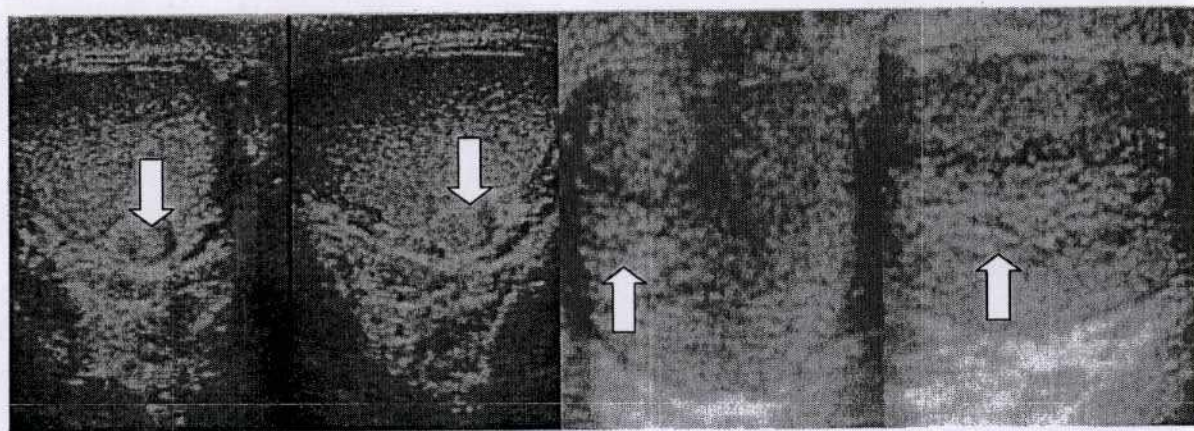


Figure 2- A) Intratesticular epidermoid in a 27-year-old man. Longitudinal US scan shows a well-circumscribed heterogeneous mass with an echogenic rim. B) Longitudinal US scan of the right testis shows cystic ectasia of rete testis

Intratesticular Varicocele

Intratesticular varicoceles can occur in association with extratesticular varicoceles, but their independent existence is also reported.[11] The sonographic findings of intratesticular varicocele are similar to those of extratesticular varicocele

and include multiple anechoic, serpiginous, tubular structures of varying sizes within the testis. Color flow and duplex Doppler US show a venous flow pattern with a characteristic venous spectral waveform, which increases with the Valsalva maneuver (Fig 3A).

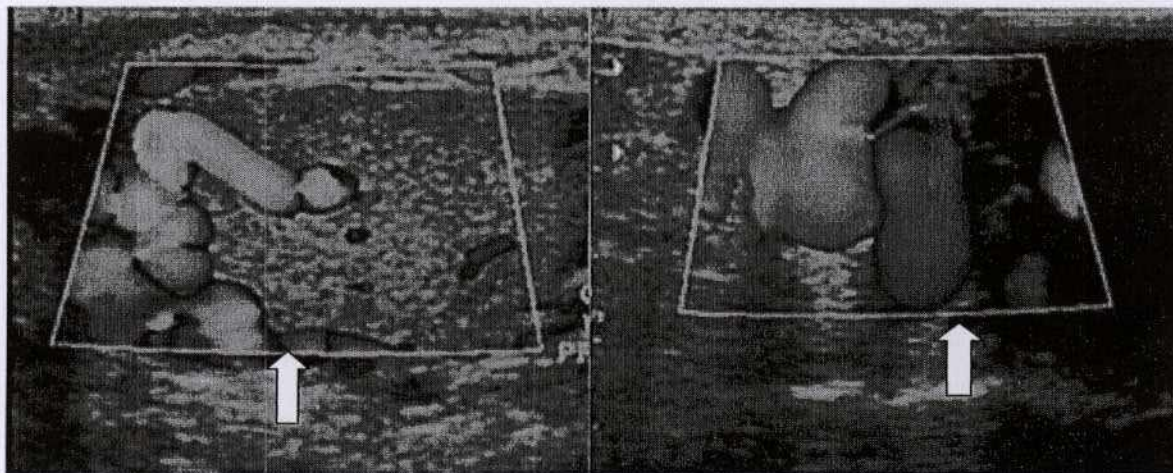


Figure 3. (A) Intratesticular varicocele in a 42-year-old man. Color Doppler US scan shows flow within the tubular structures. (B) Extratesticular Varicocele in a 22 year-old man. Color Doppler US scan shows flow within the tubular structures in the anterior and upper portion of the testis

Intratesticular Abscess

These abscesses are usually secondary to epididymo-orchitis; other causes include trauma, testicular infarction, and mumps. Their sonographic features include enlarged testis containing hypo / mixed echoic mass with shaggy, irregular walls, low-level internal echoes, and occasionally, hypervascular margins (Fig 4A).

Cystadenoma of epididymis:

Papillary cystadenoma is a rare benign neoplasm of the epididymis, occurring mainly in young adult males. More than one-third of the cases reported in the literature have occurred in patients with von Hippel-Lindau disease.[12] Sonographically they are seen round to oval anechoic lesions in head of epididymis. (Fig 4B)

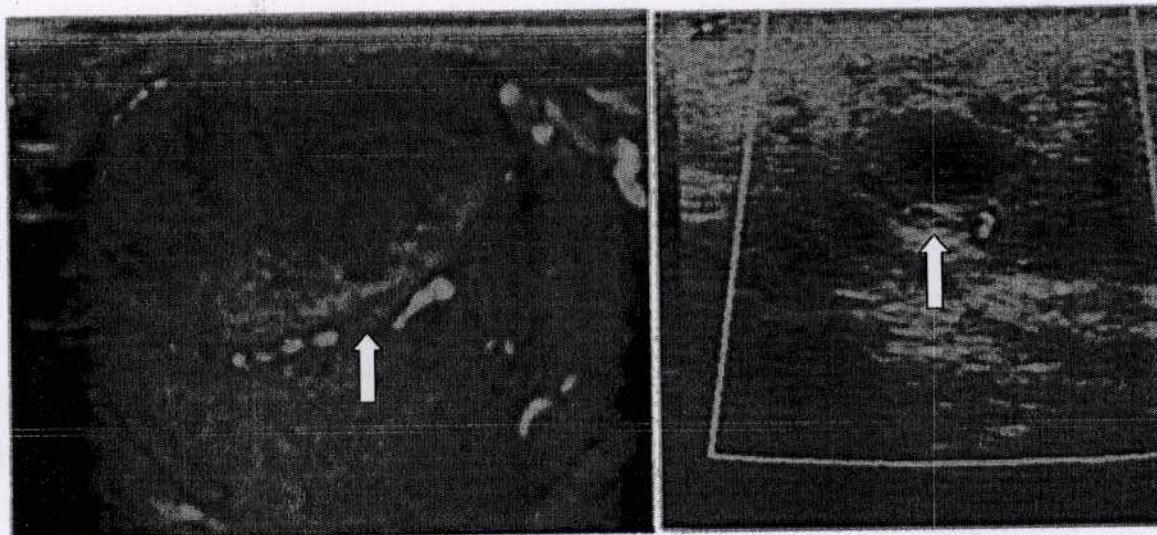


Fig 4. A) Intra testicular abscess in a 30 year-old man. Color Doppler US scan shows flow non homogenous avascular lesion in anterior aspect of left testis. B) Cystadenoma of epididymis in 31 year old man of VHL. Color Doppler US scan shows No flow within the well-defined cystic structure which is antero-lateral to the testis.

Spermatocele :

Spermatoceles are more common. They result from dilatation of epididymal tubules but contents differ.[13] Cysts contain clear serous fluid where as spermatoceles are filled with spermatozoa, cellular debris. Both of them appear identical on sonography as well circumscribed anechoic masses with no or few internal septation. Spermatoceles occur always at epididymal head where as cysts occur throughout the length of epididymis.

Hydrocele & Pyocele:

Fluid may collect between two layers of tunica vaginalis. Normally few milliliters of fluid with in tunica vaginalis is seen. Hydrocele is abnormal collection of fluid and is commonest cause of painless scrotal swelling. Congenital type results from incomplete closure of processus vaginalis with perisistent communication between scrotal sac and peritoneum. Secondary hydrocele occur result infetion, trauma and torsion. Sonographically they appear as anechoic fluid seen surrounding anterolateral aspect of testis. Hematoceles are less common. Both hematocele and pyocele contain internal echoes and loculations.

CONCLUSIONS

This article reinforces and advances the necessary knowledge base required by radiologist to correctly identify benign intratesticular cystic lesions and differentiate them from malignant testicular lesions, with the goal being to prevent unnecessary surgical intervention. Improvements in gray-scale and Doppler US technology allow subtle distinctions between benign and malignant testicular lesions.

REFERENCES

1. Dambro TJ, Stewart RR, Barbara CA. The scrotum. In: Rumack CM, Wilson SR, Charboneau JW, eds. Diagnostic ultrasound. 2nd ed. St Louis, Mo: Mosby, 1998; 791-821.
2. Tackett RE, Ling D, Catalona WJ, Melson GE. High resolution sonography in diagnosing testicular neoplasms: clinical significance of false positive scans. J Urol 1986; 135:494-496.
3. Middleton WD, Bell MW. Analysis of intratesticular arterial anatomy with emphasis on transmediastinal arteries. Radiology 1993; 189:157-160.

4. Martinez-Berganza MT, Sarria L, Cozcolluela R, Cabada T, Escolar F, Ripa L. Cysts of the tunica albuginea: sonographic appearance. *AJR Am J Roentgenol* 1998; 170:183-185.
5. Bhatt S, Zafar S, Jafri, Wasserman N, Vikram S, Dogra. Imaging of non-neoplastic intratesticular masses. *Turkish society of Radiology* 2011; 17:52-63.
6. Hamm B, Fobbe F, Loy Y., Testicular cysts, differentiation with ultrasound and clinical findings, *Radiology* 1988;168: 19-23
7. Dambro TJ, Stewart RR, Barbara CA. The scrotum. In: Rumack CM, Wilson SR, Charboneau JW, eds. *Diagnostic ultrasound*. 2nd ed. St Louis, Mo: Mosby, 1998; 791-821.
8. Manning MA, Woodward PJ. Testicular epidermoid cyst – Sonographic features with clinicopathologic correlation. *J Ultrasound Med* 2010; 29:831-837.
9. Dogra VS, Gottlieb RH, Rubens DJ, Oka M, Di Sant Agnese AP. Testicular epidermoid cysts sonographic features with histopathologic correlation. *J Clin Ultrasound* 2001; 3:192-196
10. Bree RL, Hoang DT. Scrotal ultrasound. *Radiol Clin North Am* 1996; 34:1183-1205.
11. Das KM, Prasad K, Szmigielski W, Noorani N. Intratesticular varicocele: evaluation using conventional and Doppler sonography. *AJR Am J Roentgenol* 1999; 173:1079-1083.
12. Odrzywolski KJ, Mukhopadhyay S. Papillary cystadenoma of epididymis. *Arch Pathol Lab Med*. 2010 Apr;134(4):630-3
13. Rifkin MD, Kurtz AB, Goldberg BB. Epididymis examined by ultrasound; Correlation with pathology. *Radiology* 1984;151: 187- 90

*Corresponding author: Dr. B N Kishore kumar

Email: kishoreradiologist@gmail.com