



Contents lists available at BioMedSciDirect Publications

International Journal of Biological & Medical Research

Journal homepage: www.biomedscidirect.com



Case Report

Evaluation Of Mammography, Sonomammography In Correlation With Fine Needle Aspiration Of Breast Lumps.

Dr. Jayadeva Phurailatpam^a, Dr. Anil Sakalecha^b, Dr. CSBR Prasad^c, Dr. B.N. Kishore Kumar^d, Dr. Purnima Hegde^e

^aPost graduate, Radiodiagnosis, Sri Devaraj Urs Medical College, Kolar, Karnataka

^bAssociate professor, Radiodiagnosis, Sri Devaraj Urs Medical College, Kolar, Karnataka

^cProfessor, Pathology, Sri Devaraj Urs Medical College, Kolar, Karnataka

^dProfessor & HOD, Radiodiagnosis, Sri Devaraj Urs Medical College, Kolar, Karnataka.

^eProfessor, Radiodiagnosis, Sri Devaraj Urs Medical College, Kolar, Karnataka.

^fRI DEVARAJ URS MEDICAL COLLEGE & RESEARCH CENTRE, TAMAKA, KOLAR, KARNATAKA.

ARTICLE INFO

Keywords:

Mammography

Sonomammography

FNAC

Combined imaging modalities.

ABSTRACT

OBJECTIVES: 1. To evaluate the role of mammography and sonomammography independently and in combination and correlating with FNAC for early diagnosis of breast lesions. 2. Benign To study the characteristics of mammography and sonomammography in detecting breast lesions and differentiating from benign and malignant lesions. **METHODS:** 75 female patients attending Department of Radio diagnosis with breast lumps over a period of 18 months were assessed using mammography, sonomammography and comparing with FNAC finding. **RESULTS:** A total of 75 patients were included in the study, with age ranging from more than 30 yrs. diseases (64 %) were more common than malignant (36 %), of which fibroadenoma constituted 42.6 % of cases. The sensitivity, specificity, positive and negative predictive values of mammography is 92.3%, 91.8%, 85.7%, 95.7%; Sonomammography is 80.7%, 100%, 100%, 90.7%; Combined imaging modality is 92.3 %, 100 %, 100 % and 96.0% respectively. **CONCLUSION:** Combined imaging modalities of mammography and sonomammography play an important role in diagnosing palpable breast lesions. Its applications help:

- Better characterization of the breast lesions.
- Avoiding unnecessary investigations or surgical procedures in which imaging findings are unequivocally benign.
- Negative findings on combined mammographic and sonomammographic imaging studies have very high specificity and are reassuring to the patient.

© Copyright 2010 BioMedSciDirect Publications IJBMR -ISSN: 0976:6685. All rights reserved.

CASE REPORT

INTRODUCTION: Breast lumps are one of the common complaint / cases reported which requires early diagnosis, treatment and work up. There has been significant increase in incidence of breast cancer in India since the past few years, both in rural and urban set up. Global breast cancer incidence increased from 641,000 (95% confidence intervals 610,000 -750,000) cases in 1980 to 1,643,000 (1,421,000—1,782,000) cases in 2010, an annual increase of 3.1%. 1 Over 100,000 new breast cancer patients are estimated to be diagnosed annually in India. 2 Much concern is

given to malignancy though benign lesions of the breast are far more frequent than malignant ones. With the use of mammography, USG, MRI of the breast and needle biopsies, the diagnosis of a benign disease can be accomplished without surgery in the majority of patients. As many of the benign lesions are not associated with an increased risk for breast cancer, unnecessary surgery should be avoided.

Mammography is cost efficient and widely accepted technique to evaluate clinically suspected breast lesions and used for screening of breast cancer. 3 High resolution Sonography is a useful adjunctive modality and helps characterizing a mammographically non-detected palpable abnormality, especially in dense breast. 4

* Corresponding Author : Jayadeva Phurailatpam

jaydev.ph@gmail.com (8147355232)

Sensitivity and specificity of sonomammography or mammography is higher if USG and mammography are combined.⁵

METHODS: 75 patients with complaint of lump in the breast, attending OPD / admitted to Sri R.L. Jalappa and research centre, attached to Sri Devaraj Medical College, Kolar, during January 2012 to august 2013 were included.

A Performa drafted for the study of all patients with breast complaints, like lumps.

Exclusion criteria:

1. Women below 30 years of age.
2. Women with advanced malignancy, fungating mass per breast and fixed lumps to the chest wall where performing mammography will be difficult.
3. Pregnant women
4. Male patients.

Mammography were performed with GE ZMX70-M. Both cranio-caudal and medio-lateral views are taken and the image was assessed and scored using the BIRADS.

Sonomammographic examination was performed with SEIMENS G 40 and SEIMENS G 50 with 5-10 Mhz linear transducer. Both the breast were scan radially and by grid scanning technique.

FNAC were performed under ultrasound guidance in the most suspicious lesions and at least two sites were taken. FNAC done with Giemsa stain, Papanicolaou stain and H & E stain. Core biopsy will be done when FNAC is inconclusive. Imaging studies were done for patients before FNAC. The results were analyzed and categorized according to BIRADS (Breast Imaging Reporting and Data System) score.

RESULTS:

The patients presenting with complaints of lump in the breast and who expressed consent for the study were involved and investigations were done as outlined in method of study.

75 patients entered the study and all patients were subjected to all investigations.

The results of the study are shown in the following tables.

The sensitivity, specificity, positive and negative predictive values of each investigation was calculated individually.

TABLE 1: Age distribution of breast lesions

Age groups (in years)	No. of cases	Percentage
30-39	16	21.3
40-49	29	38.6
50-59	17	22.6
>60	13	17.3
Total	75	100

TABLE 2: Distribution of breast lesions according to the side of involved breast

Side	No. of cases	Percentage
Right	30	40
Left	33	44
Bilateral	12	16

Table 3: Distribution of breast lesions according to quadrant involved

Quadrant involved	No. of cases	Percentage
Upper outer (UO)	23	30.6
Upper inner (UI)	09	12.0
Lower outer (LO)	06	8.0
Lower inner (LI)	05	6.6
Central (C)	11	14.6
> One quadrant (>1)	21	28.0
Total	75	100

TABLE 4: Distribution of cases diagnosed by mammography

Mammographic diagnosis (BIRADS)	No. of cases	Percentage
0	06	8
1	-	-
2	42	56.0
3	03	4.1
4	20	26.6
5	04	5.3
Total	75	100

TABLE 5: Distribution of benign and malignant cases on mammography

Lesions	No. of cases	Percentage
Benign	45	60
Malignant	24	32
Inconclusive	06	08
	75	100

TABLE 6: Distribution of benign and malignant cases according sonomammography

USG BIRADS	No. of cases	Percentage
0	-	-
1	-	-
2	49	65.3
3	05	6.6
4	19	25.3
5	02	2.6
	75	100

TABLE 7: Distribution of benign and malignant cases in sonomammography

Lesions	No. of cases	Percentage
Benign	54	72
Malignant	21	28
Inconclusive	-	-
Total	75	100

TABLE 8: Distribution of benign and malignant cases in FNAC

Lesions	No. of cases	Percentage
Benign	49	65.5
Malignant	26	34.6
Total	75	100

TABLE 9: Distribution of cases diagnosed by combined mammography and sonomammography

BIRADS	No. of cases	Percentage
0	-	-
1	-	-
2	47	62.6
3	04	5.3
4	20	26.7
5	04	5.3
	75	100

TABLE 10: Distribution of benign and malignant cases in combined mammography and sonomammography

Lesions	No. of cases	Percentage
Benign	51	68
Malignant	24	32
		100

TABLE 11: Distribution of cases diagnosed by diagnostic modalities compared with FNAC

Investigation	Benign	Malignant	Incon.	Total
Mammography	45	24	06	75
Sonomammography	54	21	-	75
FNAC	49	26	-	75
Combined imaging modalities	51	24	-	75

TABLE 12: Comparison of mammographic diagnosis with FNAC

Mammography Diagnosis	FNAC diagnosis		Total
	Malignant	Benign	
Malignant	24	04	28
Benign	02	45	47
	26	49	75

Sensitivity - 92.3%
 Specificity - 91.8%
 Positive predictive value - 85.7%
 Negative predictive value - 95.7%

TABLE 13: Comparison of sonomammography diagnosis with FNAC

Sonomammography Diagnosis	FNAC diagnosis		Total
	Malignant	Benign	
Malignant	21	0	21
Benign	05	49	54
	26	49	75

Sensitivity - 80.1 %
 Specificity - 100%
 Positive predictive value - 100%
 Negative predictive value - 90.7 %

TABLE 14: Comparison of diagnosis by combined imaging modalities with FNAC

Combined Diagnosis	FNAC diagnosis		Total
	Malignant	Benign	
Malignant	24	-	24
Benign	02	49	51
	26	49	75

Sensitivity - 92.3 %
 Specificity - 100 %
 Positive predictive value - 100%
 Negative predictive value - 96.0%

TABLE 15: Distribution of cases based on FNAC

FNAC diagnosis	No. of cases	Percentage
Fibroadenoma	32	42.6
Phyllodes	01	1.3
Fibrocystic disease	14	18.6
Carcinoma	26	34.6
Abscess	02	2.6

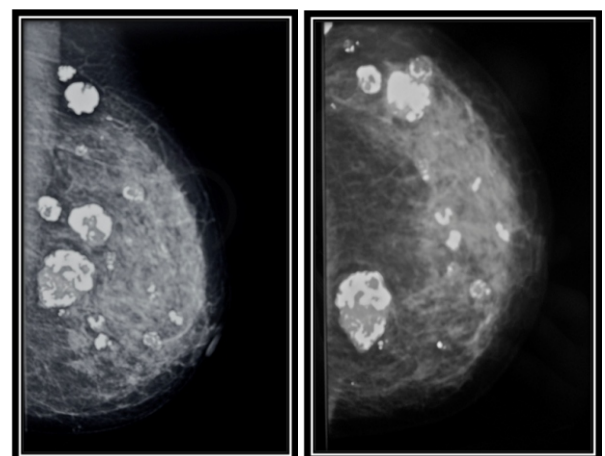
Fig No. 13: Medio-lateral oblique and cranio-caudal views showing multiple well defined lesions with popcorn calcifications - Involuting fibroadenoma

Fig No. 14: Mammographic image of a dense breast

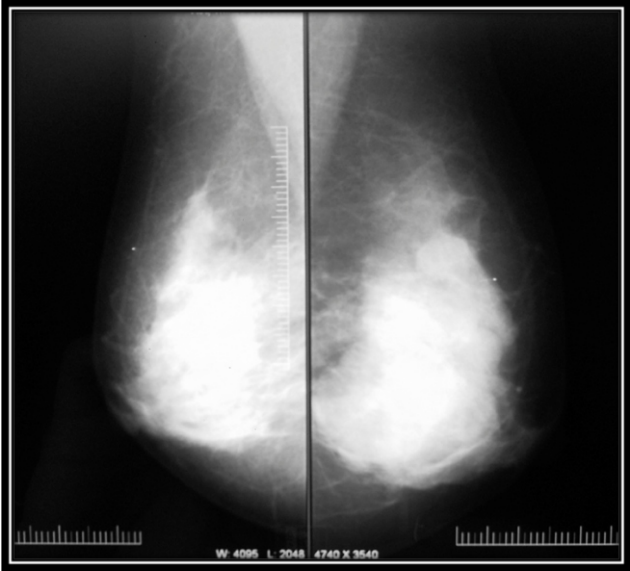


Fig No. 15: USG image of a cyst not seen on mammographically dense breast with FNAC Showing sheets of apocrine cells

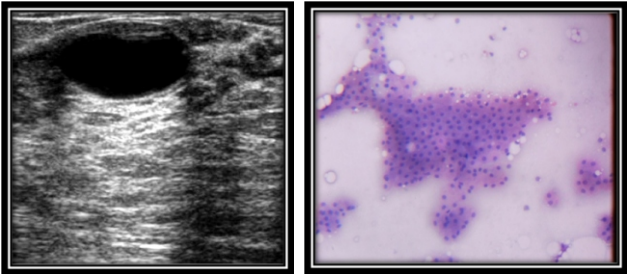


Fig No.16 :Mammographic image showing spiculated lesion which is consistent with carcinoma breast

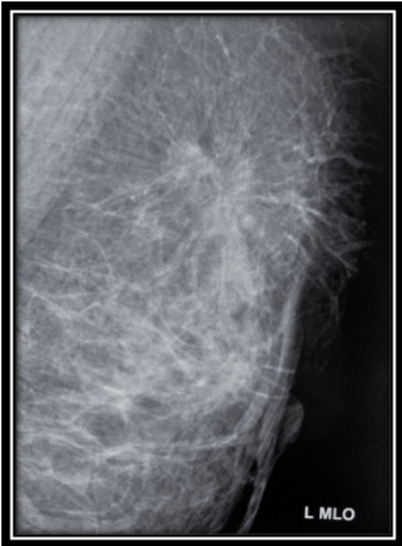

Fig No.17: USG image of malignant lesion of breast with FNAC showing anisokaryosis, irregular nuclear membrane and high n/c ratio

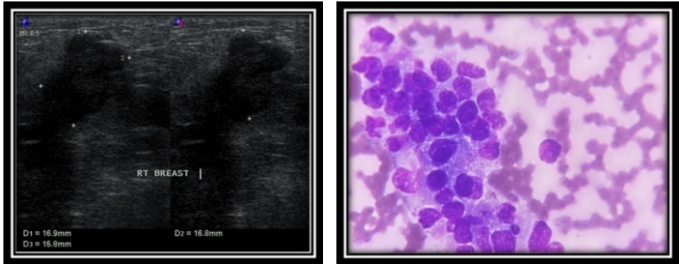


Fig No. 18: Cranio-caudal view of left breast showing bilobed mass lesion – BIRADS 5.

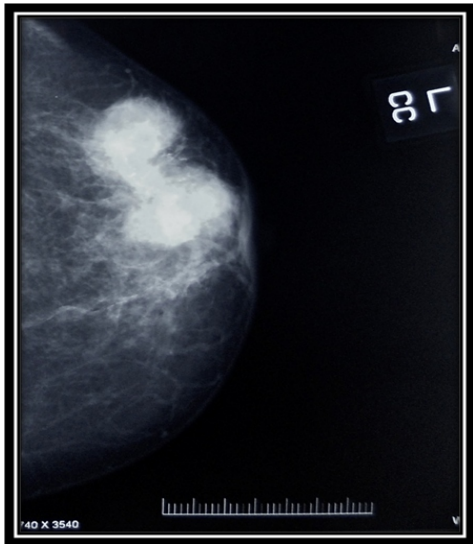
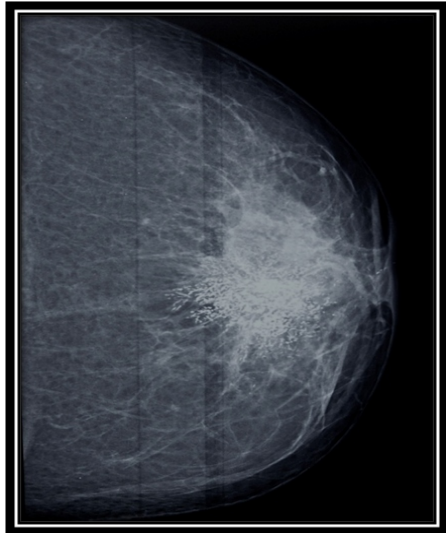

Fig No. 19: Cranio-caudal view showing ill-defined dense lesion with Microcalcifications – carcinoma breast.



DISCUSSION:

Breast carcinoma has been reported in only 4% of patients with breast symptoms, and even among palpable lesions undergoing biopsy, a large number of lesions turned out to be benign.^{6,7} The role of mammography in patients with palpable breast lumps is to rule out malignancy for any palpable abnormality and to avoid further intervention. It helps in earlier intervention for a mass with malignant features along with screening for additional lesions in the ipsilateral and contralateral breast. It is also useful in assessing the extent of malignancy when cancer is diagnosed.⁸ Mammography is the only screening modality, which has been proven to reduce mortality from breast cancer through early detection.⁹

Sensitivity of mammography in detection of breast cancers in the screening set up ranges from 83 to 95 percent.¹⁰ However the false negative rate of mammography for breast cancer in patients with palpable abnormalities of the breasts has been reported to be as high as 16.5%.¹¹ Mammographic sensitivity for breast cancer declines significantly with increasing breast density and is independently higher in older women with dense breasts.¹² It decreases to as low as 30 to 48 percent in patients with radiographically dense and glandular breasts.¹³

Multiple studies have shown that the false negative rate for a combined mammographic and sonographic evaluation varies from 0% to 2.6%.^{14,15,16}

In this study, 75 patients with age ranging from 30 years to maximum of 72 years are seen with median age of 47 years, presented with breast lesions and these patients were evaluated using mammography and sonomammography.

The results from each investigation were compared with - fine needle aspiration report.

Investigations	Sensitivity	Specificity	Positive predictive value	Negative predictive value
Mammography	92.3	91.8	85.7	95.7
USG	80.7	100	100	90.7
Combined imaging	92.3	100	100	96.0

Table: Comparison of Sonomammography results with other Studies

Study	Ashley et al (21)	Ghazala et al (22)	Present study
Sensitivity	65%	67%	80.7%
Specificity	95%	92.4%	100%

In a study done by Philip J Drew et al²¹ to compare the sensitivity and specificity of the traditional triple assessment of symptomatic breast lesions with contrast-enhanced dynamic magnetic resonance imaging, they found the sensitivity of mammography 87.6%, and specificity of 86.5%. The results of this study were similar to the results of the present study.

Al-Muhim et al,²⁰ in a study to assess accuracy of the "triple test" in the diagnosis of palpable breast masses in Saudi females, found that Mammography showed 87.5% sensitivity, 97.3% specificity and 87.5% positive predictive value. They concluded that the triple test was 100% accurate in the diagnosis of palpable breast lesions when all three elements were concordant.

Combined imaging evaluation leads to fewer unnecessary biopsies. Perdue et al²³ reported that only 11.1% of 623 excisional biopsy specimens of palpable breast revealed carcinoma. In this study only 7 of the 50 palpable abnormalities underwent biopsy on the basis of imaging findings and only 2 (4%) showed malignancy.

The value of combined mammographic and sonographic imaging in symptomatic patients has been studied previously.

Moss et al reported sensitivity of 94.2% and specificity of 67.9% in 368 patients.¹⁷

Shetty MK and Shah YP reported a sensitivity of 100% and specificity of 80.1%.²⁵ Barlow et al reported a sensitivity of 87% and specificity of 88% and positive predictive value of 22%.²⁶

When a patient presents with a lump in breast, combined imaging studies can distinguish benign from malignant lesions.^{27,28}

Inclusion of sonomammography to mammographic studies adds up to the diagnosis in patients with breast lesions.

CONCLUSION: Benign neoplasms of the breast are more common than malignant ones. Commonest age group for breast lesions ranges from 40-49 years. Upper outer quadrant of breast is the most common site for breast lesions. Combined imaging modalities of mammography and sonomammography play an important role in diagnosing palpable breast lesions. It helps in:

- a) Better characterization of the breast lesions.
- b) Avoiding unnecessary investigations or surgical procedures in which imaging findings are unequivocally benign.
- c) Negative findings on combined mammographic and sonomammographic imaging studies have very high specificity and are reassuring to the patient.

Bibliography

1. Mohammad H, Kyle J, Allyne M, Rafael L. Breast cancer and cervical cancer in 187 countries between 1980 and 2010: a systemic analysis. *The Lancet* 2011; 8:193-341.
2. National cancer registry programme consolidated report of the population based cancer registries 1990-1996. Indian Council of Medical Research 2001.
3. Barton MB, Elmore JG, Fletcher SW. Breast symptoms among women enrolled in a health maintenance organization: frequency, evaluation, and outcome. *Ann Intern Med* 1999;130: 651-679.
4. Donegan WL. Evaluation of a palpable breast mass. *N Engl J Med* 1992;327:937-942
5. Sabine M, Susanne W and Achim S. Comparison of written reports of mammography, sonography and magnetic resonance mammography for preoperative evaluation of breast lesions, with special emphasis on magnetic resonance mammography. *Breast cancer res* 2001; 3(1) 55-80.
6. Perdue P, Page D, Nellestein M, Salem C, Galbo C, Ghosh B. Early detection of breast carcinoma: a comparison of palpable and non-palpable lesions. *Surgery* 1992; 111:656-659.
7. Kopans DB. Palpable abnormalities and breast imaging. In: *Breast Imaging*. 2nd ed. Philadelphia PA: Lippincott Williams & Wilkins 1998; 747-759.
8. Coveney EC, Geraghty JG, O'Laoide R, Hourihane IB, O'Higgins NJ. Reasons underlying negative mammography in patients with palpable breast cancer. *Clin Radiol* 1994; 49:123-125.
9. Tabar L, Vitak B, Chen TH, et al. Swedish two country trial: impact of mammographic screening on breast cancer mortality during 3 decades. *Radiology* 2011; 260(3): 653-63.
10. Mushlin al, Kouides RW, Shapiro DE. Estimating the accuracy of screening mammography: a meta-analysis. *Am J Prev Med* 1998;14:143-53.
11. Kolb TM, Lichy J, Newhouse JH. Comparison of the performance of screening mammography, physical examination, and breast US and evaluation of factors that influence them: an analysis of 27,825 patient evaluations. *Radiology* 2002; 225(1):165-75.
12. Dennis MA, Parker SH, Klaus AJ, Stavros AT, et al. Breast biopsy avoidance: the value of normal mammograms and sonograms in the setting of a palpable lump. *Radiology* 2001; 219:186-191.
13. Boyd NF, Guo H, Martin LJ, et al. Mammographic density and risk and detection of breast cancer. *N Engl J Med* 2007; 356:227-36.
14. Weinstein Sp, Conant EF, Orel SG, Zuckerman JA, Czerwiecki B, Lawton TJ. Retrospective review of palpable breast lesion: negative mammography and sonography. *J Women Imaging* 2000; 2:15-18.
15. Soo MS, Rosen EI, Baker JA, Vo TT, Boyd BA. Negative predictive value of Sonography with mammography in patients with palpable breast lesions. *AJR Am J Roentgenol* 2001; 177:1167-1170.
16. Moy L, Slantez PJ, Moore R, et al. Specificity of mammography and US in the evaluation of a palpable abnormality. *Radiology* 2002; 225:176-181.
17. Moss HA, Britton PD, Flower CDR, et al. How reliable is modern breast imaging in differentiating benign from malignant breast lesions in the symptomatic population? *Clin Radiol* 1999; 54:676-682.
18. Georgian D, Taylor KJW, Maadjar H, et al. Sonography of palpable breast cancer. *J Clin Ultrasound* 2000; 28:211-216
19. Al-Mulhim AS, Sultan M, Al-Mulhim FM, et al. Accuracy of the triple test in then diagnosis of palpable breast masses in Saudi females. *Ann Saudi Med* 2003;23(3-4):158-61
20. Philip J, Lindsay W, Sumohan C, John, et al. Prospective Comparison of Standard Triple Assessment and Dynamic Magnetic Resonance Imaging of the Breast for the Evaluation of Symptomatic Breast Lesions. *Annals of Surgery* 1999; 230(5):680-5
21. Ashley S, Royale JT, Rubin CM; Clinical, radiological and cytological diagnosis of breast cancer in young women. *Br J Surg* 1989;76(8):835-7.
22. Ghazala M, Fareesa W, Ghulam Q; Sonomammography for evaluation of solid breast masses in young patients. *J Ayub med coll* 2006;18(2):34-6
23. Perdue P, Page D, Nellestein M, et al. Early detection of breast carcinoma: a comparison of palpable and non-palpable lesions. *Surgery* 1992; 111:656-659.
24. Moss HA, Britton PD, Flower CDR, et al. How reliable is modern breast imaging in differentiating benign from malignant breast lesions in the symptomatic population? *Clin Radiol* 1999; 54:676-682.
25. Shetty MK, Shah YP, Sharman RS. Prospective evaluation of value of combined mammographic and sonographic assessment in patients with palpable abnormalities of breast. *J Ultrasound Med* 2003;22: 263-268.
26. Barlow WE, Lehman CD, Zheng Y, et al. Performance of diagnostic mammography for
27. Bassett LW, Ysreal M, Gold RH. Usefulness of mammography and Sonography in women less than 35 years of age. *Radiology* 1991; 180:831-5.
28. Yang Wei, Dempsey PJ. Diagnostic breast ultrasound. *Radiol Clin North Am* 2007; 45(5): 845-62.