

Case Report

Open Access

A Case Report of Bilateral Tuberculosis of Breast

Sreeramulu PN¹, Venkatachalapathy TS^{1*} and Prathima S²

¹Department of Surgery, Sri Devaraj URS Medical College and RI Jalappa Hospital and Research Centre, Tamaka, Kolar, Karnataka, India

²Department of Pathology, Sri Devaraj URS Medical College and RI Jalappa Hospital and Research Centre, Tamaka, Kolar, Karnataka, India

Abstract

Tuberculosis of the breast is an extremely rare form of extra-pulmonary tuberculosis. Bilateral involvement is even rarer. We report a case of secondary bilateral breast tuberculosis in a young female, who responded to first line anti-tuberculosis drugs.

Keywords: Bilateral breast TB; Sinus breast; Antitubercular therapy

Introduction

Tuberculosis involvement of the breasts was first described by Sir Astley Cooper in 1829. The incidence of breast tuberculosis, among all breast lesions, has been computed by various authors as between 0.54%-1.87% [1,2]. It more often involves married women, and those who have borne children. Haematogenous infection appears to be the most plausible of all the routes of infection. The diagnosis is difficult because of nonspecific clinical and radiologic findings. The diagnosis is hampered by the identical signs and symptoms for breast carcinoma or breast abscess. We present a case of bilateral breast tuberculosis with bilateral breast lumps having suspicion of malignancy [3].

Case Report

We report a 32 years old lady with lumps in both side of breast, on the right side there was sinus in the breast connecting the lump. No history of pain, fever but she gave history of loss of weight and loss of appetite. She did not have family history or exposure to tuberculosis. On examination lumps in both breasts were firm in consistency, non tender and all the borders were well made out. Lumps move along with breast tissue, skin over the swelling was normal and pinchable. She has no other system involvement by tuberculosis. FNAC revealed granulomatous mastitis. Trucut biopsy yielded tubercular mastitis, mammography revealed distorted borders, speckled calcification (differential diagnosis of malignancy). Patient was started empirically on antitubercular therapy depending on the trucut report for which the patient responded to therapy and both lumps disappeared (Figures 1-3).

Discussion

It is possible that this condition may have been overlooked in India. High resistance offered by the breast tissue to the survival and multiplication of *tubercle bacilli* has been postulated to be the cause of the rarity of breast tuberculosis. Breast tuberculosis is more common in females since they undergo frequent hormonal changes during their reproductive life and are more susceptible to trauma and infections [4], although very rarely, tuberculosis of male breast has also been reported. In reproductive and lactating women the prevalence of *tubercle bacilli* in faucial tonsils of fed infants could be the cause of primary tuberculosis. In one study, 29 out of 38 breast tuberculosis cases were in the 21 to 40 years age group and the remaining 9 in the 41 to 70 years age group [5]. The extremely rare primary bilateral or unilateral breast tuberculosis is thought to occur due to direct inoculation through skin abrasions or duct openings in the nipple [6].

Secondary involvement of breast by haematogenous or lymphatic route is much more common; lymphatic spread by retrograde extension from axillary lymph nodes (rarely cervical and mediastinal) is

considered to be the most common mode of spread. Rarely, contiguous spread from the ribs and pleural space can occur. Diagnosis is ideally by bacteriological confirmation from the breast tissue by Ziehl-Neelsen stain or culture. However, the bacilli are isolated in only 25% of cases; therefore demonstration of caseating granulomas from the breast tissue and involved lymph nodes is usually sufficient for the diagnosis. Bilateral breast TB has been reported in 30%, multifocal TB with breast involvement is reported in 10% of cases.

Radiological imaging modalities like mammography or ultrasonography are unreliable in distinguishing it from carcinoma [7,8] because of the variable pattern of presentation of such an inflammatory lesion. The number of cases of PNHL (Primary Non Hodgkin's Lymphoma) of the breast reported to date is around 250.

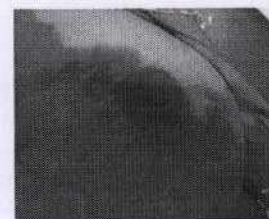

Figure 1: Sinus and ulcer over breast.

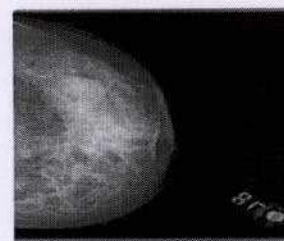

Figure 2: Mammography of left breast.

*Corresponding author: Venkatachalapathy TS, Assistant Professor of Surgery, Sri Devaraj URS Medical College and RI Jalappa Hospital and Research Centre, Tamaka, Kolar, Karnataka, India, E-mail: drvenkey@hotmail.com

Received September 29, 2012; Accepted November 07, 2012; Published November 09, 2012

Citation: Sreeramulu PN, Venkatachalapathy TS, Prathima S (2012) A Case Report of Bilateral Tuberculosis of Breast. J Clin Case Rep 2:222. doi:10.4172/2165-7920.1000222

Copyright: © 2012 Sreeramulu PN, et al. This is an open-access article distributed under the terms of the Creative Commons Attribution License, which permits unrestricted use, distribution, and reproduction in any medium, provided the original author and source are credited.




Figure 3: Granulomas circled in ducts and lobules.

Most of these cases have involved the right breast, and almost all the patients were females. Non Hodgkin's Lymphomas of the breast typically present as unilateral mass; the frequency of bilateral disease at first presentation ranges from 5-25%.

Clinical presentation may be as a lump, an abscess or as single or multiple discharging sinuses with bluish undermined edges. Previous reports have suggested that active or healed tuberculosis in other parts of body may be present in 25-84% of patients with breast tuberculosis [4,9-16]. Tuberculosis of the breast is rarely diagnosed by clinical methods alone but merits attention because it is of surgical importance as a lump in the breast which may be mistaken for carcinoma.

Fine Needle Aspiration and Cytology (FNAC) establish the diagnosis in most cases. Khanna et al. [17] reported a success rate of 100% in his series while Kakkar et al. [18] reported a success rate of 73%. Tse et al. [19] has emphasized the presence of Epithelioid histocytes as the single most common indicator of granulomatous inflammation [12,17-23], in the absence of Granulomas, which were absent in half the cases reviewed by them. Treatment is by institution of antituberculous therapy using standard regimes. Surgical intervention may be required for patients with abscess, sinuses or a need to exclude malignancy in a patient with high index of suspicion.

Conclusion

Bilateral breast tuberculosis is a rare entity, needs high index of suspicion which has good prognosis. In our case managed conservatively and healed with complete recovery.

References

- Cooper A (1829) Illustrations of the diseases of the breast: Part I. London: Longman, Rees Orme, Brown and Green 73.
- Kedar GP, Bophate SK, Kherdekar M (1985) Tuberculosis of the breast. Ind J Tub 32: 146.
- Madhusudhan KS, Gamanagatti S (2008) Primary breast tuberculosis masquerading as carcinoma. Singapore Med J 49: 3-5.
- Singh A, Gupta SK, Mirdehghani SA, Nagpal BL (1980) Tuberculosis of the breast. Ind J Surgery 42: 432.
- Mukherjee P, George M, Maheshwari HB, Rao CP (1974) Tuberculosis of the breast. J Indian Med Assoc 62: 411.
- Banerjee SN, Ananthakrishnan MS, Prakash S (1987) Tuberculosis mastitis- a continuing problem. World J Surg, 11: 105.
- Ducroz B, Nael LM, Gautier G, Montreal JM, Marquet M, et al. Bilateral breast tuberculosis: a case report. J Gynaecol Obstet Biol Reprod (Paris) 21: 484.
- Navani NK, Bhagwat SS, Chaphekar AP, Pinto AC, Sheth, SV (1991) Bilateral breast tuberculosis-an unusual presentation. Bombay Hospital Journal 41: 34(S).
- Forrest DM, Parkes R (1995) Mammary tuberculosis; critical discussion with an illustrative case. Postgrad Med J 31: 172-179.
- Sharma PK, Babel AL, Yadav SS (1991) Tuberculosis of breast (Study of 7 cases). J Postgrad Med 37: 24-26.
- Wilson JP, Chapman SW (1990) Tuberculous mastitis. Chest 98: 1505-1509.
- Prem Parkash Gupta, Gupta KB (2003) Tuberculous Mastitis: A review of seven consecutive cases. Ind J Tub 50: 47.
- McKeown KC, Wilkinson KW (1952) Tuberculosis of the breast. Br J Surg 39: 420-429.
- Shinde SR, Chandawarkar RY, Deshmukh SP (1995) Tuberculosis of the breast masquerading as carcinoma: a study of 100 patients. World J Surg 19: 379-381.
- Gupta D, Rajwanshi A, Gupta SK (1999) Fine needle aspiration cytology in the diagnosis of tuberculosis mastitis. Acta Cytol 43: 191-194.
- Raw N (1924) Tuberculosis of the breast. Br Med J 1: 657.
- Khanna R, Prasanna GV, Gupta P (2002) Mammary Tuberculosis Report on 52 Cases. Postgrad Med J 78: 422-424.
- Kakkar S, Kapila K, Singh MK, Verma K (2000) Tuberculosis of the breast. A cytomorphologic study. Acta Cytol 44: 292-296.
- Tse GM, Poon CS, Law BK, Pang LM, Chu WC, et al. (2003) Fine needle aspiration Cytology of granulomatous Mastitis. J Clin Pathol 56: 519-521.
- Morgen M (1931) Tuberculosis of the breast. Surgery, Gynaecology and Obstetrics 53: 593.
- Sakr AA, Fawzy RK, Fadaly G, Baky MA (2004) Mammographic and sonographic features of tuberculous mastitis. Eur J Radiol 51: 54-60.
- Sriram KB, Moffatt D, Stapledon R (2008) Tuberculosis infection of the breast mistaken for granulomatous mastitis: A case report. Cases J 1: 273.
- Anand A, Bhosale, Avinash R, Joshi, Amrut V, Ashturkar, Gayatri S, Pathak (2012) Primary tuberculosis of breast: A case series 5: 262-264.

Submit your next manuscript and get advantages of OMICS Group submissions

Unique features:

- User friendly/feasible website-translation of your paper to 50 world's leading languages
- Audio Version of published paper
- Digital articles to share and explore

Special features:

- 200 Open Access Journals
- 15,000 editorial team
- 21 days rapid review process
- Quality and quick editorial, review and publication processing
- Indexing at PubMed (partial), Scopus, DOAJ, EBSCO, Index Copernicus and Google Scholar etc
- Sharing Option: Social Networking Enabled
- Authors, Reviewers and Editors rewarded with online Scientific Credits
- Better discount for your subsequent articles

Submit your manuscript at: <http://www.omicsonline.org/submission>