



Epididymal Sparing Bilateral Orchidectomy with Epididymoplasty for Advanced Cancer Prostate: Our Experience in Rural Setup

Vijay P Agrawal*, TK Sen and Krishna Shetty MV

Department of Urology, Sri Devraj Urs Medical College, Tamaka, Kolar, Karnataka, India

Abstract

Rise in incidence and variable natural history of prostatic carcinoma, presents a challenge to professionals involved in its management. Cases that come for evaluation and treatment in developing countries like ours are elderly and usually present in the late stages of the disease. Perhaps the best option remain at this stage is palliative in the form of channel TURP to improve the urine flow and suppress the cancer growth by androgen deprivation treatment (ADT). Further improvement of quality of life is achieved by supportive measures like good nutrition, vitamins and calcium supplementation to prevent demineralisation of bones and analgesic for pain relief.

Bilateral Orchidectomy remains the most effective and permanent solution for ADT as it brings down serum testosterone level very rapidly to castration level of 20%. Epididymis functions only as the carrier of sperms and help in maturation during the passage. In no way it is involved in spermatogenesis or production of testosterone.

Epididymal sparing bilateral orchidectomy with epididymoplasty achieves androgen deprivation to that of castration level. Left over epididymal bobbins in the scrotal sacs maintains the shape of scrotum and gives the patient a feel of scrotal sac not being empty.

Keywords: Cancer prostate; Orchidectomy; Epididymal sparing bilateral orchidectomy; Epididymoplasty; Body image

Introduction

Prostate cancer is predominantly a disease of aging population. Improvement in socioeconomic condition and availability of better health care facilities has lead to increase in longevity and a larger number of aging populations with rise in incidence of prostate cancer. To further add to the problem, is the variable nature and clinical presentation of the disease which leads to a formidable challenge to all the professionals involved in its management [1,2].

The clinical and scientific understanding of the disease process is ever improving leading to a rapid change in its management options. Standard treatment option of yesteryears does not hold good today and what is prevalent now may change in the days to come.

Early stage of the disease (localised prostate cancer) is very difficult to pick up due to silent nature of its clinical presentation. Most of the cases detected in developing countries like ours are in late stages where the patient present with bladder outlet obstruction, bone pains, or pathological fractures, chronic ill health, weight loss or severe anemia.

Localised prostate cancer

Though the detection of early prostate cancer is increasing in recent years due to easy availability of prostate specific antigen (PSA) estimation [3], the treatment option recommended is widely variable. No unanimity has achieved to stress the superiority of one mode of treatment over the other.

The options are:

- 1 Surgery – Radical nerve sparing prostatectomy
- 2 Radiotherapy – Radical distant beam radiotherapy or brachytherapy
- 3 Expectant management – Active monitoring for the progress of the disease. Since the tumour is slow growing, in many cases one may not need any form of treatment in their life span.

To add to this dilemma approximately one third of the patients treated for localise prostate cancer by radical surgery or radiotherapy eventually relapse, indicated by rise in PSA.

Advanced prostate cancer

Androgen deprivation therapy (ADT) remains the mainstay of advanced prostate cancer. At the onset prostate cancer cells are regulated by androgens, typically called hormone sensitive prostate cancer. In this state, the majority of patient will responds to ADT. However some of them subsequently progress to androgen independent disease state. Typically manifested by relapsing of symptoms or rise in PSA (after a median duration of 18 to 24 months). These androgens independent cancers remains susceptible to further secondary hormone manipulation for a further limited period of time by adding anti-androgens (bicalutamide, flutamide or cyproterone) or female hormone (estrogen and stilbestrol) with its added risk of side effects. Eventually they further progresses to hormone refractory prostate cancer (HRPC) state.

For HRPC, chemotherapy is in the form of taxanes (paclitaxel and docetaxel). Mitoxantrone remains the mainstay of management. Palliative and symptomatic treatment of bone pains due to secondaries or androgen deprived osteoporosis may require local radiation, steroids or biphosphate along with other supportive treatment like calcium, analgesics, good nutritious diet with iron and vitamin supplementation. Targeted chemotherapy with radio pharmaceutical

*Corresponding author: Dr. Vijay P Agrawal, Department of Surgery, Sri Devraj Urs Medical College, Tamaka, Kolar, Karnataka, India, E-mail: vijugunnu@gmail.com

Received October 15, 2012; Accepted October 18, 2012; Published October 22, 2012

Citation: Agrawal VP, Sen TK, Krishna Shetty MV (2012) Epididymal Sparing Bilateral Orchidectomy with Epididymoplasty for Advanced Cancer Prostate: Our Experience in Rural Setup. Med Surg Urol 1:106. doi:10.4172/2168-9857.1000106

Copyright: © 2012 Agrawal VP, et al. This is an open-access article distributed under the terms of the Creative Commons Attribution License, which permits unrestricted use, distribution, and reproduction in any medium, provided the original author and source are credited.

agents like strontium⁸⁹ or phosphorous³² is costly and not easily available for mass population and rural setups.

Androgen deprivation

Androgen deprivation can be achieved by bilateral orchidectomy, medical orchidectomy (by LHRH analogues) and by anti-androgen therapy. Achieving medical orchidectomy by luteinizing hormone releasing hormone analogue like Leuprolide or Goserelin every monthly, 3 monthly or 6 monthly injectables dosage schedules can achieve androgen reduction to that of surgical castration level [4-6]. The cost of injection comes to around Rs. 5-7 thousands for 3 monthly doses and Rs. 8-11 thousand for 6 monthly dose schedules (for each injection). Besides this, there is an androgen flare at the beginning of the treatment which needs to be counteracted by giving anti-androgen.

Antiandrogen like Bicalutamide, flutamide or nilutamide has to be given at high doses to suppress androgen level to that of castration level with its antecedent intolerable side effects like nausea, vomiting, GI upset and liver toxicity.

Bilateral orchidectomy

Bilateral orchidectomy is the simple and most effective way to achieve permanent androgen deprivation [4,6,7]. It can be performed by any one of the following procedures:

1. Simple total scrotal orchidectomy;
2. Subcapsular orchidectomy [8];
3. Epididymal sparing orchidectomy with epididymoplasty [9,10].

In simple total scrotal orchidectomy, the spermatic cord is double ligated with non absorbable sutures after splitting the cord in two or three segments. The drawback is the empty scrotal sacs which may not be well appreciated by all. On sporadic incidence there may develop granuloma and a sinus arising from the silk sutures of the transected cord.

In subcapsular orchidectomy the tunica albuginea of testis is incised and the seminiferous tubules are scooped out. The advantage is the retained tunica may give a false feeling of testis in the scrotal sac. The disadvantage of the procedure is that the functional orchidectomy may not be complete if some of the seminiferous tubules are left behind. The dead space inside the tunical sac may form a hematoma and if it gets infected may form an abscess. It was seen in one odd case.

Materials and Methods

Epididymal sparing orchidectomy and epididymoplasty

Clinically suspected cancer prostate and/or elevated PSA presenting with LUTS are subjected to channel TURP and initial specimen sent for frozen section biopsy. On confirmation of cancer prostate, bilateral orchidectomy is done at the end of TURP. In cases of negative or equivocal biopsy report the procedure is differed till confirmation of paraffin section histopathology report.

The testis is exposed by midline scrotal incision over median raphe. Epididymis is stretched away from the testicular surface and dissected off with cutting cautery and sharp scissor dissection. After removal of the testis, intact tunica albuginea cover the long axis of the epididymis in folded in "U" shaped manner and sutured together with 3.0 vicryl mattress sutures to achieve perfect hemostasis. The bubbin shaped folded epididymis is replaced back in the scrotal sac. The procedure is repeated on the other side through the same incision. Scrotal skin is

closed with 3.0 catgut suture without drain and patient is discharged after 2-3 days after catheter removal. When the procedure is done for previously diagnosed cancer prostate, it is preferred to do the operation under local anaesthesia.

The procedure was simple to learn and easily picked up by the postgraduate students (Figures 1-6).

Results

Lately the procedure is adopted in all cases needing ADT for ca prostate. The 15 cases done so far did not have any complication and serum testosterone level achieved to that of castration level. Well maintained scrotal shape and form and the epididymal bubbins felt




Figure 1: Commencing epididymal sparing orchidectomy.

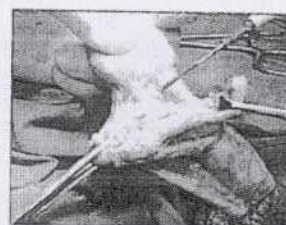

Figure 2: Epididymis is stretched away from the testicular surface and dissected off with cutting cautery and sharp scissor dissection.

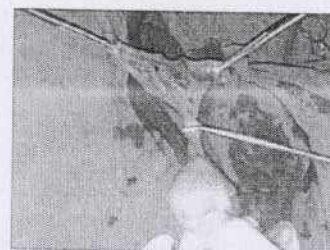


Figure 3: Separation of testis from epididymis.

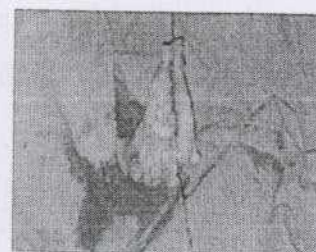


Figure 4: Epididymis in folded in "U" shaped manner and sutured together to form bubbin shaped folded epididymis.

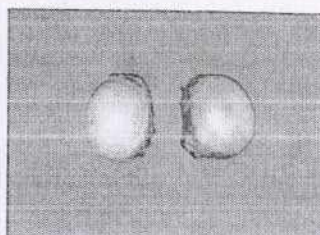


Figure 5: Post operative specimen of testis after epididymal sparing orchidectomy.

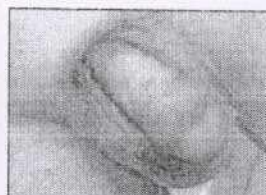

Figure 6: Well maintained scrotal shape and form after epididymal sparing orchidectomy.

inside, apparently made the patient look quite happy, relaxed and satisfied.

Conclusion

Epididymal sparing bilateral orchidectomy with epididymoplasty achieves androgen deprivation to that of castration level and maintains

the shape of scrotum with feeling of the epididymal bobbins as testicles. The procedure is safe and simple and is easy to learn, though the time taken to perform the procedure is little longer than conventional orchidectomy.

References

1. Adolfsson J, Carstensen J, Löwhagen T (1992) Deferred treatment in clinically localised prostatic carcinoma. Br J Urol 69: 183-187.
2. Johansson JE, Adami HO, Andersson SO, Bergström R, Holmberg L, et al. (1992) High 10-year survival rate in patients with early, untreated prostatic cancer. JAMA 267: 2191-2195.
3. Cooperberg MR, Park S, Carroll PR (2004) Prostate cancer 2004: insights from national disease registries. Oncology (Williston Park) 18: 1239-1247.
4. Bayoumi AM, Brown AD, Garber AM (2000) Cost-effectiveness of androgen suppression therapies in advanced prostate cancer. J Natl Cancer Inst 92: 1731-1739.
5. Landis SH, Murray T, Bolden S, Wingo PA. (2008) Cancer statistics 1998. Ca: A Cancer Journal for Clinicians 48:6-29.
6. Mariani AJ, Glover M, Arita S (2001) Medical versus surgical androgen suppression therapy for prostate cancer: a 10-year longitudinal cost study. J Urol 165: 104-107.
7. Chon JK, Jacobs SC, Naslund MJ (2000) The cost value of medical versus surgical hormonal therapy for metastatic prostate cancer. J Urol 164: 735-737.
8. Riba LW. Subcapsular castration for carcinoma of prostate. J Urol. 1942;48: 384-387.
9. Issa MM, Lendvay TS, Bouet R, Young MR, Petros JA, et al. (2005) Epididymal sparing bilateral simple orchidectomy with epididymoplasty: preservation of esthetics and body image. J Urol 174: 893-897.
10. Glenn JF (1990) Subepididymal orchidectomy: the acceptable alternative. J Urol 144: 942-944.

Submit your next manuscript and get advantages of OMICS Group submissions

Unique features:

- User friendly/feasible website-translation of your paper to 50 world's leading languages
- Audio Version of published paper
- Digital articles to share and explore

Special features:

- 200 Open Access Journals
- 15,000 editorial team
- 21 days rapid review process
- Quality and quick editorial, review and publication processing
- Indexing at PubMed (partial), Scopus, DOAJ, EBSCO, Index Copernicus and Google Scholar etc
- Sharing Option: Social Networking Enabled
- Authors, Reviewers and Editors rewarded with online Scientific Credits
- Better discount for your subsequent articles

Submit your manuscript at: <http://www.omicsonline.org/submission/>

