


Contents lists available at BioMedSciDirect Publications

International Journal of Biological & Medical Research

Journal homepage: www.biomedscidirect.com



Case report

A rare cause for seizures and mental retardation – Dyke Davidoff Masson Syndrome

Dr. Kumar S^{*a}, Dr. Lakshmaiah V^b, Dr. Karthik Naidu. KC^c

^{*a} Asst.Prof,Dept. of Medicine,Sri Devaraj Urs Medical College and Research Center,Tamaka,Kolar,Karnataka,INDIA.

^b Prof. & Medical Superintendent,Dept. of Medicine,Sri Devaraj Urs Medical College and Research Center,Tamaka,Kolar,Karnataka,INDIA.

^c Junior Resident,Dept. of Medicine,Sri Devaraj Urs Medical College and Research Center,Tamaka,Kolar,Karnataka,INDIA.

ARTICLE INFO

Keywords:

Cerebral hemiatrophy

Diagnosed

Homolateral hypertrophy

ABSTRACT

Dyke – Davidoff – Masson Syndrome (DDMS), also called as cerebral hemiatrophy, is a rare clinical condition characterized by seizures, facial asymmetry, contralateral spastic hemiplegia or hemiparesis, with learning difficulties. It is commonly diagnosed in presence of associated radiologic findings which include cerebral hemiatrophy with homolateral hypertrophy of the skull and sinuses. Here we report a case of DDMS in a 15 year old female patient who presented with seizures and mental retardation. Computerized Tomography of the brain showed hemi atrophy involving the left cerebral hemisphere. An X-ray of the Para nasal air sinuses was normal.

© Copyright 2010 BioMedSciDirect Publications IJBMR -ISSN: 0976:6685. All rights reserved.

1. Introduction

DDMS was first described by C.G. Dyke, L.M. Davidoff and C.B. Masson in 1933 in a series of nine patients with plain skull radiographic and pneumatoencephalographic changes [1,2]. The condition is characterized by cerebral hemiatrophy, facial asymmetry, thickening or thinning of cranial vault, contralateral hemiplegia or hemiparesis, seizures, mental retardation, and behavioural changes like schizophrenia [3-5]. The above features may be present in varying combinations and degrees of severity. Diagnosis is usually achieved by clinical examination and radiologic investigation. The condition is usually diagnosed in childhood but rare cases of the condition diagnosed in teenagers and young adults have been made. Here we describe a 15 year old female patient who presented to us with seizures, mental retardation and characteristic radiologic findings suggestive of DDMS.

2. Case Report

A 15 year old girl child was brought to the accident and emergency department with c/o involuntary movements of both upper and lower limbs with frothing from the mouth since 1 day. There was associated deviation of angle of mouth to the left.

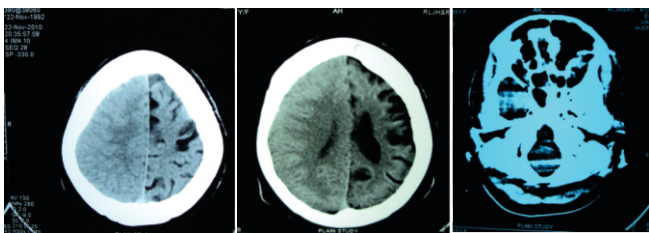
Patient had several such episodes with each episode lasting for approximately 5 minutes with loss of consciousness in between episodes with regaining of consciousness slowly. On further probing history similar episodes since the age of 7 years was obtained. Patient was a known case of seizure disorder and was not on regular medication. Further there was no control of seizures even when on medication. Patient was also given some native medicines but with no improvement in symptoms. Despite all the above efforts she was getting seizures regularly each episode lasting for about 5 minutes with complete recovery of consciousness within 15 minutes with no residual neurological deficits.

Patient's birth history was uneventful. However, patient's developmental history was significant with delayed milestones and mental retardation. Patient has not done any schooling so far. No history of any serious childhood infections like fever, neuroinfection or trauma could be elicited.

On examination, patient was an adolescent girl moderately built and nourished. She was disoriented to time place and person with irrelevant talking. Her general physical examination and vitals were normal. Examination of central nervous system revealed only hypotonia with exaggerated deep tendon reflexes and bilateral extensor plantar response along with fanning of toes. Examination of the other systems was unremarkable.

* Corresponding Author : Dr.Kumar.S
Asst.Prof.,Dept. of Medicine,
Sri Devaraj Urs Medical College,
Tamaka, Kolar, Karnataka, INDIA-563101
Mobile: 9900981096
E-mail: kumarsrinivasan67@gmail.com

An emergency Computerized Tomography of the brain showed hemi atrophy involving the left cerebral hemisphere. No comment could be made on Para nasal air sinuses. An X-ray of the Para nasal air sinuses was normal. Complete hemogram showed mild neutrophilic leucocytosis with WBC count of 14,700 cells/cumm and a differential count showing 93% lymphocytes. Her ESR was elevated to 70 mm/hour. Renal function tests were normal and serum electrolytes showed hyperkalaemia with K⁺ ion concentration being around 6.7 mEq/l. But, patient did not have any signs and symptoms of hyperkalaemia and ECG was within normal limits.



Patient was put on a combination of 3 anti-epileptic drugs [Eptoin, Valproic acid and Phenobarbitone]. But despite this, seizures could not be controlled. Before any further diagnostic work up could be done patient was taken to higher centre by her relatives for further management. And the patient was lost to follow up.

3. Discussion

DDMS is a rare condition characterized clinically by varying degrees of facial asymmetry, seizures, contralateral hemiparesis, mental retardation and learning disabilities with behavioural abnormalities [5,6]. The radiological findings include cerebral hemiatrophy, ipsilateral osseous hypertrophy and hyperpneumatization of sinuses [6]. Either sex may be affected with involvement of any cerebral hemisphere. Unal et al., in a retrospective study of 26 patients of cerebral hemiatrophy showed that it was more frequent in the males with left cerebral hemisphere involvement [7]. Clinical features vary depending on the extent of brain injury. A detailed history, meticulous clinical examination with radiologic findings provide clue to the diagnosis.

The disease is generally classified into Infantile (congenital) and Acquired variety [4]. Congenital variety is mainly caused due to vascular occlusions or malformations in-utero or in the neonatal period. Neonatal or gestational vascular occlusion involving the middle cerebral vascular territory, unilateral cerebral arterial circulation anomalies, coarctation of the mid-aortic arch, mesencephalon hypoplasia and Wallerian degeneration have been propounded as some of the etiologies for the congenital variety [3,4,8]. Hageman et al., proposed the terms cerebral hemi-hypoplasia or unilateral cerebral hypoplasia for the primary (congenital) cerebral atrophy owing to the fact that there is lack of cerebral development rather than atrophy [9]. When the cerebral hemiatrophy develops in-utero or during first two years of life, it is associated with certain cranial changes like ipsilateral hypertrophy of the skull and sinuses as a compensatory change to take up the relative vacuum created by the hypoplastic cerebrum [8]. The brain reaches half the adult

size during first year of life and three-fourths by the end of third year. As it enlarges, the brain presses outward on the bony tables which gradually results in general shape of the adult head. But, failure of the cerebrum to grow causes other structures to direct their growth inward, accounting for ipsilateral hyperpneumatization of the sinuses, increased width of the diploic space and elevations of the greater wing of the sphenoid and petrous ridge [3]. The other change in infantile type is a shift of midline structures towards the side of the disease and the sulcal prominence replacing the gliotic tissue is absent [8]. This feature differentiates it from cerebral hemiatrophy that occurs in later life.

Acquired variety may be due to infections, trauma, ischemia and hemorrhage. Age of presentation depends on the time of occurrence of the brain insult and often clinical features may not be evident till adolescence. The characteristic calvarial changes may or may not be present depending upon the time of injury. Further, these insults occur after birth, after completion of sulci formation [10]. In the case report presented above all the clinical features described suggest an acquired variety of the syndrome. However, mental retardation observed in this patient goes unexplained in the acquired variety.

The exact mechanism of cerebral atrophy is still unclear in either type. It is hypothesized that ischemic episodes from a variety of different causes reduce the production of brain derived neurotrophic factors, which in turn lead to cerebral atrophy [10]. Atalar et al., in their clinico-radiologic analysis of 19 patients concluded that, Computed tomography and, in particular, magnetic resonance imaging is the procedure of choice with respect to assessment of the etiology and extent of cerebral parenchymal involvement in cerebral hemiatrophy.

The condition needs to be differentiated from Basal ganglia germinoma, Sturge Weber syndrome, Linear nevus syndrome, Fishman syndrome, Silver-Russell syndrome and Rasmussen encephalitis [6].

The treatment is symptomatic, and includes management of convulsion, hemiplegia, hemiparesis and learning difficulties. Prognosis is better if hemiparesis occurs after the age of 2 years and in absence of prolonged or recurrent seizures. Children with intractable disabling and hemiplegia are the potential candidates for hemispherectomy with a success rate of 85% in carefully selected cases [6,8].

4. Reference

- [1] Dyke C G, Davidoff L M, Masson C B. Cerebral Hemiatrophy and homolateral hypertrophy of the skull and sinuses. Surg Gynecol Obstet. 1933; 57: 588-600.
- [2] Deniz, Yerdelen, Filiz, Zafer. Dyke – Davidoff – Masson Syndrome. Neurosurgery Quaterly. 2009; 19 (1): 59-61.
- [3] Sharma S, Goyal D, Negi A, Sood R G, Jhobta A, Surya M. Dyke – Davidoff – Masson Syndrome. Ind J Radiol Imag. 2006; 16(2): 165-166.
- [4] Pendse NA, Bapna P, Menghani V, Diwan A. Dyke – Davidoff – Masson Syndrome (DDMS). Ind J Paed. 2004; 71: 943.
- [5] Shetty DS, Lakhkar BN, John JR. Dyke-Davidoff-Masson syndrome. Neurol India. 2003; 51: 136
- [6] Narain NP, Kumar R, Narain B. Dyke – Davidoff – Masson Syndrome. Indian Pediatrics. 2008; 45: 927-928.5.

- [7] Unal O, Tombul T, Cirak B, Anlar O, Incesu L, Kayan M. Left hemisphere and male sex dominance of cerebral hemiatrophy (Dyke-Davidoff-Masson Syndrome). Clin Imaging. 2004; 28(3):163-5.
 - [8] Goyal J, Shah V, Rao S, Jindal N. Dyke Davidoff Masson syndrome in Children. The Internet Journal of Pediatrics and Neonatology. 2009; 10(2): 101-107.
 - [9] Hageman G, Gooskens R H J M, Willemse J, A cerebral cause of arthrogryposis: Unilateral cerebral hypoplasia. Clin Neurol Neurosurg. 1985; 87: 119-119-122.
 - [10] Lee JH, Lee ZI, Kim HK, Kwon SH. A case of Dyke – Davidoff – Masson syndrome in Korea. Korean Journal of Pediatrics. 2006; 49 (2): 208-211.
 - [11] Atalar MH, Icagasioglu D, Tas F. Cerebral hemiatrophy (Dyke-Davidoff-Masson syndrome) in childhood: clinicoradiological analysis of 19 cases. Pediatr Int. 2007 Feb; 49(1):70-7
- © Copyright 2010 BioMedSciDirect Publications IJBMR -ISSN: 0976:6685.
All rights reserved.