

Case Report

Open Access

A Case Report of Mucinous Carcinoma of Left Breast

Venkatachalapathy TS* and Sreeramulu PN

Sri Devaraj Urs Medical College, Tamaka, Kolar, Karnataka, India-563101

Abstract

We report a 60-year-old woman with locally advanced mucinous carcinoma of the breast with sudden growth acceleration. A pea-sized mass developed into an ulcerated large tumor within 1 month. After counseling the patient a modified radical mastectomy was performed. Histological examination revealed a mucinous carcinoma without axillary lymph node involvement. Estrogen and progesterone receptors were not detected in the tumor.

Pure mucinous carcinoma generally has a less aggressive growth pattern as defined by tumor size, adherence to the overlying skin/bottom fasciae, estrogen and progesterone receptor positive and absence of primary axillary lymph node metastases. This case showed completely similar features to all of the typical biological features of mucinous carcinomas.

Keywords: Mucinous carcinoma; Mastectomy; Combined treatment

Introduction

Mucinous carcinoma of the breast is one of the most common special histological types of breast carcinoma, but locally aggressive growth to form a large skin ulcer is rarely seen [1,2]. It is more prevalent in older patients [3,4]. The biological phenotype of mucinous carcinomas is quite favorable, as reflected in substantially less nodal involvement and a higher rate of estrogen receptor and progesterone receptor-positive cases [5]. Hence it usually has a better prognosis than does invasive ductal carcinoma [1-7].

Case Report

A 60-year-old woman was admitted to the hospital because of an ulcerated large tumor in the left breast. The patient stated that she noticed a pea-sized tumor 6 month before visiting the hospital, which grew rapidly and formed a ulceration and bleeding from the ulcer. She was upset when she visited this hospital, because of the rapid development of the tumor. Physical examination revealed a large tumor ~10 cm in diameter in the left breast, which involved almost the entire breast. It was ulcerated deeply as the cavity of tumour was clearly exposed. No lymph nodes palpated in the left axilla. There was no edema in the left arm. The right breast and opposite axilla and both supraclavicular fossa appeared normal.

Discussion

Because of the unusual size of the tumor and its sudden growth acceleration, we thought that this tumor might be cystosarcoma phyllodes before the histological result of biopsy specimen was obtained. We needed to analyze her mental status that made her ignore the tumor until the extremely advanced stage and to confirm that her statement on the history of the tumor was reliable.

The reported frequency of mucinous carcinoma of the breast is as high as 3.6% [8]. This type of the tumor is sub classified into two groups: 'pure' mucinous carcinoma that consists solely of tumor tissue with extracellular mucin production and 'mixed' mucinous carcinoma that also contains infiltrating carcinoma without mucin. Although the reported tumor clearly falls into the 'pure' mucinous type (Figure 1,2), this case is unusual not only in the sudden growth acceleration, but also in biological aspects of mucinous carcinoma. The mean age of women with pure mucinous carcinoma is greater than those with non-mucinous carcinoma, with Pure mucinous carcinoma has a less aggressive growth pattern, i.e. smaller tumor size, a lower frequency of adherence to the overlying skin/bottom fasciae and primary axillary

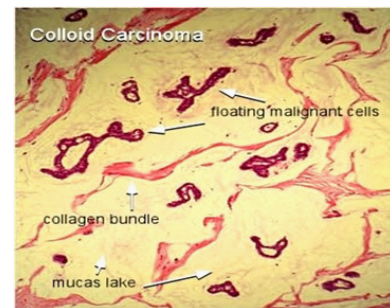


Figure 1: Pure Mucinous Carcinoma.

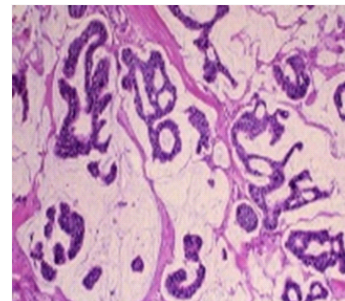


Figure 2: Pure Mucinous Carcinoma.

lymph node metastases and a higher percentage of positive estrogen receptor, compared with non-mucinous carcinoma [2-8]. This case showed completely similar features to all of these typical biological aspects of pure mucinous carcinomas [9]

There must be some explanation for the sudden growth

***Corresponding author:** Venkatachalapathy TS, Assistant Professor in Surgery, Sri Devaraj Urs Medical College, Tamaka, Kolar, Karnataka, India-563101, Tel: +918197507094; E-mail: Drvenkey@Hotmail.Com

Received February 03, 2012; Accepted April 20, 2012; Published April 28, 2012

Citation: Venkatachalapathy TS, Sreeramulu PN (2012) A Case Report of Mucinous Carcinoma of Left Breast. J Clin Case Rep 2:136. doi:10.4172/2165-7920.1000136

Copyright: © 2012 Venkatachalapathy TS, et al. This is an open-access article distributed under the terms of the Creative Commons Attribution License, which permits unrestricted use, distribution, and reproduction in any medium, provided the original author and source are credited.

acceleration of this tumor that led to the extremely locally advanced stage. Biological aspects of nuclear grading and status of c-erbB 2 and p53 are not correlated with the malignant potential of this tumor [10]. The accumulation of abundant extracellular mucin around invasive tumor cells is characteristic of mucinous carcinoma. In this tumor specimen, mucin formed nests where tumor cells were degraded or had already disappeared, i.e. a 'muconodular pattern'. This is a phenomenon that is seen when cells produce a large amount of mucin rapidly [11]. Although it is unknown what triggered the sudden growth of this tumor, rapid enlargement of the tumor by mucin production developed the extremely locally advanced breast tumor with deep ulcer formation.

References

1. Diab SG, Clark GM, Osborne CK, Libby A, Allred DC, et al. (1999) Tumor characteristics and clinical outcome of tubular and mucinous breast carcinomas. *J Clin Oncol* 17: 1442–1448.
2. Avisar E, Khan MA, Axelrod D, Oza K (1998) Pure mucinous carcinoma of the breast: clinicopathologic correlation study. *Ann Surg Oncol* 5: 447–451.
3. Rosen PP, Lesser ML, Kinne DW (1985) Breast carcinoma at the extremes of age: a comparison of patients younger than 35 years and older than 75 years. *J Surg Oncol* 28: 90–96.
4. Toikkanen S, Kujari H (1989) Pure and mixed mucinous carcinomas of the breast: a clinicopathologic analysis of 61 cases with long-term follow-up. *Hum Pathol* 20: 758–764.
5. Fentiman IS, Millis RR, Smith P, Ellul JP, Lampejo O (1997) Mucoïd breast carcinomas: histology and prognosis. *Br J Cancer* 75: 1061–1065.
6. Tabar L, Fagerberg G, Chen HH, Duffy SW, Gad A (1996) Tumour development, histology and grade of breast cancers: prognosis and progression. *Int J Cancer* 66: 413–419.
7. Andre S, Cunha F, Bernardo M, Meneses e Sousa J, Cortez F, et al. (1995) Mucinous carcinoma of the breast: a pathologic study of 82 cases. *J Surg Oncol* 58: 162–167.
8. Komaki K, Sakamoto G, Sugano H, Morimoto T, Monden Y (1988) Mucinous carcinoma of the breast in Japan. A prognostic analysis based on morphologic features. *Cancer* 61: 989–996.
9. Rasmussen BB, Rose C, Christensen IB (1987) Prognostic factors in primary mucinous breast carcinoma. *Am J Clin Pathol* 87: 155–160.
10. Scopsi L, Andreola S, Pilotti S, Bufalino R, Baldini MT, et al. (1994) Mucinous carcinoma of the breast. A clinicopathologic, histochemical, and immunocytochemical study with special reference to neuroendocrine differentiation. *Am J Surg Pathol* 18: 702–711.
11. Page DL (2003) Special types of invasive breast cancer, with clinical implications. *Am J Surg Pathol* 27: 832–835.