

A Case Report of Large Renal Cell Carcinoma

Venkatachalapathy TS^{1*}, Sreeramulu PN² and NagendraBabu T¹

¹Assistant Professor of Surgery, Sri Devaraj Urs Medical College & RI Jalappa Hospital and Research Centre, Tamaka, Kolar, Karnataka, India

²Professor of Surgery, Sri Devaraj Urs Medical College & RI Jalappa Hospital and Research Centre, Tamaka, Kolar, Karnataka, India

Abstract

We report a case of 70 yr old woman with history of mass per abdomen since 5 months, which was insidious in onset and gradually progressed to present size. It was not associated with fever, haematuria, but gives history of loss of weight and loss of appetite. She was emaciated, poorly nourished with no significant past history. On examination she had mass per abdomen occupying Right lumbar, hypochondrium, umbilical, Right iliac fossa and hypogastrium abutting the anterior abdominal wall. No free fluid, no organomegaly. No evidence of swellings in other part of body, and no supraclavicular lymphadenopathy.

Keywords: Mass abdomen; Renal cell carcinoma; CT abdomen

Introduction

Renal cell carcinoma (RCC) was first reported by Paul Grawitz in 1883. It was named after him as Grawitz tumor, or hyper nephroma, according to his belief that the tumor originated in adrenal rests at the upper pole of the kidney. Later, the origin of this tumor in renal tubular cells was documented [1]. Accounting for 2% of all adult malignancies [2], RCC has tendency to spread into the renal vein and the IVC (inferior vena cava). Late presentation is the common initial diagnosis in our part of the world [3], making operative treatment more challenging. Kidney cancer is among the 10 most common cancers in both men and women.

Case Report

We report a case of 70 year old woman with history of mass per abdomen since 5 month's, which was insidious in onset and gradually progressed to present size. It was not associated with fever, haematuria, but gives h/o loss of weight and loss of appetite. She was emaciated, poorly nourished with no significant past history. On examination she had mass per abdomen occupying Right lumbar, hypochondrium, umbilical, Right iliac fossa and hypogastrium abutting the anterior abdominal wall. No free fluid, no organomegaly. No evidence of swellings in other part of body, and no supraclavicular lymphadenopathy. Blood investigations: Haemoglobin- 9.9 gms%, Hematocrit-28.2%, Total Count- 7700 cells/mm³, Neutrophils- 85, Lymphocytes-10, Eosinophils-02, Monocytes-03. Bleeding Time- 2' 15", Clotting Time - 4' 30". Peripheral smear - normocytic normochromic anemia. Blood urea- 21 mg%, serum creatinine - 0.85 mg%, Random blood sugar (RBS) - 84 mg%; Liver function tests (LFT), Alkaline phosphatase (ALP)- 471 IU/L, Gamma Glutamyl transaminase (GGT)- 232 IU/L. X Ray chest - no secondaries, no effusion. USG (Ultrasonography) abdomen revealed a large heterogeneous mass occupying Right lumbar, Right hypochondrium, Umbilical and crossing the midline measuring 15 × 12 × 10.5 cm. Right kidney not visualized, Left kidney normal. Liver shows multiple hyperechoic lesions in both lobes largest measuring 3.2 × 2.6 × 3.5 cm seen. The tumor stage was T4 N1 M1 (stage IV). The five year survival rate of stage IV- 8% (Figures 1 and 2).

Computerized Axial Tomography

Abdomen (Plain and Contrast) a well defined large lobulated mass seen in Right renal region extending from sub hepatic region to pelvis, medially crossing midline extending to the medial surface of Left kidney. Encasing retroperitoneal great vessels and renal vessels, measuring 17 × 14 × 13.5 cm. multiple hypodense areas and calcified areas noted. On contrast mass shows heterogeneous enhancement, IVC

(inferior vena cava) compression by the mass. No thrombosis of the IVC (inferior vena cava) and renal vein. After 24 hrs scan small amount of contrast excreted at periphery. No free fluid. Other solid organs were normal.

Liver multiple hypodense areas were seen, largest measuring 3.2 × 2.6 × 3.5 cm. Bilateral pleural effusion seen (Figures 3,4 and 5). FNAC (Fine needle aspiration cytology) shows round to polygonal cells having coarse chromatin. 2-4 nucleoli arranged in discreates. The nuclear

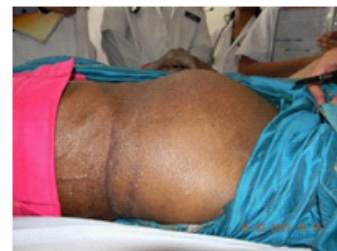

Figure 1: Mass abutting ant abdomen.

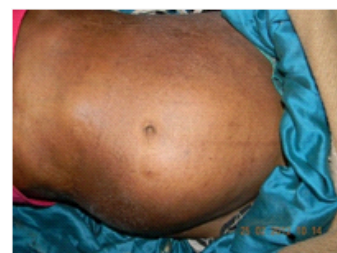

Figure 2: Mass occupying entire abdomen.

***Corresponding author:** Venkatachalapathy TS, Assistant Professor of Surgery, Sri Devaraj Urs Medical College & RI Jalappa Hospital and Research Centre, Tamaka, Kolar, Karnataka, India-563101, Tel: 8197507094; E-mail: drvenkey@hotmail.com

Received March 05, 2012; **Accepted** March 29, 2012; **Published** April 04, 2012

Citation: Venkatachalapathy TS, Sreeramulu PN, NagendraBabu T (2012) A Case Report of Large Renal Cell Carcinoma. J Clinic Case Reports 2:120. doi:10.4172/2165-7920.1000120

Copyright: © 2012 Venkatachalapathy TS, et al. This is an open-access article distributed under the terms of the Creative Commons Attribution License, which permits unrestricted use, distribution, and reproduction in any medium, provided the original author and source are credited.

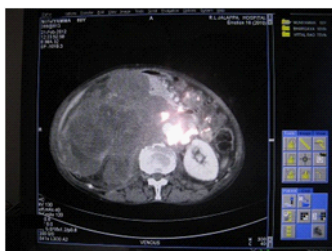


Figure 3: Renal mass Right side.

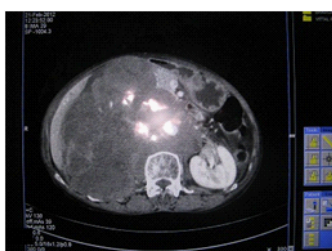

Figure 4: Renal mass Right side.

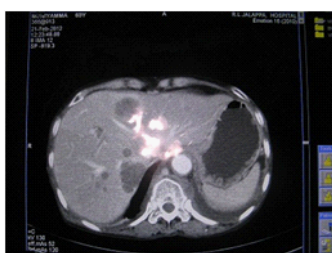

Figure 5: Renal mass with secondaries liver.

margin prominent, the cytoplasm is scant these cells are arranged in solid cells clumps with a flowery arrangement featured suggestive of adeno carcinoma / Renal cell carcinoma [4].

Discussion

Malignant neoplasms involving the kidney may be primary or secondary tumors. Although metastatic lesions outnumber primary tumors, secondary renal neoplasms are usually clinically insignificant and are principally discovered at postmortem examination.

Patients with Renal cell carcinoma (RCC) present with a range of symptoms, but many are asymptomatic until the disease is advanced [5]. At presentation, approximately 25 percent of individuals either have distant metastases or significant local-regional disease. Other patients, even some with only localized disease, present with a wide array of symptoms and/or laboratory abnormalities. Because of this unusual characteristic, RCC has been labeled the “internist’s tumor” [1]. Today, most tumors are diagnosed incidentally [6].

The classic triad of flank pain, hematuria and flank mass is uncommon (10% cases) and is indicative of advanced disease. Renal cell carcinoma represents a heterogeneous group of tumors, the most common of which is clear cell adenocarcinoma [7]. RCC accounts for 3% of adult tumors. The incidence has increased more than 30% over the past two decades. It is generally accepted that the increased

incidence rates reflect earlier diagnosis at an earlier stage, largely due to more liberal use of radiological imaging techniques. However advanced disease has also been diagnosed more frequently and mortality has increased as well [6].

Symptomatic presentation correlates with aggressive histology and advanced disease. Incidental tumors may be frequently detected in female and elderly patients, as these groups traditionally seek general medical care more regularly. The mode of presentation can independently predict an adverse patient outcome. Indicators of symptomatic presentations include flank pain, flank mass, varicocele, constitutional symptoms, paraneoplastic syndromes and bone pain related to metastatic disease [8].

Ultrasound scan was found to be useful screening test, but CT (Computerized tomography) is the imaging study of choice to identify malignant features. MRI (Magnetic resonance imaging) can be used in equivocal cases [6].

Pre-operative clinical variables may be used instead of the pathological stage to determine the risk of recurrence [3].

References

1. Kirkali Z, Obec C (2003) Clinical aspects of Renal Cell Carcinoma. EAU Update Series 1: 189-196.
2. Luciani LG, Castari R, Tallarigo C (2000) Incidental Renal Cell Carcinoma- age and stage characterization and clinical implications; a study of 1092 patients (1982–1997). Urology 56: 58-62.
3. Lee CT, Katz J, Fearn PA, Russo P (2000) Mode of presentation of Renal Cell Carcinoma- provides prognostic information. Urol Oncol 7: 135-140.
4. Brierly RD, Thomas PJ, Harrison NW, Fletcher MS, Nawrocki JD, et al. (2000) Evaluation of fine-needle aspiration cytology for renal masses. BJU Int 85: 14-18.
5. Greenberg RE, Cooper J, Knigel RL, Richter RM, Kessler H, et al. (1992) Hoarseness, A unique clinical presentation of Renal cell Carcinoma. Urology 40: 159-161.
6. Nassir A, Jollimore J, Gupta R, Bell D, Norman R (2002) Multilocular cystic Renal Cell Carcinoma; a series of 12 cases and a review of literature. Urology 60: 421-427.
7. Patard JJ, Leray E, Rodriguez A, Rioux-Leclercq N, Guille F, et al. (2003) Correlation between symptom graduation, tumor characteristics and survival in renal cell carcinoma. Eur Urol 44: 226-232.
8. Doda SS, Mathur RK, Buxi TS (1986) Role of computed tomography in staging of renal cell carcinoma. Comput Radiol 10: 183-188.