The association for medical ultrasound
aium
AMERICAN INSTITUTE OF ULTRASOUND IN MEDICINE

CME Course
POWERED BY THE AIUM

AMERICAN INSTITUTE OF ULTRASOUND IN MEDICINE (AIUM)

Advanced OB-GYN Ultrasound Seminar

February 20–23, 2019 | Disney's Yacht and Beach Club Resorts | Lake Buena Vista, FL

Register to attend in-person or live stream

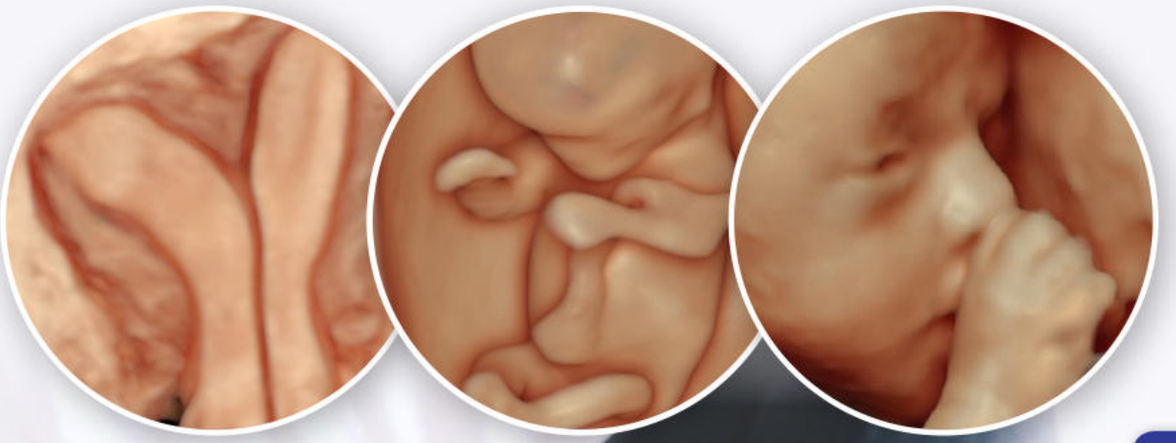

REGISTER TODAY!

American Institute of Ultrasound in Medicine
14750 Sweitzer Ln , Suite 100
Laurel, MD 20707
aium.org | 800-638-5352

IN PARTNERSHIP WITH

ORLANDO HEALTH

Wake Forest® School of Medicine

Spontaneous Antepartum Vesicouterine Fistula Causing Severe Oligohydramnios in a Patient With a Previous Cesarean Delivery

Videos online at www.jultrasoundmed.org

A 26-year-old woman, gravida 2, para 1, at 18 weeks' gestation with a previous uneventful cesarean delivery presented to the emergency department with acute onset of lower abdominal pain and passage of blood in the urine. She denied vaginal bleeding and a history of hematuria or urinary incontinence. On examination, she was in mild distress, with a pulse rate of 94 beats per minute, blood pressure of 104/74 mm Hg, and mild tenderness in the suprapubic region. Examination of other systems was unremarkable. Laboratory studies showed a hematocrit value of 41%, a platelet count of 281,000/μL, a fibrinogen level of 482 mg/dL, an international normalized ratio of 0.89, and an activated partial thromboplastin time of 31 seconds.

Sonography revealed a single live intrauterine gestation of 18 weeks 1 day. The fetal heart rate was 171 beats per minute. The single deepest cord-free pocket of amniotic fluid was 1.2 cm. The placenta was situated in the fundal region. No retroplacental hemorrhagic clot was seen. A small hypoechoic defect was seen in the walls between the anterior wall of the lower segment of the uterus above the isthmus and posterior wall of the urinary bladder, suggesting a vesicouterine fistula (Figure 1A). The fistulous tract measured approximately 12 mm in diameter. There was rhythmic movement of the linear soft echoes into the urinary bladder through the fistula, corresponding to uterine contractions, and coming back into the uterine cavity during uterine relaxation on dynamic sonography (Figure 1B and Video 1), which were thought to be ruptured amniotic membranes. Color Doppler sonography showed abnormal color flow in the fistulous tract during the uter-

Figure 1. Spontaneous antepartum vesicouterine fistula causing severe oligohydramnios in a 26-year-old woman. **A**, Gray-scale sonogram at a gestational age of 18 weeks 1 day showing a hypoechoic fistulous tract (arrow) measuring 12 mm communicating between the anterior wall of the uterus and posterior wall of the urinary bladder (UB). The thick linear band of echoes anterior to the fetal head was composed of detached membranes (arrowhead). Note the fetal head (FH) lying just above the fistula. **B**, Gray-scale sonogram showing herniation of the amniotic membranes into the urinary bladder through the fistula (arrow). **C**, Color Doppler sonogram showing abnormal color flow of the amniotic fluid through the fistula (arrowhead) with increased vascularity in the uterine wall adjacent to the fistula (arrow).

A

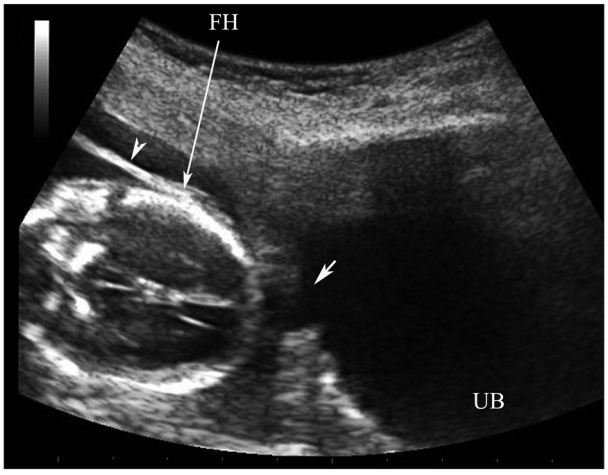

B

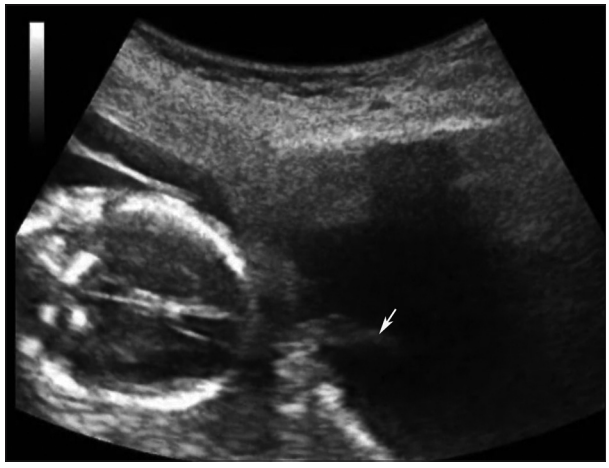

C

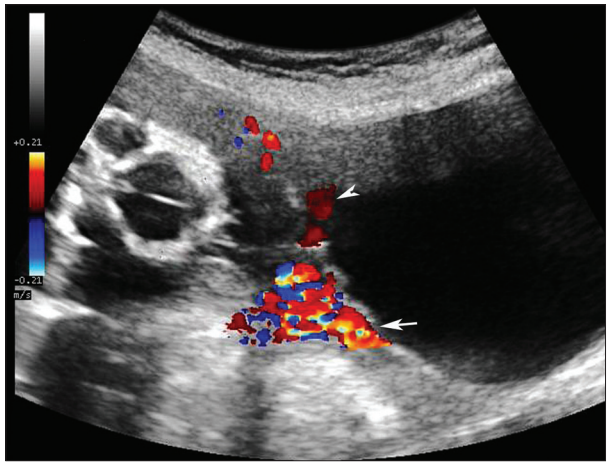

ine contractions, which could have been due to movement of amniotic fluid or blood along with the membranes through the fistulous tract between the two cavities (Video 2). Mild increased vascularity was seen in the uterine wall adjacent to the fistulous tract (Figure 1C). A thick linear band of echoes was seen anterior to the head of the fetus with a mild fluid collection between this band and the uterine wall, which was thought to be detached amniotic membranes with amniotic fluid or blood tracking between the detached membranes and uterine wall. The diagnosis of an antepartum vesicouterine fistula with ruptured amniotic membranes causing oligohydramnios was made.

Intraoperatively, the fistula was seen between the posteroinferior wall of the bladder and the anterior wall of the lower segment of the uterus above the isthmus. The uterine and bladder walls adjacent to the fistula were hyperemic. Amniotic membranes were ruptured at the fistulous site and detached in the anterior aspect of the amniotic cavity. The fluid remaining in the amniotic cavity after preoperative draining of the bladder through a Foley catheter contained blood mixed with amniotic fluid. No clots could be identified. Surgical termination of the pregnancy was performed. The defects in the urinary bladder and uterus were separately closed in multiple layers. Postoperatively, a transurethral Foley catheter was kept indwelling for 2 weeks to drain the urinary bladder. The postoperative period was uneventful. Cystography performed before removing the Foley catheter showed normal findings. After 8 weeks, sonography focused on the repaired walls of the urinary bladder and uterus showed a normal appearance. The patient was fully continent with normal menstruation during further follow-up visits.

A vesicouterine fistula is an abnormal communication between the anterior wall of the uterus and posterior wall of the urinary bladder. Vesicouterine fistulas account for only 1% to 4% of all urogenital fistulas. In modern obstetric practice, more frequent use of cesarean delivery leads to an increased prevalence of vesicouterine fistulas.[1] A considerable number of spontaneous intrapartum[2] and postpartum vesicouterine fistulas with or without previous cesarean deliveries have been reported in the literature.[1] Bertin et al[3] reported a patient with amniotic sac herniation into the bladder through a vesicouterine fistula during the 32nd week of pregnancy without rupture of the amniotic sac. To our knowledge, a spontaneous antepartum vesicouterine fistula causing oligohydramnios and its sonographic features have not been reported previously in the literature.

Although the pathogenesis of a vesicouterine fistula is unclear, it may occur as a result of occult injury to the urinary bladder during lower-segment cesarean delivery.[4] In our patient, it might have been possible that trauma to the uterine and bladder walls occurred during previous low cesarean delivery, causing dehiscence during the present gestation. It is difficult to prove this possibility because the patient was asymptomatic after the previous cesarean delivery. Gross antepartum hematuria with lower abdominal pain in a pregnant woman may indicate an acute vesicouterine fistula after rupture of the uterus and warrants evaluation of the uterus and urinary bladder.

Sonography should be performed with a full bladder to show the fistula. It clearly shows the fistulous communication as a hypoechoic defect in the walls between the posterior wall of the urinary bladder and the anterior wall of the lower segment of uterus. Color Doppler imaging may show fluid flow between the cavities through the fistula with increased vascularity around the fistula tract. Transvaginal sonography may also show the abnormal hypoechoic fistulous communication.[1] Our patient clearly showed the fistulous communication along with rhythmic movement of the soft echoes in and out of the bladder through the fistula, corresponding to uterine contractions, which was confirmed to be ruptured amniotic membranes postoperatively. Increased vascularity in the uterine wall around the fistulous tract was caused by hyperemia and inflammation.

Various treatment approaches have been described in the literature for vesicouterine fistulas. An early fistula is managed conservatively by allowing the fistula to close with continuous catheter drainage of the bladder and antibiotic administration. Alternatively, fulguration and hormone therapy may be used.[1]

Surgery is the mainstay and definitive treatment of vesicouterine fistulas. The recommended approach is transabdominal excision of the fistulous tract between the uterus and bladder with closure of each organ in multiple layers.[1] Recently, laparoscopy[5] and robotic surgery[6] have been proposed as successful options for repair of a vesicouterine fistula. Because our patient had a large fistula with amniotic fluid leakage into the urinary bladder, resulting in severe oligohydramnios, surgical repair of the fistula was considered.

In conclusion, a spontaneous antepartum vesicouterine fistula is rare and can be a cause of oligohydramnios. A pregnant woman presenting with hematuria and lower abdominal pain with a previous cesarean delivery should be evaluated for a vesicouterine fistula. Early and definite diagnosis of the fistula is very important for timely inter-

vention. In an antepartum vesicouterine fistula, sonography and color Doppler imaging can evaluate the status of the fetus and the location and size of the fistula effectively.

Manjunatha YC, MD, DNB, Pradeep Sonwalkar, MD
Department of Radiodiagnosis
Sri Devaraj Urs Medical College
Tamaka, Kolar, India (Y.C.M.)
Department of Radiodiagnosis
Bijapur Liberal District Education Association Shri B. M. Patil Medical College
Smt Bangaramma Sajjan Campus
Bijapur, India (P.S.)

References

1. Porcaro AB, Zicari M, Zecchini Antoniolli S, et al. Vesicouterine fistulas following cesarean section: report on a case, review and update of the literature. *Int Urol Nephrol* 2002; 34:335–344.
2. Kaaki B, Gyves M, Goldman H. Spontaneous intrapartum vesicouterine fistula. *Obstet Gynecol* 2006; 107:449–450.
3. Bertin R, Roscigno M, Colombo R, Spagnolo D, Ferrari A, Rigatti P. Herniation of the amniotic sac into the bladder through a vesico-uterine fistula in the 32nd week of pregnancy. *BJOG* 2001; 108:1300–1301.
4. Tancer ML. Vesicouterine fistula: a review. *Obstet Gynecol Surv* 1986; 41:743–753.
5. Kemal AK, Kumar R, Nabi G. Post-cesarean cervicovesical fistula: technique of laparoscopic repair. *J Urol* 2001; 165:1167–1168.
6. Hemal AK, Sharma N, Mukherjee S. Robotic repair of complex vesicouterine fistula with and without hysterectomy. *Urol Int* 2009; 82:411–415.