

Case Report

Exteriorisation of Omentum from Necrosed Skin an unusual Complication of Incisional Hernia in a Tertiary Rural Health Centre

Paul Dhinakaran, Krishna Prasad, Dinesh Kumar Sathanantham*, Sreeramulu PN, and Amal Abraham

Department of General Surgery, Sri Devaraj Urs Medical College, India

***Corresponding author**

Dinesh Kumar Sathanantham, Department of General Surgery, Sri Devaraj Urs Medical College, India, Email: dinesh.sathanantham@gmail.com

Submitted: 21 May 2017

Accepted: 24 December 2017

Published: 27 December 2017

Copyright © 2017 Sathanantham et al.

ISSN: 2373-9819

OPEN ACCESS

Keywords

- Unusual complications
- Eviscerated omentum
- Incisional hernia
- Incarcerated uterus
- Polypropylene mesh

Abstract

Incisional hernia represents a breakdown or loss of continuity of a fascial closure. It is one of the most frequent long term complications of abdominal surgeries. These hernias are of particular concern not only for the high recurrence rates among them but also for the challenges that follow their repair. It is known to occur in 11-23% of laparotomies. This paper presents one of the unusual complications of incisional hernia managed by the authors. One ruptured incisional hernia with evisceration of omentum. The patient with ruptured hernia and eviscerated gut presented immediately and was resuscitated and the hernia repaired with on lay pre-peritoneal polypropylene mesh. Incisional hernia can present with unusual complications. The management is very challenging. Good knowledge and skills are required to deal with this condition.

INTRODUCTION

Incisional hernia (IH) represents a breakdown or loss of continuity of a fascia closure. IH occurs in 11-23% of laparotomies [2]. It enlarges over time and can give rise to such complications as pain, discomfort, bowel obstruction, incarceration and strangulation. Furthermore, IHs reduce the quality-of-life and the chances of employment [3]. Prolonged pressure and stretch on skin leads to skin problems such as attenuated skin, depigmentation or hypo pigmentation of the skin, ulceration and infection [3].

These hernias are of particular concern not only for the high recurrence rate among them, but also for the challenges that are associated with their repair [4].

The aim of this article is to discuss the unusual case of complications of IH managed by the authors and then to review the literature on management and complications of IH. Evisceration of gut secondary to ruptured incisional hernia

A 54-year-old woman presented at the Accident and Emergency Dept. of R.L. Jalappa hospital (Tertiary rural health centre), Kolar, Karnataka, India, with c/o pain in abdomen and exteriorization of abdominal contents since 8 hours prior to hospitalization. Patient gives history of exploratory laparotomy 2 years back for hollow viscus perforation followed with blackish discoloration of the skin over the lower abdomen surrounding the incision since 2 months with itching over it since 15 days and development of a small ulcer over it since 2 days, which

subsequently got opened, exteriorizing the abdominal contents since 8 hours day. There was no associated bleeding or loss of consciousness. Patient was rushed to the emergency unit of the hospital and. Patient was admitted into casualty. The eviscerated gut was washed with normal saline and covered with abdominal mop soaked in warm saline and was rehydrated with intravenous fluid. Nasogastric tube was also passed. The hernia defect was 20 cm × 16 cm.

She was then taken to the theater within 1 hr and operative repair with on lay i.e. Preperitoneal placement of Polypropylene mesh was done. Post-operative period was largely uneventful, but had seroma and superficial wound breakdown. This healed on daily dressing the abdominal drain was removed on post operative day #8. She was discharged at POD #10. She was followed-up for 1 year and there was no evidence of recurrence or any other complication.

DISCUSSION

Incisional hernia is known to occur in 11-23% of laparotomies.² Predisposing factors to Incisional Hernias can be categorized into two broad groups: "Patient factors" (obesity, old age, abdominal distension, post-operative cough, jaundice and wound sepsis) and "surgeons factors" (type of incision, closure technique and type of suture materials used) [1,5,6].

The challenge in managing this type of hernia include problem of loss of domain due to the prolonged housing of intra-abdominal viscera outside the abdominal cavity. This can lead

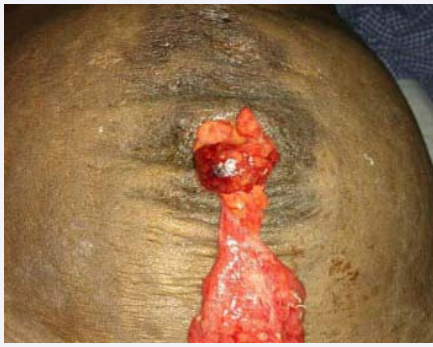

Figure 1 Intra Op showing the exteriorisation of omentum following skin necrosis.

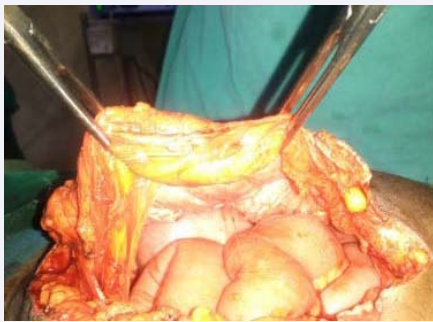


Figure 2 Mobilisation and reduction of omental contents.

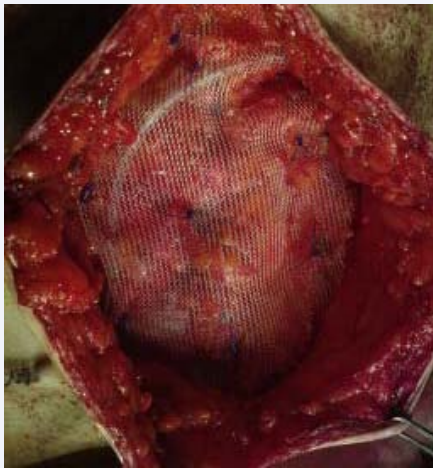


Figure 3 Mesh Placement on lay technique with Drain.

to raised intra-abdominal tension when the hernia contents are reduced or from attenuated respiratory muscle that make it difficult for patients to ventilate themselves during the post-operative period. Abdominal hypertension can also lead to serious intraoperative and post-operative hypertension hypotension due to compression of the inferior vena cava.

Repair of incisional hernia is recommended to avoid complications such as incarceration and strangulation of intestines and improve severe disability due to loss of abdominal

wall domain. Lasting surgical repair of these hernias continues to be elusive. 18-41% of ventral hernias recur after initial repair and once repaired, the incidence of a second recurrence can exceed 50 percent [2]. An effective ventral hernia repair should be achieved, with the goals of minimal perioperative morbidity and low recurrence rate.

Apart from midline laparotomies, caesarian section also is a leading cause of incisional hernias with incidence of about 27% and 48% in Benin and Zaria respectively. Also cesarean section is the most common surgery that leads to Incisional Hernia in Enugu [4]. It may not be unrelated to the fact that most of the cesarean sections are performed as emergencies and wound closures are hurriedly performed [7]. Besides, most are carried out by surgeons who are below consultant's status and general practitioners whose surgical techniques are queried. This category of "surgeons" most times does not use non-absorbable sutures in fascia closure [8]. Even when cesarean section is excluded, it is still more common in females. This is likely because females are more prone to develop IH due to the lax abdominal muscles and stretched fascia planes from repeated pregnancies, especially in Nigeria [9,10]. Incisional Hernia, can present early after the index surgery or many years subsequently [5]. The two cases, we managed, presented many years after the primary surgery. They presented with unusual cases, which are ruptured Incisional Hernia, with extravasations of bowel contents and Incisional Hernia with incarcerated gravid uterus in a woman at term.

Spontaneous rupture of abdominal hernia is very rare and usually occurs in incisional and recurrent groin hernia [11] only few cases of spontaneous rupture of abdominal hernia are reported in the literature. Large IH is contained only by its sac and thin avascular skin. Larger the hernia, more atrophic and avascular is the overlying skin and this along with thin sac leads to higher chances of rupture of IH [12]. Neglect for early operative intervention or delay in seeking for treatment increases the risk of rupture [13,14]. The rupture may be sudden following any event, which can increase intra-abdominal pressure such as coughing, lifting heavy weight, straining at defecation and micturition or it may be gradual after developing an ulcer at its base [12]. In our case, rupture of an IH occurred due to the sudden rise in intra-abdominal pressure following a cough and also with predisposing ulcer skin ulcer formation a day prior to it. The hernia contents can be covered primarily by mesh repair

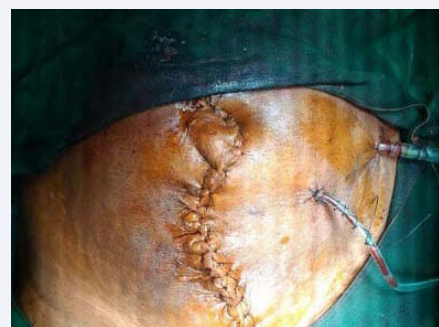

Figure 4 Skin closure and drain placement.

if the general condition and condition of the operative site allows or can be covered by skin followed by delayed mesh repair [15]. In our case, we covered the hernia contents primarily by polypropylene mesh.

An infrequent, but more serious complication is incarceration of gravid uterus with or without strangulation along with ulceration and excoriation of the overlying skin [12,17].

The management of pregnant patients with IH depends upon the trimester they are presenting. For those presenting early in pregnancy, manual reduction of hernia and use of an abdominal binder during the antenatal period and labor has been applied with varying success [12,13,17,18].

Surgical intervention in the form of antenatal hernia repair in the second and third trimesters has also been undertaken in two patients and then the pregnancy carried to term and normal vaginal delivery allowed [14,18]. Strangulation at or near term appears to be a genuine indication for early hospitalization and elective caesarean section, possibly combined with hernia repair, which has successfully been reported [11,12,16,17]. In cases of ruptured hernia with eviscerated gut although wound is contaminated, immediate repair of the hernia with polypropylene mesh can be performed as was done in one of the case presented here. Polypropylene prostheses, due to their macroporous structure, are sufficiently resistant to infections. In addition, polypropylene mesh allows for in growth of native fibroblasts and incorporation into the surrounding tissue [21]. This further allows blood supply to the mesh and further enhances its resistances to infections.

CONCLUSION

In conclusion, this article has presented some unusual complication of Incisional Hernia and the ways of managing them, as because a little delay in management of these complications can be fatal, leading to increased morbidity and mortality.

REFERENCES

1. Santora TA, Roslyn JJ. Philadelphia: WB Saunders Company. Incisional hernia: Hernia surgery in the surgical clinics of North America. 1993; 73: 557-570.
2. Cassar K, Munro A. Surgical treatment of incisional hernia. Br J Surg. 2002; 89: 534-545.
3. Dur AH, den Hartog D, Tuinebreijer WE, Kreis RW, Lange JF. Low recurrence rate of a two-layered closure repair for primary and recurrent midline incisional hernia without mesh. Hernia. 2009; 13: 421-426.
4. Ezeome ER, Nwajiobi CE. Challenges in the repair of large abdominal wall hernias in Nigeria: review of available options in resource limited environments. Niger J Clin Pract. 2010; 13: 167-172.
5. Houck JP, Rypins EB, Sarfeh IJ, Juler GL, Shimoda KJ. Repair of incisional hernia. Surg Gynecol Obstet. 1989; 169: 397-399.
6. Bucknall TE, Cox PJ, Ellis H. Burst abdomen and incisional hernia: a prospective study of 1129 major laparotomies. Br Med J (Clin Res Ed). 1982; 931-933.
7. Ohanaka EC, Osarenkhoe O. Management of ventral incisional hernia. Is there still a place for mayo's repair? Niger J Clin Pract. 1998; 1: 90-92.
8. Garba ES. The pattern of adult external abdominal hernias in Zaria. Niger J Surg Sci. 2000; 2: 12-15.
9. Gali BM, Madziga AG, Na'aya HU, Yawe T. Management of adult incisional hernias at the University of Maiduguri Teaching Hospital. Niger J Clin Pract. 2007; 10: 184-187.
10. Saha PK, Rohilla M, Prasad GR, Dhaliwal LK, Gupta I. Herniation of gravid uterus: report of 2 cases and review of literature. MedGenMed. 2006; 8: 14.
11. Zinner MJ, Schwartz SI, Ellis H. USA: Appleton and Lange. Incisions, closures, and management of the wound. Maingot's Abdominal Surgery. 1997; 10: 423.
12. Singla SL, Kalra U, Singh B, Narula S, Dahiya P. Ruptured incisional hernia. Trop Doct. 1997; 27: 112-113.
13. Hamilton RW. Spontaneous rupture of an incisional hernia. Br J Surg. 1966; 53: 477-479.
14. Mudge M, Hughes LE. Incisional hernia: a 10 year prospective study of incidence and attitudes. Br J Surg. 1985; 72: 70-71.
15. Sagar J, Sagar B, Shah DK. Spontaneous rupture of incisional hernia. Indian J Surg. 2005; 67: 280-281.
16. Banerjee N, Deka D, Sinha A, Prasad R, Takkar D. Gravid uterus in an incisional hernia. J Obstet Gynaecol Res. 2001; 27: 77-79.
17. Boys CE. Strangulated hernia containing pregnant uterus at term. Am J Obstet Gynecol. 1945; 50: 450-452.
18. Naspal M, Kaur S. Herniated pregnant uterus with bleeding from previous abdominal scar. J Obstet Gynaecol India. 2003; 53: 283.
19. Fullman PM. An incisional hernia containing an incarcerated twin pregnant uterus. Am J Obstet Gynecol. 1971; 111: 308-309.
20. D'Ambrosio R, Capasso L, Sgueglia S, Iarrobino G, Buonincontro S, Carfora E, et al. The meshes of polypropylene in emergency surgery for strangulated hernias and incisional hernias. Ann Ital Chir. 2004; 75: 569-573.
21. Maalangoni MA, Gagliardi RJ. Hernias. In: Townsend CM, editors. Sabiston Textbook of Surgery, 17th edn. Philadelphia, Pennsylvania: Elsevier Saunders. 2004; 1213.

Cite this article

Dhinakaran P, Prasad K, Sathanantham DK, Sreeramulu PN, Abraham A (2017) Exteriorisation of Omentum from Necrosed Skin an unusual Complication of Incisional Hernia in a Tertiary Rural Health Centre. JSM Clin Case Rep 5(4): 1110.