

See discussions, stats, and author profiles for this publication at: <https://www.researchgate.net/publication/318483343>

A prospective study of 30 cases of PHILOS plating for displaced proximal humeral fractures

Article · July 2017

DOI: 10.22271/ortho.2017.v3.i3b.14

CITATION

1

READS

35

3 authors, including:



[Srinivas Pandurangaiah](#)

Sri Devaraj Urs Medical College

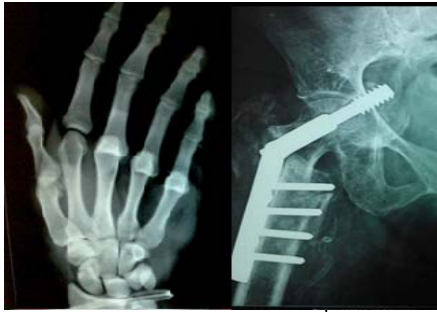6 PUBLICATIONS 1 CITATION

SEE PROFILE

Some of the authors of this publication are also working on these related projects:



Periarticular steroid for peri arthritis of shoulder [View project](#)



International Journal of Orthopaedics Sciences

ISSN: 2395-1958
IJS 2017; 3(3): 86-91
© 2017 IJS
www.orthopaper.com
Received: 14-05-2017
Accepted: 15-06-2017

Siddaram N Patil
Professor and Unit Head,
Unit 2, Department of
Orthopaedics, Sri Devaraj Urs
Medical College, Tamaka, Kolar,
Karnataka, India

Pandurangaiah Srinivas
Assistant Professor, Department
of Orthopaedics, Sri Devaraj Urs
Medical College, Tamaka, Kolar,
Karnataka, India

Vaibhav Bhadbade
Postgraduate Student,
Department of Orthopaedics,
Sri Devaraj Urs Medical College,
Tamaka, Kolar, Karnataka,
India

A prospective study of 30 cases of PHILOS plating for displaced proximal humeral fractures

Siddaram N Patil, Pandurangaiah Srinivas and Vaibhav Bhadbade

DOI: <http://dx.doi.org/10.22271/ortho.2017.v3.i3b.14>

Abstract

Introduction: Fractures of proximal humerus is still unsolved fractures in many ways. The Proximal humeral internal locking system (PHILOS) plate fixation provides greater angular stability, works as a locked internal fixator and provides better anchorage of screws in osteoporotic bone, early joint mobilisation and good functional outcome. Considering these advantages and the scarcity of data on the efficacy and the functional outcome following internal fixation with PHILOS plate for displaced proximal humerus fractures, the present study was planned.

Materials and Methods: This study was conducted from October 2014 to October 2016. 30 cases who sustained proximal humerus fractures were enrolled in the study. Through delto-pectoral approach, the fracture site was reduced and fixed with PHILOS plate. Follow up was done at 6 wks, 12 wks and 6 months. Patients were evaluated for 1. Range of motion of the Shoulder. 2. Complications. 3. Clinical union. 4. Radiological union. The final assessment was done using DASH score for outcome.

Results: Excellent outcome was noted in 20%, good in 47%, fair in 26% and poor in 7%. The outcome was independent to side of fracture ($p=0.935$), mode of injury ($p=0.914$) and type of fracture (0.562) as no statistically significant association was noted. 90% patients had clinical and radiological union at three months. The range of motion at first, second and third follow ups showed gradual increase in mean flexion, abduction, external rotation and internal rotation.

Conclusion: PHILOS plate provides a high degree of angular and axial stability eliminating screw loosening and backout. The divergent and convergent orientation of the screws engaging in the humeral head prevent pull out and failure of fixation. The PHILOS plate is an ideal construct and a stable implant to use for fractures of the proximal humerus in Neer's 2-part, 3-part, and 4-part and osteoporotic fractures.

Keywords: Proximal Humerus, Fractures, Plating, PHILOS (proximal humeral interlocking system)

1. Introduction

Fractures of proximal humerus is still unsolved fractures in many ways. Fixation techniques are myriad and none is ideal for all cases [1]. 15% of these fractures are displaced unstable and may have disruption of the blood supply. The treatment of these fractures is therapeutic challenge [2]. The majority of patients with this fracture are elderly, which increases the risk for their bones to be osteoporotic or brittle. A wide variety of treatment modalities have been used in the past. These include transosseous suture fixation, tension band wiring, percutaneous wire, screw fixation, standard plate and screw fixation and hemireplacement arthroplasty. Precontoured locking plates work on the principle of angular stability, less disruption of vascularity and less chances of plate failure [3]. Improved fixation by locking plates are attributed to the angular stability of the screws locking in the plate and their three-dimensional distribution in the humeral head [3]. The Proximal humeral internal locking system (PHILOS) plate fixation provides greater angular stability than do conventional implants. It works as a locked internal fixator and provides better anchorage of screws in osteoporotic bone [4, 5], with good functional outcomes [6, 7]. In proximal humerus fractures, PHILOS plate offers a good functional outcome in context to the early joint mobilisation and rigid fixation of the fracture [8]. Considering these advantages and the scarcity of data on the efficacy and the functional outcome following internal fixation with PHILOS plate for displaced proximal humerus fractures, the present study was planned.

Correspondence
Pandurangaiah Srinivas
Assistant Professor, Department
of Orthopaedics, Sri Devaraj Urs
Medical College, Tamaka, Kolar,
Karnataka, India

2. Materials and methods

This study was conducted during the period from October 2014 to October 2016 including the follow-up period of six months. A total of 30 cases who sustained proximal humerus fractures were enrolled in the study. Inclusion criteria: 1. Patients with 2-, 3- or 4-part proximal humeral fracture. 2. Patients aged greater than 18 years. 3. Patients willing to undergo surgery for treatment of proximal humeral fractures. Exclusion criteria: 1. Type III-C compound fractures. 2. Patients not fit for surgery due to any pre-existing morbidity. Ethical clearance approval for the study was obtained from the Institutional Ethics Committee. Patients fulfilling the selection criteria were informed about the nature of the study. The consent for surgery and anaesthesia were taken. At the arrival of the patient with these fractures a careful history was elicited about age, sex, details of injury, duration. Patients were evaluated for associated medical problems and associated injuries. Patients were subjected to clinical and local examination. Patients were subjected to routine preop investigations. X-ray - Shoulder AP, Lateral and trans-axillary (optional) view were taken. CT scan with 3D reconstruction was done in selected cases. Fracture was stabilized temporarily by POP U-slab and arm sling. Injection tetanus toxoid and antibiotics were given 1 hour prior to the surgery. Brachial block or General anaesthesia was used in all the patients according to their medical condition. The surgery was done in beach chair position. Through delto-pectoral approach, the fracture site was exposed and reduced with minimal soft tissue dissection. The anatomical relationship between humeral head and greater tuberosity was reduced and fixed temporarily with K wires. In case of obvious rotation or displacement of the humeral head, a joystick technique was used. Then the shaft fragment was reduced by abduction, traction and rotation of the arm. The fragments will be indirectly reduced with the help of traction sutures, which are placed in the insertions of rotator cuff tendons, and by extremity rotation. When acceptable reduction was obtained, the PHILOS plate was placed at least 1 cm distal to the upper end of the greater tuberosity and fixed to the humeral shaft. An aiming device was then attached to the upper part of the plate, and the head fragments were secured with Kirschner wires, after image intensifier control. Four to six locking screws were then inserted. All proximal locking screws were placed through an external guide and confirmed to be within the humeral head with intraoperative fluoroscopy. AP (internal and external rotation) views and axillary views 90 degrees to each other were used to visualize screw placement. A minimum of three bicortical screws were used distally. Fluoroscopic images were taken to confirm satisfactory fracture reduction, plate positioning and proper length of screws in the humeral head. Range of motion of shoulder was checked on the table for impingement. After surgery the shoulder was immobilised in an universal shoulder immobiliser. Immediate post operative check radiographs were taken to determine the alignment of the bone and maintenance of reduction. Depending upon the pain, pendulum exercises were begun as soon as possible. Active range of motion was started at 2-4 weeks postoperatively, depending on stability of osteosynthesis. At fourth to sixth week immobilization was discontinued. Active assisted movements started up to 90° abduction with no forced external rotation. At sixth to eighth week-full range of movements with active exercises started. At the end the patients were examined clinically and radiologically, assessed for range of motion and bony union and complications. The

patients with shoulder stiffness were given physiotherapy for 1 to 2 weeks on outpatient basis. Follow-up of patients was done at six weeks, three months and six months following the surgery. For all subjects, radiographs were performed at the end of six weeks, 12 weeks and six months follow-up. Patients were evaluated based on the following parameters at the time of discharge and all the follow ups: 1. Range of motion of the Shoulder. 2. Complications. 3. Clinical union. 4. Radiological union. The final assessment using DASH⁹ score for outcome was interpreted as: Excellent - 0 to 55 points, Good - 56 to 70 points, Fair - 71 to 85 points, Poor - 86 to 100 points.

Statistical analysis: Data obtained was coded and entered into Microsoft Excel spreadsheet. The categorical data was expressed as rate, ratio and percentage. The continuous data was expressed as mean \pm S.D. Fisher's exact test was used to find the association between categorical data. A 'p' value of less than or equal to 0.05 was considered as statistically significant.

3. Results

A total of 30 patients sustained with proximal humerus fractures were studied. Data obtained was analysed and the final results and observations were interpreted as below.

Table 1: Sex distribution

SEX	Number	Percentage
Female	14	46.7
Male	16	53.3
Total	30	100

The male to female ratio was 1.12: 1

Table 2: Age distribution

AGE	Number	Percentage
21-30yrs	7	23.33
31-40yrs	2	6.67
41-50yrs	4	13.33
51-60yrs	7	23.33
>60yrs	10	33.33
Total	30	100

In this study most of the patients presented with age beyond 60 years.

Table 3: Nature of trauma

Nature of trauma	Number	Percentage
RTA	21	70
Fall	9	30
Total	30	100

In the present study 70% of the patients presented with road traffic accident and 30% with history of fall as nature of trauma.

Table 4: Side involved

Side	Number	Percentage
Right	17	56.7
Left	13	43.3
Total	30	100

In this present study 57% of the patients presented with right sided humerus fracture.

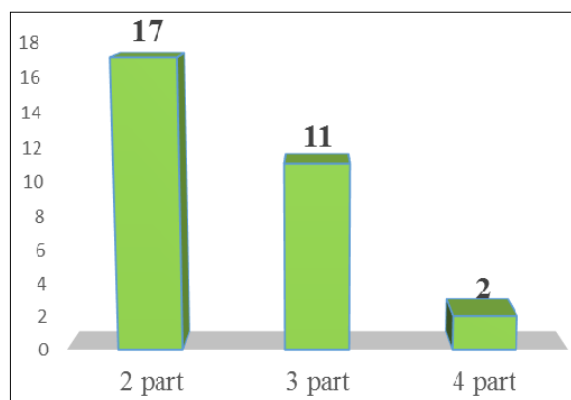
Table 5: Duration of injury

Duration (days)	Number	Percentage
1	21	70
2	6	20
3	3	10
Total	30	100

In the present study, most of the patients (70%) presented with duration of one day following injury.

Table 6: Fracture classification

Neer classification	Number	Percentage
2 part	17	56.7
3 part	11	36.7
4 part	2	6.7
Total	30	100

**Graph 1:** Fracture classification

In this study, 56% of the patients presented with 2-part fracture, 37% with 3-part fracture and 7% with 4-part fracture of the proximal humerus according to Neer's classification.

Table 8: Follow up at 6 weeks (first follow up)

Variables		Number	Percentage
Clinical union	Yes	0	0
	No	30	100
Pain at fracture site	Yes	30	100
	No	0	0
Complications	Yes	0	0
	No	30	100
Radiological union	Yes	2	6.6
	No	28	93.4

In the present study at first follow up at six weeks, pain at fracture site was noted in all the patients (100%) with no clinical union, and radiological union in 6.6%.

Table 9: Follow up at 3 months (second follow up)

Variables		Number	Percentage
Clinical union	Yes	27	90
	No	3	10
Pain at fracture site	Yes	5	16.7
	No	25	83.3
Complications	No	24	80
	Malunion	1	3.3
	Stiffness	4	13.3
	Varus malunion	1	3.3
Radiological union	Yes	27	90
	No	3	10

In this study during second follow up at three months, clinical union was noted in 90% of the patients and radiological union in 90%. Pain at fracture site was reported by 17% of the patients and complications observed were malunion (3%), varus malunion (3%) and stiffness (13%).

Table 10: Follow up at 6 months

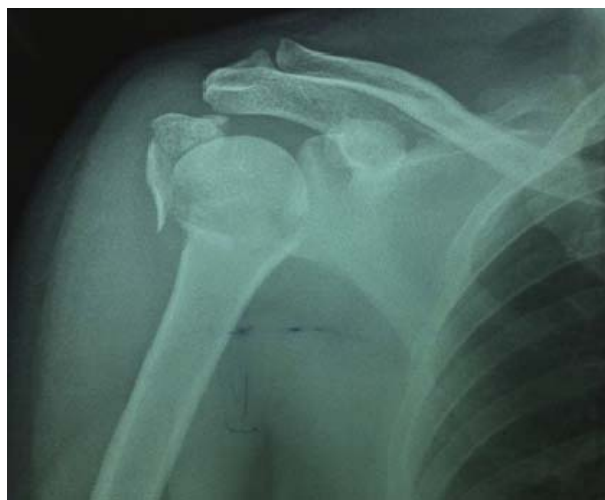Variables		Number	Percentage
Clinical union	Yes	30	100
	No	0	0
Pain at fracture site	Yes	3	10
	No	27	90
Complications	No	24	80
	Malunion	1	3.3
	Stiffness	4	13.3
	Varus malunion	1	3.3
Radiological union	Yes	30	100
	No	0	0

In the present study all the patients (100%) had clinical and radiological union. Pain was reported by 10% of the patients while complications noted were varus malunion (3%), malunion (3%) and stiffness (13%).

Table 11: Range Of Motion

		Mean	SD
Follow up at 6 weeks (First follow up)	Flexion	89.33	15.29
	Abduction	98.3	15.3
	External rotation	38	8.86
	Internal rotation	42	12.14
Follow up at 3 months (Second follow up)	Flexion	98	15.4
	Abduction	105.33	15.69
	External rotation	48.33	9.12
	Internal rotation	51.3	9.3
Follow up at 6 months	Flexion	110	12.86
	Abduction	115.6	16.7
	External rotation	57.3	8.2
	Internal rotation	60.6	12.8

The range of motion at first, second and final follow ups is as depicted in table. It was observed that, there was gradual increase in mean flexion, abduction, external rotation and internal rotation during subsequent follow up.

**Fig 1:** Preop x-ray

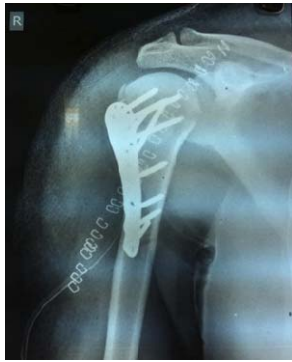

Fig 2: Immediate post op xray

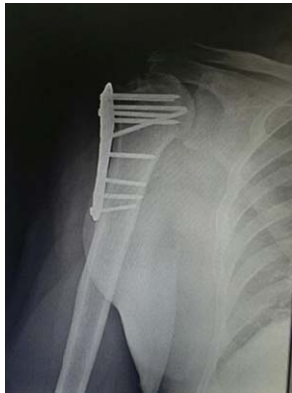

Fig 3: At 6 wks, union in progress

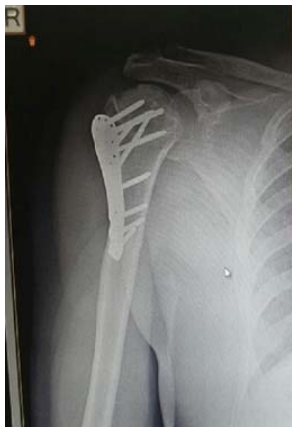

Fig 4: At 6 months, United

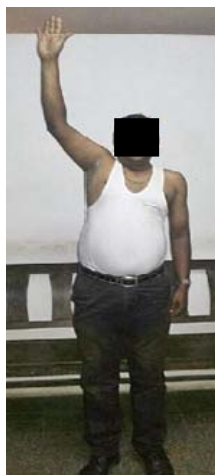

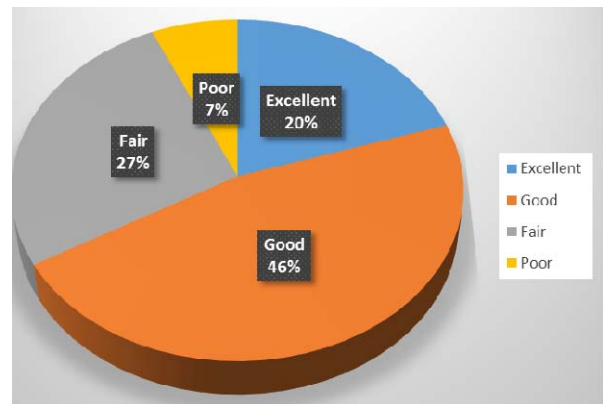
Fig 5: At 6 months abduction



Fig 6: At 6 months, Flexion

Table 12: Final outcome based on dash score

Outcome	Number	Percentage
Excellent	6	20
Good	14	46.67
Fair	8	26.66
Poor	2	6.67



Graph 2: Final outcome based on DASH score

In the present study most of the patients had good outcome (47%) followed by fair (26%), excellent (20%) and poor outcome (7%).

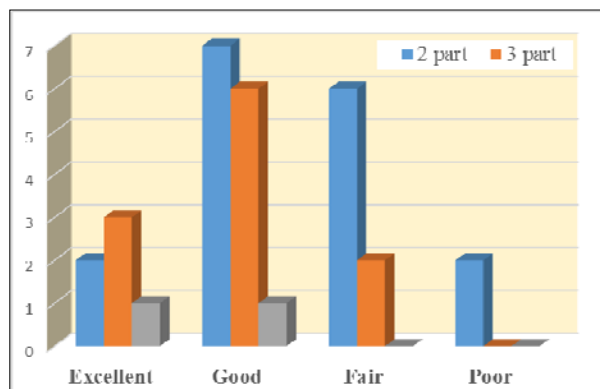
Table 13: Association of outcome with mechanism of injury

Outcome	RTA	FALL	P Value
Excellent	4	2	0.914
Good	10(71%)	4(29%)	
Fair	6	2	
Poor	1	1	

In this study of the 14 patients with good outcome, RTA was the mechanism of injury in 71% compared to fall in 29% and the difference was statistically not significant ($p=0.914$)

Table 15: Association of outcome with type of fracture

Outcome	2 part	3 part	4 part	P Value
Excellent	2	3	1	0.562
Good	7	6	1	
Fair	6	2	0	
Poor	2	0	0	

**Graph 3:** Association of outcome with type of fracture

In this study no statistically significant association was observed between outcome and type of fracture ($p=0.562$).

4. Discussion

Open reduction and internal fixation (ORIF) provides the features of anatomical fracture reduction, rigid fixation and the possibility of bone grafting. In proximal humerus fractures, PHILOS plate offers good functional outcome with context to the early joint mobilisation and rigid fixation of the fracture. The present study was undertaken to assess the efficacy and the functional outcome following internal fixation with PHILOS (proximal humeral internal locking system) plate for displaced proximal humerus fractures. The present two year prospective study was conducted from October 2014 to October 2016. A total of 30 patients who sustained proximal humerus fracture were enrolled. Patients underwent open reduction and internal fixation using PHILOS plate through deltopectoral approach. In this study, patients with only 2-part, 3-part & 4-part fracture of proximal humerus were included based on Neer's classification. Accordingly, the 2-part fractures were noted in most of the cases (57%) followed by 3-part (38%) and 4-part (7%). Kristiansen and Christensen^[10] have reported a high incidence of fixation failure following use of T-buttress plates in fixation of proximal humerus fractures. Wiggman *et al.*^[11] have reported good intermediate and long-term results in 87% of patients who had three-and four-part fractures fixed with T-buttress plate. Recently newer implants such as the Plan Tan humerus fixator plate, Polaris nail and the PHILOS plate have been used for fixation of proximal humerus fractures. The plate is pre-shaped and contoured for the proximal humerus. The benefits of this implant are that it gives enhanced purchase in osteopenic bone, there is no loss of reduction or varus/valgus angulations, the locking screws into the plate provide angular and axial stability of the construct. With regard to functional outcome following use of locking plates (PHILOS) early benefits can be gained. The other demanding aspect is to avoid placing the plate too proximally on the humerus with resulting impingement of the top of the plate on the acromion. This can be avoided by using a K wire inserted through a hole at the top of the plate, which should line up with the tip of the greater tuberosity. This is done during initial positioning of

the plate. Positioning the plate too high can also lead to incorrect placement of the divergent screws in the humeral head. Care should be taken to avoid penetration of the head and subsequent chondrolysis with proximal interlocking screws^[12].

In the present study open reduction and internal fixation through deltopectoral approach with PHILOS plate was carried out and nearly half of the study population had good outcome (47%). Among the others, fair and poor outcomes were noted in 26% and 7% while excellent outcome was noted in 20% of the patients. The outcome was independent to side of fracture, mode of injury and type of fracture as no statistically significant association was noted between side of fracture ($p=0.935$), mode of injury ($p=0.914$), type of fracture (0.562) and outcome. Majority of the patients had clinical (90%) and radiological union (90%) during second follow up at three months. The range of motion at first, second and third follow ups showed gradual increase in mean flexion, abduction, external rotation and internal rotation during subsequent follow ups. These findings suggest that internal fixation with PHILOS (proximal humeral internal locking system) plate for displaced proximal humerus fractures results in overall good results that is nearly 67% of the patients had excellent and good results.

Esser^[13] reported excellent results in 22 out of his 26 patients of three part and four part fractures of proximal humerus treated with a modified clover leaf plate. Paavola *et al.*^[14] reported satisfactory results in 74.2% of their 41 patients with severe proximal humerus fractures treated with plate and screw devices. However all these authors found poor results in 4 part fractures and recommended a prosthetic replacement in such patients. In a study Koukakis A *et al.*^[15] prospectively evaluated 20 patients with fractures of the proximal humerus. According to their experience, the plate design provides stable fixation with a good functional outcome and eliminates most hardware problems such as failure and impingement syndrome. In 2009 MA Fazal *et al.*^[16] retrospectively reviewed 27 patients who underwent locking compression plate fixation. The Constant shoulder Score was > 75 in 11 patients, 13 were scored between 50 to 75, and 3 below 50. They concluded PHILOS plate fixation provided stable fixation, minimal metal work problem and enabled early range of motion exercises to achieve acceptable functional results. Egol KA *et al.*^[17] in his retrospective analysis studied early complications in proximal humerus fractures treated with locked plates in 51 consecutive patients. Radiographically, 92% of the cases united at 3 months after surgery, and 2 fractures had signs of osteonecrosis at latest follow-up. The major complication reported in this study was screw penetration, suggesting that exceptional vigilance must be taken in estimating the appropriate number and length of screws used to prevent articular penetration. In 2009 Brunner F *et al.*^[18] in his multicenter study from 8 trauma units enrolled 157 patients and treated with open reduction and internal fixation with a Philos plate. The incidence of experiencing any implant-related complication was 9% and 35% for non implant related complications. Primary screw perforation was the most frequent problem (14%) followed by secondary screw perforation (8%) and avascular necrosis (8%). After 1 year, a mean Constant score of 72 points (87% of the contralateral noninjured side), a mean Neer's score of 76 points, and mean Disabilities of the Arm, Shoulder, and Hand score of 16 points were achieved. They concluded that fixation with Philos plates preserves achieved reduction, and a good functional outcome can be expected.

Proximal humerus fractures, remain a challenging problem for the surgeon because the complication rate for these fractures still remains high. The internal locked system (PHILOS) plate is a new device used for proximal humerus fracture fixation is designed to decrease the high complication rate. In the present study at second follow up complications observed were varus malunion (3.3%), malunion (3.3%) and stiffness (13.3%) and during third follow up varus malunion (3.3%), malunion (3.3%) and stiffness (13.3%).

5. Conclusion

Philos plate has threads in its holes, which locks with the threads of its screw heads. This provides a high degree of angular and axial stability eliminating screw loosening and backout. The divergent and convergent orientation of the screws engaging in the humeral head prevent pull out and failure of fixation. Early physiotherapy and good rehabilitation programme is vital to get a good functional outcome. In conclusion, the PHILOS plate is an ideal construct and a stable implant to use for fractures of the proximal humerus in Neer's 2-part, 3-part, and 4-part and osteoporotic fractures of the proximal humerus in elderly patients hence allowing early mobilisation of the shoulder.

6. References

- Gerald RW, Kirk Wong L. Two-part and three part fractures - Management of proximal and distal humerus fracture. *Orthop Clin North Am.* 2000; 1:1-21.
- Lous Bigiliani U, Charles Rockwood, Frederick A. Fractures of proximal humerus. Chapter 9 The shoulder. In Rockwood CA, Matsen. Philadelphia: W.B. Saunders, 1990; 1:278-334.
- Kumar C, Gupta AK, Nath R, Ahmad J. Open reduction and locking plate fixation of displaced proximal humerus fractures. *Indian J Orthop.* 2013; 47(2):156-60.
- Gautier E, Sommer C. Guidelines for the clinical application of the LCP. *Injury.* 2003; 34(2):B63-76.
- Helmy N, Hintermann B. New trends in the treatment of proximal humerus fractures. *Clin Orthop Relat Res.* 2006; 442:100-8.
- Koukakis A, Apostolou CD, Taneja T, Korres DS, Amini A. Fixation of proximal humerus fractures using the PHILOS plate: early experience. *Clin Orthop Relat Res.* 2006; 442:115-20.
- Bjorkenheim JM, Pajarinen J, Savolainen V. Internal fixation of proximal humeral fractures with a locking compression plate: a retrospective evaluation of 72 patients followed for a minimum of 1 year. *Acta Orthop Scand.* 2004; 75:741-5.
- Kiliç B, Uysal M, Cinar BM, Ozkoç G, Demirörs H, Akpınar S. Early results of treatment of proximal humerus fractures with the PHILOS locking plate. *Acta Orthop Traumatol Turc.* 2008; 42(3):149-53.
- Hudak PL, Amadio PC, Bombardier C. Development of an upper extremity outcome measure: the DASH (disabilities of the arm, shoulder and hand) [corrected]. The Upper Extremity Collaborative Group (UECG). *Am J Ind Med* 1996; 29(6):602-8. Erratum in: *Am J Ind Med* 1996; 30(3):372.
- Kristiansen B, Christensen SW. Plate fixation of proximal humeral fractures. *Acta Orthop Scand.* 1986; 57:320-3.
- Wijgman AJ, Roolker W, Patt TW, Raaymakers EL, Marti RK. Open reduction and internal fixation of three and four part fractures of the proximal part of the humerus. *J Bone Joint Surg Am.* 2002; 84:1919-25.
- Thyagarajan DS, Haridas SJ, Jones D, Dent C, Evans R, Williams R. Functional outcome following proximal humeral interlocking system plating for displaced proximal humeral fractures. *Int J Shoulder Surg.* 2009; 3(3):57-62.
- Esser RD. Treatment of three and four part fractures of the proximal humerus with a modified cloverleaf plate. *J Orthop Trauma.* 1994; 788-91.
- Paavolainen P, Bjorkenheim JM, Slati P, Pauku P. Operative treatment of severe proximal humeral fractures. *Acta Orthop Scand.* 1983; 54:374-9.
- Koukakis A, Apostolou CD, Taneja T, Korres DS, Amini A. Fixation of proximal humerus fractures using the PHILOS plate: early experience. *Clin Orthop Relat Res.* 2006; 442:115-20.
- Fazal MA, Haddad FS. PHILOS plate fixation for displaced proximal humeral fractures. *J Orth Surg.* 2009; 17(1):15-8.
- Egol KA, Ong CC, Walsh M, Jazrawi LM, Tejawani NC, Zuckerman JD. Early complication of proximal humerus fractures treated with locked plates, *J orthop trauma.* 2008; 22:159-64.
- Brunner F, Sommer C, Bahrs C, Heuwinkel R, Hafner C, Rillmann P *et al.* Open Reduction and Internal Fixation of Proximal Humerus Fractures Using a Proximal Humeral Locked Plate: A Prospective Multicenter Analysis. *J Orthop Trauma.* 2009; 23:163-72.