

Case Report

Fournier's Gangrene of the Penis

Mohd Kashif Imran, Krishna Prasad, Amal Abraham, Praveen GP, Dinesh Kumar Sathanantham* and Mohd Kashif Imran

Department of General Surgery, Sri Devaraj Urs Medical College, India

*Corresponding author

Dinesh Kumar Sathanantham, Department of General Surgery, Sri Devaraj Urs Medical College, Tamaka, Kolar, Karnataka, India, Email: dinesh.sathanantham@gmail.com

Submitted: 22 June 2017

Accepted: 17 August 2017

Published: 19 August 2017

Copyright © 2017 Sathanantham et al.

ISSN: 2373-9819

OPEN ACCESS

Abstract

Fournier's gangrene is an uncommon rare, debilitating and fulminant condition of infective origin which is characterized by sudden scrotal edema with rapid onset of gangrene leading to exposure of the scrotal contents. It is usually a localized disease of the scrotum and penis, with an occasional extension up to the abdominal wall. The usual organism is an anaerobic *streptococcus* synergistic with other organisms. A 65-year-old male presented with fever and pain and a brownish-black discoloration of the penis, of 8 days and difficulty in passing urine and dribbling of urine from mid shaft of the penis. Our case is rare as just penis was involved, without the involvement of scrotum which is very rare. The management of the present condition involves hospitalization, early debridement of the entire shaft of the penis distal to the devastated area, without excising the normal skin, parenteral broad-spectrum antibiotics, and skin grafting.

Keywords

- Anaerobes
- Antibiotics
- Debridement
- Fournier's gangrene
- Penis
- Scrotum
- Gangrene
- Cellulitis

INTRODUCTION

Fournier gangrene was first identified in 1883, when the French venereologist Jean Alfred Fournier described a series in which 4 previously healthy young men suffered from a rapidly progressive gangrene of the penis and scrotum without apparent cause [1,2]. There has been a report made by baurienne in 1794, describing the disease in a very early period before Fournier which is quite mentionable [3].

In his presentation, Fournier reviews the systemic and local factors that influence this fulminative process. Local factors related to the trauma of the genitalia accounted for a vast majority of the cases of genital gangrene. Although Fournier has not emphasized the role of diabetes in this article, diabetes was known as the leading predisposing systemic factor [1]. Trauma to the genitalia continues to be a frequently recognized vector for the introduction of bacteria that initiate the infectious process [4].

The management of the present condition involves hospitalization, early debridement of the entire shaft of the penis distal to the devastated area, without excising the normal skin, parenteral broad-spectrum antibiotics, and skin grafting. Here we present is a rare case of Fournier gangrene of isolated penile skin.

CASE REPORT

A 66 year-old-male patient presented with fever and pain, with brownish black discolouration of the penis (Figure 1) for 8 days and difficulty in passing urine since 2 days. Initially started with redness and pain over the penile region, the lesions started

spontaneously without any history of trauma or any sepsis in the genitoperineal area. On general physical examination, the patient was febrile. Local examination revealed brownish-black discoloration of the penile skin extending up to the penoscrotal junction with clear line of demarcation [Figure 2]. Multiple blackish patches were seen over the dorsum of the penis with largest measuring about 2.5cm x 3cm which, penis was diffusely edematous. There were no other foci of infection in the genitor perineal area there was no palpable inguinal lymph nodes. There was grade I prostatomegaly on per rectal examination. Routine hematological examination revealed leucocytosis and neutrophilia. Urine microscopy revealed no abnormality. Random

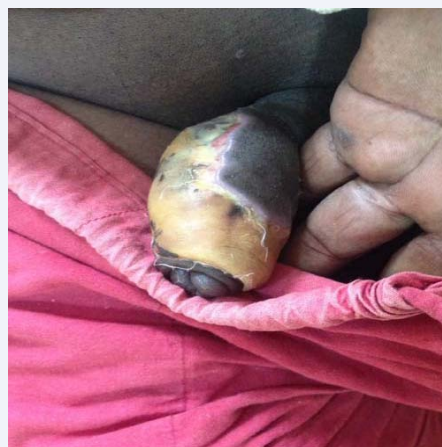


Figure 1 Brownish-black discolouration of the penis.

blood sugar was 246mg/dl, blood urea, and serum creatinine was within normal limits. The ultrasonological examination of the abdomen and pelvis was normal. Other imaging modalities could not be performed due to the lack of financial stability of the patient. Supra pubic catheterization was done, for urinary retention, followed by which patient was taken for emergency wound debridement. Per operatively, the gangrene was limited to distal 1/3rd of the penis with full necrosis of the foreskin but the underlying glans appears to be normal. Post-operative image is shown in Figure 2.

Discharge sent for culture isolated a mixed growth of *Bacteroides fragilis*, *Bacteroides fragilis* and anaerobic streptococcus sensitive to cefotaxime, ceftriaxone, amoxicillin/ clavulonic acid and amikacin.

The patient was hospitalized and broad spectrum antibiotics including piperacillin, tazobactam and metronidazole were administered parenterally. Emergency debridement and dressings the bed was finally healthy (Figure 3), and an unexpanded, meshed, split-thickness skin graft was performed, by placing the graft junction on the ventral surface of the penis [6]. The graft dressing was changed on the fourth and sixth postoperative days, and it revealed a 100% take of the graft. The postoperative period was uneventful. Follow up after 3 months showed good healing of the wound.

DISCUSSION

Fournier's gangrene is described as a rare, fulminant, and usually localized disease of the scrotum and penis, with occasional extension up to the abdominal wall. The usual organism is an anaerobic streptococcus synergistic with other organism like enterobacteria species, staphylococcal species, anerobic organisms and fungi [4]. Rarity in our case is involvement of the gangrene to the penile skin alone, with no extension to scrotum or abdominal wall is the characteristic feature in our case. Early therapy is the key, including hospitalization, debridement of the entire shaft of the penis distal to the devastated area without excising the normal skin, parenteral broad-spectrum antibiotics and skin grafting. Only few cases of Fournier's gangrene of the penis have been reported.

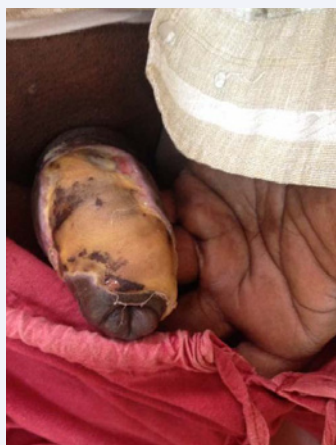

Figure 2 Discolouration of the penis with vesicles filled with hemorrhagic fluid.

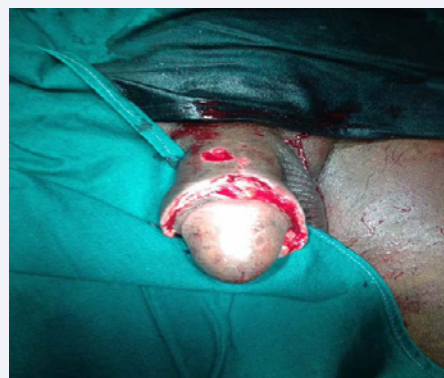

Figure 3 Penile skin Post-Debridement.

Infection represents an imbalance in host immunity, which is frequently compromised by one or more of the above-mentioned co-morbid systemic processes and the virulence of the causative microorganisms. In our case the diabetic being the predisposing factor leading to immuno-compromisation leading to the disease. The aetiological factors allow the portal for entry of the microorganism into the perineum. The compromised immunity provides a favorable environment to initiate the infection and the virulence of the microorganism promotes the rapid spread of the disease [4].

The following are the common causative microorganisms:

Streptococcal species, staphylococcal species, enterobacteriaceae species, anaerobic organisms and fungi. Most authorities believe the polymicrobial nature of this disease is necessary to create the synergy of enzyme production that promotes rapid multiplication and spread of the infection. For example, one microorganism might produce the enzymes necessary to cause coagulation of the nutrient vessels. Thrombosis of these nutrient vessels reduces local blood supply; thus, the tissue oxygen tension falls. The resultant tissue hypoxia allows growth of facultative anaerobes and microaerophilic organisms. The latter microorganisms, in turn, may produce enzymes (e.g., lecithinase, collagenase), which lead to the digestion of fascial barriers, thus fueling the rapid extension of the infection. Fascial necrosis and digestion are the hallmarks of this disease process; this is important to appreciate because it provides the surgeon with a clinical marker of the extent of tissue involvement. Specifically, if the fascial plane can be separated easily from the surrounding tissue by blunt dissection, it is quite likely to be involved with the ischemic-infectious process; therefore, any such dissected tissue should be excised. Far-advanced or fulminant disease can spread from the fascial envelopment of the genitalia throughout the perineum, along the torso, and occasionally, into the thighs.

- The hallmark of Fournier's gangrene is intense pain and tenderness in the genitalia [7]. The clinical course usually progresses through the following phases: Prodromal symptoms of fever and lethargy, which may be present for two to seven days
- Intense genital pain and tenderness that is usually associated with edema of the overlying skin

- c. Increasing genital pain and tenderness with progressive erythema of the overlying skin
- d. Dusky appearance of the overlying skin; subcutaneous crepitation
- e. Obvious gangrene of a portion of the genitalia; purulent drainage from the wounds

The systemic effects of this process vary from local tenderness with no toxicity to florid septic shock. In general, the greater the degree of necrosis the more profound the systemic effects. The typical patient would be an elderly male in his sixth or seventh decade of life with comorbid diseases; females are not immune to this disease, but are affected less frequently. The characteristic histological finding that most commonly indicates Fournier's disease is fibrinoid thrombosis of the nutrient vessels that supply the superficial and deep fascia. A frequent occurrence is a widespread necrosis of the fascia with acute inflammatory cell infiltration, necrotic debris and frequent demonstration of causative microorganisms within the tissues. This extensive inflammatory process is often present deep in the intact skin, which is often minimally involved with the inflammatory process until late in the disease. Diagnosis in most cases is clinical, ultrasonography and CT can aid in the earlier diagnosis of Fournier's gangrene and give us vast information regarding the extent of the disease [8]. Treatment also involves the institution of broad-spectrum antibiotic therapy. The antibiotic spectrum should cover staphylococci, streptococci, the Enterobacteriaceae family of organisms and anaerobes. A reasonable empiric regimen might consist of ciprofloxacin and clindamycin. Clindamycin is particularly useful in the treatment of necrotizing soft tissue infections, due to its gram-positive and anaerobic spectrum of activity. Clindamycin has been shown, in animal models of streptococcal infection, to have superior response rates compared to penicillin or erythromycin, even though the treatment is delayed [6,7,9]. If the initial tissue stains show fungi, an empiric antifungal agent such as amphotericin B is added. In cases associated with the sepsis syndrome, therapy with intravenous immunoglobulin (IVIG), which

is thought to neutralize super antigens such as the streptotoxins (A,B) believed to mitigate the exaggerated cytokine response, has been shown to be a good adjuvant to appropriate antibiotic coverage and complete surgical debridement [10].

CONCLUSION

Only few cases of Fournier's gangrene of the penis have been reported so far. This case is reported because of its rarity and a rapid confirmation of diagnosis with starting of treatment will sure limitation of the disease spread and containment of the infection, promising a better prognosis.

REFERENCES

1. Fournier JA: Gangrène foudroyante de la verge. in La Semaine Médicale N°50. 345-347.
2. Vernon M Pais, Jr Fournier Gangrene.
3. Vaz I. Trop Doct. 2006; 36:203-204.
4. Basoglu M, Gul O, Yildiran I, Balik AA, Ozbey I, Oren D. Fournier's gangrene: Review of fifteen cases. Am Surg. 1997; 63:1019-1021.
5. Ashutosh Talwar, Neerja Puri, Majhail Singh. Fournier's Gangrene of the Penis: A Rare Entity. J Cutan Aesthet Surg. 2010; 41-44.
6. Yumura Y, Chiba K, Saito K, Hirokawa M. Fournier's gangrene of penis in a patient with malignant lymphoma: A case report. Hinyokika Kiyo. 2000; 46: 735-737.
7. Efem SE. The features and aetiology of Fournier's gangrene. Postgrad Med J. 1994; 70: 568-571.
8. Erika Kube, Stanislaw P Stawicki, David P Bahner. Ultrasound in the diagnosis of Fournier's gangrene. Int J Crit Illn Inj Sci. 2012; 2: 104-106.
9. Frydenberg M. Penile gangrene: A separate entity from Fournier's syndrome? Br J Urol. 1998; 61: 523-523.
10. Panagea S, Perry JD, Gould FK. Should clindamycin be used as treatment of patients with infections caused by erythromycin-resistant staphylococci? J Antimicrob Chemother. 1999; 44: 581-582.

Cite this article

Imran MK, Prasad K, Abraham A, Praveen GP, Sathanantham DK, et al. (2017) Fournier's Gangrene of the Penis. JSM Clin Case Rep 5(2): 1132.