

A Rare Case of Nodular Fasciitis of Hand – Case Study and Review of Literature



Medical Science

KEYWORDS : Nodular fasciitis, Pseudosarcomatous fasciitis, Proliferative fasciitis, Parosteal fasciitis.

KRISHNA PRASAD K

**KARTHIK HAREEN
TVK**

PRAVEEN GP

AMAL ABRAHAM

ABSTRACT

Introduction:

Nodular fasciitis is a rapidly growing benign, self-limiting, reactive lesion, which due to clinical findings and pathologic appearance can be mistaken for a soft tissue sarcoma. Although nodular fasciitis can occur virtually anywhere in the body, it is commonly found in the volar aspect of the forearm, next in frequency is the chest wall and back, followed by the neck and head. This disorder is extremely rare in the hand. A large series of nodular fasciitis showed only 0%–2% of occurrences in the hand.

Case report:

A 35 year old male patient presented with complaints of swelling in the left palm since 6 weeks. Swelling was initially of the size of 1x1 cm and has progressed to the current size of 3x2 cm and was associated with pain. There was no history of any trauma or similar complaints in the past. On physical examination, a painful mass measuring 3x2 cm in diameter was observed in the left palm below the index and the middle fingers. The swelling was non-mobile, firm in consistency and non-tender upon palpation with a smooth surface and clear margins. Excision was done and specimen was sent for histo-pathological examination. Histo-pathological report showed features of Nodular Fasciitis. Post-operative period was uneventful.

Conclusion:

Nodular fasciitis is a self-limiting benign reactive fibroblastic growth and often mistaken for malignant neoplasm with its features of rapid growth and histological appearance. This is a rare benign condition for which treatment is limited to surgical excision. This is generally curative and relapses are rare.

INTRODUCTION:

Nodular fasciitis is a rapidly growing benign, self-limiting, reactive lesion, which due to clinical findings and pathologic appearance can be mistaken for a soft tissue sarcoma. This lesion is commonly found in the forearm and is extremely rare in the hand. The precise cause of nodular fasciitis is unknown, but despite a benign clinical behavior injury or infection is possible.

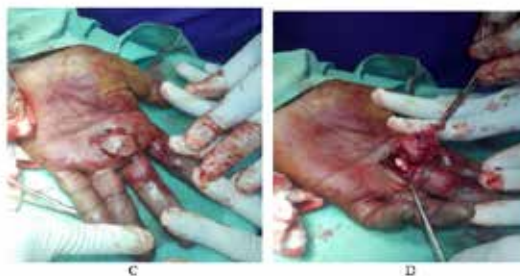CASE REPORT:

A 35 year old male patient presented with complaints of swelling in the left palm for 6 weeks. Swelling was initially of the size of 1x1 cm and has progressed to the current size of 3x2 cm and was associated with pain. There was no history of any trauma or similar swellings in the past.

On physical examination, a non-tender swelling measuring 3x2 cm in diameter was observed in the left palm below the index and the middle fingers. The swelling was immobile, firm in consistency with a smooth surface and clear margins. Clinical diagnosis of dermoid cyst was entertained.

Fine needle aspiration cytology of the swelling was done and report was suggestive of dermoid cyst.

Excision was done under wrist block and specimen was sent for histo-pathological examination.



During the procedure – EXCISION - C to F

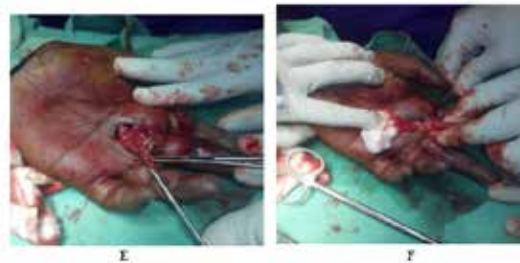
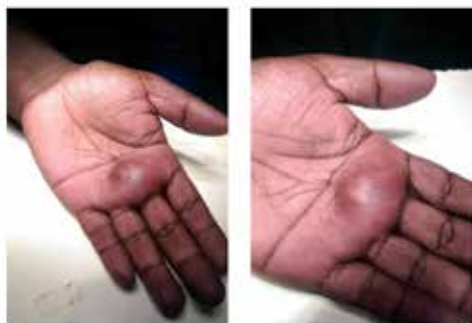
Fig A and B – Swelling present in the palmar surface of left hand

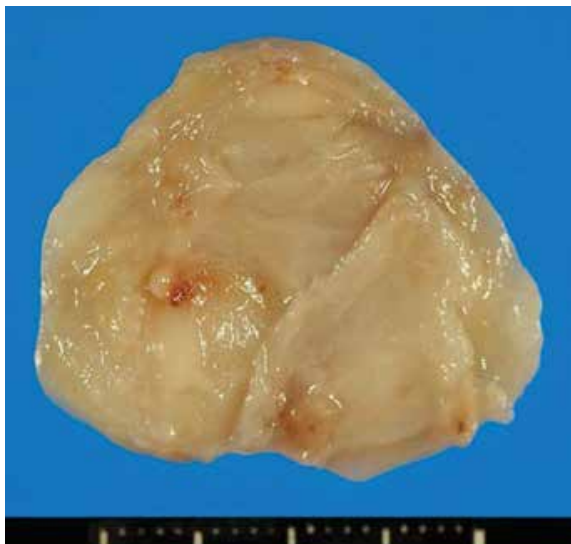

Fig G – Excised Specimen

Histo-pathological report showed features of Nodular Fasciitis. Post-operative period was uneventful.

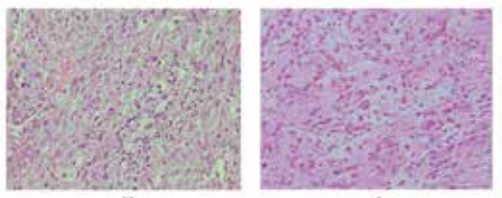


Fig H - The specimen shows vascular hyperplasia and infiltration of inflammatory cells.

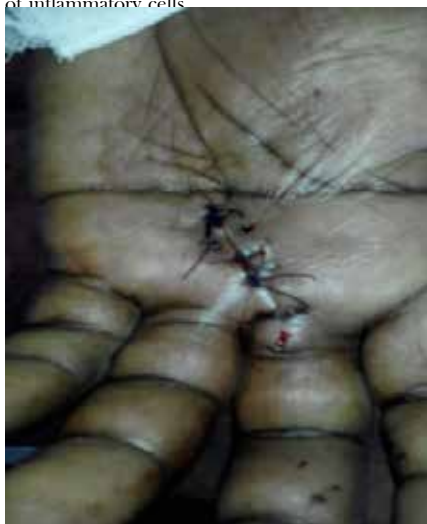

Fig J – Sutured Wound on post-operative day 3.

The patient was followed up for a period of 6 months. There were no signs of recurrence.

DISCUSSION:

Nodular fasciitis is a benign reactive lesion first reported by Konwaler et al. in 1955 as a subcutaneous pseudosarcomatous fibromatosis¹. It is a rapidly growing mass occurring in all age groups but most often in young adults between 20 and 40 years of age, but with no racial or gender predilection. It is usually subcutaneous, although occasional cases involve muscle and fascia.

In about 10%–50% of patients there is associated pain or tenderness^{2,3}. Although nodular fasciitis can occur virtually anywhere in the body, it is commonly found in the volar aspect of the forearm, next in frequency is the chest wall and back, followed by the neck and head^{2,4}. This disorder is less common in the hand. A large series of nodular fasciitis showed only 1%–2% of occurrences in the

hand^{2,4,5}. Since Brimhall et al. first made a detailed case report of nodular fasciitis of the hand in 1989⁶, only 14 cases (including the current case) have been reported in the English literature.

The macroscopic appearance of nodular fasciitis is solitary round to oval nodules, well circumscribed and usually measuring less than 2 cm in diameter. Only 8% are larger than 4 cm². It is often initially misdiagnosed as sarcoma because of its rapidly growing nature of 1 month or less in duration. The etiology of nodular fasciitis remains unclear, but it is considered to be a self-limiting reactive lesion and not a true neoplasm as some cases have occurred after trauma or infection. Bernstein and Lattes described a recognized history of trauma in 5 of 134 cases². Although the number of patients with trauma was low, they described the possibility of minor trauma causing this reactive disorder. Nodular fasciitis of the hand seems to have a close association with trauma compared to other locations.

The features of nodular fasciitis on MR imaging are non-specific. The lesions appear as well circumscribed, round to oval mass⁷. Literature descriptions of the signal intensity of the condition, including the contrast enhancement pattern, vary^{7–11}. On MRI, intramuscular lesions appear mildly homogeneous and hyperintense to skeletal muscle on T1-weighted spin-echo images; whereas on T2-weighted spin-echo images, the lesions are relatively homogeneous with hyperintense signal to subcutaneous fat.

Subcutaneous lesions, typically more fibrous than intramuscular lesions, are markedly hypointense to skeletal muscle on all spin-echo sequences and appear homogeneous in texture^{7,10–12}. High cellularity and micro-vessel density may directly influence the early enhancement after intravenous gadolinium injection and compact cellularity with a prominent capillary network. A myxoid pattern may be responsible for the enhancement on MRI¹².

Kessels et al. reported that nodular fasciitis was detected by positron emission tomography with 18F-fluorodeoxyglucose (18-FDG-PET)¹³. However when thallium-201 scintigraphy or 18-FDG-PET shows a high uptake similar to sarcoma, nodular fasciitis should be included in the differential diagnosis. Histologically, the lesion is composed of regular spindle-shaped fibroblasts or myofibroblasts lacking nuclear hyperchromasia and pleomorphism.

The lesion may be highly cellular. Although mitotic figures are fairly common, atypical mitoses are almost never seen. Five important histologic features of

nodular fasciitis which aid in diagnosis include spindle shaped fibroblasts, clefts separating the fibroblasts, extravasated erythrocytes, interstitial mucoid material and a loosely textured 'feathery' pattern of the mucopolysaccharide ground substance³. Immunostains for vimentin and alpha-SMA are usually positive, but desmin, cytokeratin and S-100 are typically negative. Because of common misdiagnosis, incisional or excisional biopsy is usually required for a definitive diagnosis. Montgomery and Meis verified that correct tissue diagnosis of nodular fasciitis was made in fewer than 50% of cases submitted to the Armed Forces Institute of Pathology¹⁴.

Plaza et al. reported that nodular fasciitis remained a difficult diagnosis by fine-needle aspiration cytology (FNAC), particularly when it occurred in locations such as the hand¹⁵. Careful histological examination is important to avoid radical surgery. We recommend excisional or incisional biopsy, and a permanent histological sec-

tion, including immune-histochemical study to confirm the diagnosis.

Most lesions are effectively treated by local excision, as reflected by a recurrence rate of 1% to 2%^{2,4,16,17}. Recurrence soon after excision has been associated with incomplete excision of the lesion⁷. The current report documents a rare case of nodular fasciitis in the hand. Sufficient knowledge and awareness is always required for the proper management of the case.

REFERENCES:

1. Konwaler BE, Keasbey L, Kaplan L. Subcutaneous pseudosarcomatous fibromatosis (fasciitis). *Am J Clin Pathol.* 1955; 25:241–52.
2. Bernstein KE, Lattes R. Nodular (pseudosarcomatous) fasciitis, a nonrecurrent lesion: clinicopathologic study of 134 cases. *Cancer.* 1982;49:1668–78.
3. Rankin G, Kushner SH, Gellman H. Nodular fasciitis: a rapidly growing tumor of the hand. *J Hand Surg Am.* 1991;16A:791–5.
4. Shimizu S, Hashimoto H and Enjoji M. Nodular fasciitis: an analysis of 250 patients. *Pathology.* 1984;16:161–6.
5. Kijima H, Okada K, Ito H, Shimada Y, Nanjo H, Itoi E. Nodular fasciitis of the finger. *Skeletal Radiol.* 2005;34:121–3.
6. Brimhall CL, Segura AD, McTigue MK, Esterly NB. Nodular fasciitis on the palm of a child. *Arch Dermatol.* 1989;125: 1441–2.
7. Katz MA, Beredjiklian PK, Wirganowicz PZ. Nodular fasciitis of the hand. *Clin Orthop Relat Res.* 2001;382:108–11.
8. Frei S, de Lange EE, Fechner RE. Case report 690. Nodular fasciitis of the elbow. *Skeletal Radiol.* 1991;20:468–71.
9. Hymas DC, Mamalis N, Pratt DV, Scott MH, Anderson RL, Langer PD. Nodular fasciitis of the lower eyelid in a pediatric patient. *Ophthal Plast Reconstr Surg.* 1999;15:139–42.
10. Leung LY, Shu SJ, Chan AC, Chan MK, Chan CH. Nodular fasciitis: MRI appearance and literature review. *Skeletal Radiol.* 2002;31:9–13.
11. Meyer CA, Kransdorf MJ, Jelinek JS, Moser RP Jr. MR and CT appearance of nodular fasciitis. *J Comput Assist Tomogr.* 1991;15:276–9.
12. Wang XL, De Schepper AM, Vanhoenacker F, De Raeye H, Gielen J, Aparisi F, et al. Nodular fasciitis: correlation of MRI findings and histopathology. *Skeletal Radiol.* 2002;31:155–61.
13. Kessels LW, Simsek S, Van Hattum AH, Stam F, Comans EF. Nodular fasciitis: an unexpected finding on computed tomography and positron emission tomography. *Eur J Intern Med.* 2004;15:183–5.
14. Montgomery EA, Meis JM. Nodular fasciitis. Its morphologic spectrum and immunohistochemical profile. *Am J Surg Pathol.* 1991;15:942–8.
15. Plaza JA, Mayerson J, Wakely PE Jr. Nodular fasciitis of the hand: a potential diagnostic pitfall in fine-needle aspiration cytopathology. *Am J Clin Pathol.* 2005;123:388–93.
16. Evans HL, Bridge JA. Nodular fasciitis. In: Fletcher CD, Unni KK, Mertens F, editors. *Pathology & Genetics Tumours of Soft Tissue and Bone.* Lyon: IARC; 2002. p. 48–9.
17. Weiss SW, Goldblum JR. *Enzinger and Weiss's Soft Tissue Tumors.* 5th ed. St. Louis: Mosby; 2007. p. 177–89.
18. Donner LR, Silva T, Dobin SM. Clonal rearrangement of 15p11.2, 16p11.2, and 16p13.3 in a case of nodular fasciitis: additional evidence favoring nodular fasciitis as a benign neoplasm and not a reactive tumefaction. *Cancer Genet Cytogenet.* 2002;139:138–40.
19. Bau JL, Ly JQ, Lusk JD. Quiz case. Nodular fasciitis. *Eur J Radiol.* 2003;47:54–6.
20. Singh R, Sharma AK, Sen R. Nodular fasciitis of the thumb: a case report. *Hand Surg.* 2004;9:117–20.
21. Ikeda K, Hagiwara N, Funaki K, Tomita K, Sudo Y. Nodular fasciitis of the ulnar nerve at the palm. *Scand J Plast Reconstr Surg Hand Surg.* 2005;39:249–51.
22. Sailon AM, Cappuccino G, Hameed M, Fleegler EJ. Nodular fasciitis of the hand over the metacarpophalangeal joint: a case report. *Eplasty.* 2008;24:383–7. 296 H. Hara et al.