

# Significance of Morphometric Evaluation of Pre-Malignant and Malignant Lesions of Uterine Cervix: A Cross-sectional Analytical Study

HAJRA K MEHDI<sup>1</sup>, KALYANI RAJU<sup>2</sup>, SR SHEELA<sup>3</sup>

## ABSTRACT

**Introduction:** Morphometric analysis of various parameters of the cells is done to classify the lesion as benign or malignant. It is an objective assessment which reduces the variability due to subjective visual assessment. Authors have done the nuclear morphometric analysis in ectocervix and endocervix tissue sections.

**Aim:** To evaluate the significance and utility of nuclear morphometry in pre-malignant and malignant lesions of uterine cervix.

**Materials and Methods:** This was a retrospective cross-sectional study done on 120 cases of cervix which were categorised histomorphologically into normal ectocervix, chronic cervicitis, Low-Grade Squamous Intraepithelial Lesion (LSIL), High-Grade Squamous Intraepithelial Lesion (HSIL), Squamous Cell Carcinoma (SCC), normal endocervix, chronic endocervicitis, Low-Grade Cervical Glandular Intraepithelial

Neoplasia (LCGIN), Adenocarcinoma In Situ (AIS) and adenocarcinoma. The quantitative nuclear morphometry analysis was done and entered in Microsoft Excel sheet. Statistical analysis was done by using SPSS software 22.0 version. The p-value <0.05 was considered as statistically significant.

**Results:** In ectocervical cases, all the nuclear parameters as Mean Nuclear area (MNA), Mean Nuclear Perimeter (MNP), Minimum Nuclear Diameter (mND), Maximum Nuclear Diameter (MND), Mean Nuclear Compactness (MNC) and Mean Nuclear size (MNS) were statistically significant (p-value <0.05) except Mean Shape Factor (MSHF) where the p-value was 0.415. In the endocervical cases, only mND and MSHF were statistically significant.

**Conclusion:** Nuclear morphometry can be used as a tool in distinguishing the premalignant and malignant lesions in both ectocervical and endocervical tissue samples.

**Keywords:** Cervical cancer, Cervical intraepithelial neoplasm, Morphometric study

## INTRODUCTION

Cervical cancer is the second most common cancer among women all over the world [1,2]. In India, it is the most common gynaecological cancer and one of the leading causes of cancer-related deaths in women. In Kolar, Karnataka, the prevalence of carcinoma cervix amounts to 17.55% of all cancer cases in the female population. Squamous cell carcinoma constitutes 80% of cases and adenocarcinoma is relatively rare [3]. The diagnosis of pre-malignant and malignant lesions of the cervix is predominantly dependent on the presence of atypia. These atypical cells are primarily identified and classified based on their characteristic nuclear features [2]. There is a high degree of interobserver variability in the subcategorisation of LSIL and HSIL as well as LCGIN and AIS. These discrepancies are due to the dependency on visual interpretation for the diagnosis of these lesions. Moreover, very few studies have attempted morphometric analysis of both the ectocervical and endocervical; pre-malignant and malignant lesions [4-6]. This study attempts to reduce the variability in the use of subjective visual evaluation of histopathological specimens, which is the gold standard for diagnosis, by employing morphometrical analysis and thus providing an objective, quantitative and reproducible interpretation of endocervical and ectocervical pre-malignant and malignant lesions.

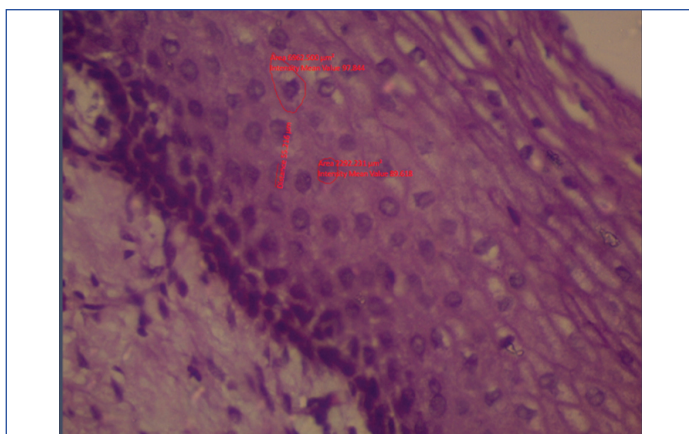
## MATERIALS AND METHODS

This study is a retrospective cross-section study which was done on 120 cases of cervical specimens which were either in the form of cervical biopsy or hysterectomy specimens. This study was approved by the Institutional Ethics Committee (DMC/KLR/IEC/155/2016-2017). The records and histopathological slides of these cases were retrieved from the archives of the Department of Pathology, Sri Devaraj Urs Medical College between October 2016

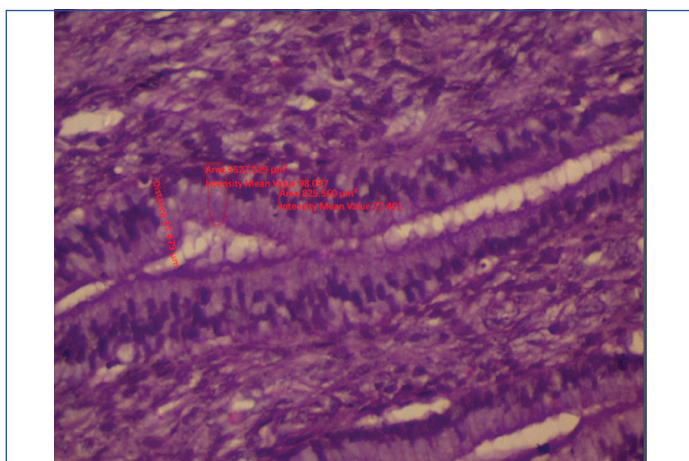
to September 2017. Cases that had undergone chemotherapy or radiotherapy were excluded from the study. The 120 cases were then categorised histomorphologically into normal ectocervix, chronic cervicitis, LSIL, HSIL, SCC, normal endocervix, chronic endocervicitis, LCGIN, AIS and adenocarcinoma. The diagnosis of LCGIN is more challenging as many features overlap with those of reactive changes. The glands in LCGIN show pseudostratification, with mild loss of polarity, hyperchromatic nucleus and absent/minimal mitosis. Stroma is typically devoid of inflammatory or reactive changes. In AIS dysplasia is more severe. The glands show crowding with numerous architectural patterns such as branching, intraluminal papillary pattern, micropapillary pattern and sometimes cribriform pattern of glands. The atypical cells have scant to moderate amount of mucin, markedly pleomorphic and hyperchromatic nuclei. Also, the degree of atypia and mitotic activity is greater than that seen in LCGIN [7]. The quantitative morphometrical analysis was done by using images captured of the representative area under Carl ZeissTM Primo StarTM microscope at X400 magnification for each case. At least 50 non-overlapping cells were analysed per case. The stromal cells or background cells were not included in the analysis. These cells were outlined using the ZEN 2.3 (blue edition) version 2.3.69.1000 @Carl Zeiss Microscopy GmbH, 2011 software. MNA, MNP, mND, MND were measured as shown in [Table/Fig-1,2]. These parameters were saved in the excel sheet and later were used to calculate the other three parameters namely,

- Mean nuclear Compactness (MNC)= $MNP^2/MNA$
- Mean Shape factor (MSHF)= $4 \times \pi \times MNA/MNP^2$
- Mean Nuclear size (MNS)= $2 \times (MNA/\pi)^{0.5}$  [8]

After obtaining the above parameters for each case, finally, the average value of each parameter was calculated for each histopathological category.



**[Table/Fig-1]:** Morphometrical analysis of cells using the ZEN 2.3 (blue edition) version 2.3.69.1000 @Carl Zeiss Microscopy GmbH, 2011 software.



**[Table/Fig-2]:** Morphometric image of endocervical cells using the ZEN 2.3 (blue edition) version 2.3.69.1000 @Carl Zeiss Microscopy GmbH, 2011 software.

## STATISTICAL ANALYSIS

All the captured data was coded and entered in Microsoft Excel sheet. Continuous variables were represented by mean±SD. The nuclear parameters between all the groups of ectocervix and

endocervix were analysed using ANOVA and between the groups using a post-hoc test i.e. Bonferroni multiple comparison tests. Analysis was done by using SPSS software, version 22.0. The p-value <0.05 was considered as statistically significant.

## RESULTS

A total of 120 cases of cervical specimens were studied. These cases were then categorised into two main groups of ectocervix and endocervix. The ectocervix group was subcategorised into normal ectocervix (12), chronic cervicitis (12), LSIL (05), HSIL (08), squamous cell carcinoma (24). Similarly, the endocervix group was subcategorised into normal endocervix (26), chronic endocervicitis (13), LCGIN (20). Authors did not receive any case of AIS and adenocarcinoma during the period of study. [Table/Fig-3,4] show the nuclear parameters analysed in the different groups of both the ectocervical and endocervical cases. Using ANOVA for the ectocervical cases, all the nuclear parameters were statistically significant (p-value <0.05) except MSHF where the p-value was 0.415 whereas, in the endocervical cases, only mND and MSHF were statistically significant (p-value <0.05) [Table/Fig-3,4].

## DISCUSSION

Cervical cancer is one of the leading causes of cancer and cancer-related morbidity among women all over the world [1,2]. In Kolar, Karnataka, cervical cancer accounts for 17.55% of all cancer cases in the female population. In a developing country like India, most of these cases present at an advanced stage [3]. The diagnosis of premalignant and malignant lesions of the cervix is predominantly dependent on the presence of abnormal cells. These abnormal cells are primarily identified and classified subjectively based on their characteristic nuclear features such as nuclear size, irregularity of nuclear border, nuclear pleomorphism, nuclear hyperchromatism and chromatin distribution [4]. There is a high degree of interobserver variability in the subcategorisation of high and low-grade lesions by subjective assessment. These discrepancies can be reduced by using objective visual evaluation by employing morphometrical analysis [5,6,9-12]. Thus, authors aimed at assessing the utility of nuclear morphometry through digital image analysis in converting

Ectocervix	NEC	CE	LSIL	HSIL	SCC	ANOVA (F value)	p-value
	(n=12)	(n=12)	(n=5)	(n=8)	(n=24)		
	Mean±SD	Mean±SD	Mean±SD	Mean±SD	Mean±SD		
mND (µ)	13.71±1.49	15.40±0.92	44.70±2.68	60.48±4.31	43.43±6.09	162.77	<0.001
MND (µ)	24.55±1.21	27.76±1.61	64.91±2.91	72.43±7.78	76.42±8.66	146.512	<0.001
MNA (µ²)	235.15±10.08	265.18±52.37	2098.51±428.03	3340.31±564.57	4317.19±889.62	37.3	<0.001
MNP (µ)	60.09±2.06	67.77±4.75	161.44±16.92	207.62±10.91	289.65±19.89	196.20	<0.001
MNC	15.35±1.28	17.31±1.50	12.42±0.05	12.91±3.07	17.56±6.10	3.108	0.022
MSHF	0.81±0.06	0.72±0.05	1.01±0.01	0.97±0.14	0.84±0.44	1.001	0.415
MNS	17.31±0.37	18.38±1.90	51.7±5.38	65.23±5.91	73.48±10.22	73.6	<0.001

**[Table/Fig-3]:** Nuclear parameters in different ectocervical lesions.

NEC: Normal ectocervix; CE: Chronic cervicitis; LSIL: Low grade squamous intraepithelial lesion; HSIL: High grade squamous intraepithelial lesion; SCC: Squamous cell carcinoma

Endocervix	NEN	PEC	LCGIN	ANOVA (F Value)	p-value
	(n=26)	(n=13)	(n=20)		
	Mean±SD	Mean±SD	Mean±SD		
mND (µ)	53.11±1.55	54.03±1.50	47.70±3.64	12.16	<0.001
MND (µ)	65.01±1.56	62.64±1.72	65.62±2.88	2.27	0.121
MNA (µ²)	2167.51±13.57	2162.83±41.03	1184.25±371.19	2.76	0.079
MNP (µ)	185.56±2.47	183.18±4.97	178.03±8.51	3.11	0.059
MNC	15.88±0.36	15.24±0.86	12.94±3.69	2.01	0.152
MSHF	0.79±0.01	0.82±0.04	0.97±0.12	9.30	<0.001
MNS	52.55±0.16	52.94±0.49	55.86±4.67	2.13	0.136

**[Table/Fig-4]:** Nuclear parameters in different endocervical lesions.

NEN: Normal endocervix; PEC: Polypoidal endocervicitis; LCGIN: Low grade cervical glandular intraepithelial neoplasia

these subjective parameters into an objective, quantitative, and reproducible parameters for the interpretation of endocervical and ectocervical pre-malignant and malignant lesions.

In the present study, authors have considered the nuclear parameters such as mND, MND, MNA, MNP, MNC, MSHF and MNS to differentiate between premalignant and malignant lesions in ectocervix and endocervix. The MSHF indicates nuclear shape irregularity [9]. Some of the studies which are done in breast and thyroid cases used these parameters for nuclear morphometry study and are published in English literature [8,13]. Among the mentioned parameters which were studied in the ectocervix group, all the nuclear parameters were statistically significant (p-value <0.05) except for MSHF where the p-value was 0.415 [Table/Fig-3]. Conversely, in the endocervix group only mND and mean shape factor MSHF were statistically significant (p-value <0.05) [Table/Fig-4]. However, due to the unavailability of cases in the endocervix group, a concrete opinion cannot be formed regarding the utility of morphometry in this group.

In a study done on cervical pap smears by Divya Rani MN et al., nuclear diameter and nuclear area were statistically significant (p-value <0.001) between premalignant and malignant squamous lesions of cervix [2]. In a similar study done by Po CH et al., using computer-based image analysis and Support Vector Machine, it showed that nuclear perimeter, nuclear area and nuclear diameter were statistically significant in dysplastic squamous cells [4]. Another study was done on cervix by Nemec E et al., using Feulgen stained tissue showed 97% specificity and 88% sensitivity in differentiating between normal and dysplastic squamous cells [14]. In this study, there was gradual increase in the nuclear parameters as the disease progressed from normal cervix to premalignant lesion to carcinoma in both the ectocervix and endocervix group with statistical significance [Table/Fig-3,4]. Similar findings were seen in the study done by Divya Rani MN et al., in Pap smears, however this study was done on tissue sections [2].

Many morphometry studies of other organs as breast and thyroid are published. In a morphometry study done on breast FNAC by Sabina L et al., parameters like nuclear diameter and nuclear area were statistically significant (p-value <0.001) between benign and malignant breast lesions [13,14]. Thus, in this study, nuclear diameter, nuclear perimeter, nuclear area, nuclear compactness and nuclear size were highly useful in differentiating premalignant lesions from carcinoma in the ectocervix group with a p-value of <0.05. Mean shape factor was not significant in doing the same with a p-value of >0.05 [Table/Fig-3]. However, in the endocervix group minimum nuclear diameter and nuclear shape factor was the significant parameters in differentiating between the normal endocervix, endocervicitis and LCGIN with a p-value of <0.05. All the other parameters were not statistically significant [Table/Fig-4].

## LIMITATION

The limiting factors of this study were the unavailability of AIS and adenocarcinoma cases during the stipulated period. Thus, the nuclear morphometric parameters were not assessed in these two subgroups of endocervical lesions. However, the present study

highlights the nuclear morphometric analysis in both ectocervical and endocervical tissue sections. The study was done on tissue sections which can overcome the fixation artefacts as in Pap smears. Doing this study in large population can help to derive the normal and abnormal values of different nuclear parameters in different grades of the ectocervical and endocervical lesions and can be used in cases with diagnostic ambiguity. The mean values derived in this study in different ectocervical and endocervical lesions can be applied for cytology smears.

## CONCLUSION

Nuclear morphometry can be used as a tool in distinguishing the premalignant and malignant lesions in both ectocervix and endocervix. It can aid in solving cases with diagnostic ambiguity and offer appropriate quality treatment strategies. As this study was done on histopathology tissue sections, the nuclear morphometric mean values derived can be used as basic values in morphometric assessment of Pap smears.

## ACKNOWLEDGEMENTS

Dr. Sunil Bage, Assistant Professor of Community Medicine Department, for the statistical analysis for this study.

## REFERENCES

- [1] Jondet M, Agoli-Agbo R, Dehennin L. Automatic measurement of epithelium differentiation and classification of cervical intraepithelial neoplasia by computerized image analysis. *Diag Pathol*. 2010;5(1):7-10.
- [2] Divya Rani M.N, Narasimha A, Harendra Kumar ML, Sheela SR. Evaluation of pre-malignant and malignant lesions in cervico vaginal (PAP) smears by nuclear morphometry. *J Clin Diag Res*. 2014;8(11):16-19.
- [3] Kalyani R, Das S, Singh MSB, Kumar HML. Cancer profile in Kolar: A ten years study. *Indian J Cancer*. 2010;47(2):160-65.
- [4] Po CH, Yung KC, Po CC, Yung-Fu C, Rung CC, Yu-Ruei H. Quantitative assessment of pap smear cells by PC based cytopathologic image analysis system and support vector machine. *Lecture Notes in Computer Science*. 2007;4901:192-99.
- [5] Guillaud M, Cox D, Adler-Storthz K, Malpica A, Staerkel G, Matisic J, et al. Exploratory analysis of quantitative histopathology of cervical intraepithelial neoplasia: objectivity, reproducibility, malignancy-associated changes, and human papillomavirus. *Cytometry Part A*. 2004;60(1):81-89.
- [6] Ismail S, Colclough A, Dinnen J, Eakins D, Evans D, Gradwell E, et al. Reporting cervical intra-epithelial neoplasia (CIN): intra- and interpathologist variation and factors associated with disagreement. *Histopathol*. 1990;16(4):371-76.
- [7] Izadi-Mood N, Sarmadi S, Sotoudeh K. Cervical Glandular Intraepithelial Neoplasia (CGIN). In book: *Intraepithelial Neoplasia*. doi: 10.5772/31209.
- [8] Yashaswini R, Suresh TN, Sagayaraj A. Cytological evaluation of thyroid lesions by nuclear morphology and nuclear morphometry. *J Cytol*. 2017;34(4):197-202.
- [9] McCluggage W, Walsh M, Thornton C, Hamilton P, Date A, Caughley L, et al. Inter- and intra-observer variation in the histopathological reporting of cervical squamous intraepithelial lesions using a modified Bethesda grading system. *Br J Obstet Gynaecol*. 1998;105(2):206-10.
- [10] Koss L. *Diagnostic cytology and its histopathologic bases*. Philadelphia: JB Lippincott, 1992.
- [11] Swartz R, West L, Boiko I, Malpica A, MacAulay C, Carraro M, et al. Use of nuclear morphometry characteristics to distinguish between normal and abnormal cervical glandular histologies. *Analytical Cellular Pathol: Journal Euro Soc Analytical Cellular Pathol*. 2003;25(4):193-200.
- [12] Buhmeida A. Quantitative pathology: historical background, clinical research and application of nuclear morphometry and DNA Image Cytometry. *Libyan J Med*. 2006;1(2):126-39.
- [13] Sabina L, Shameen S. Significance of nuclear morphometry on fine needle aspirates of breast lesions. *J Med Res*. 2015;27(1):72-75.
- [14] Nemec E, Vandeputte S, Van Pachterbeke R, Vokaer R, Budel V, Deprez C, et al. Ploidy and chromatin analysis as an aid for cervical smear diagnosis. *Histopathol*. 2002;17(2):403-09.

### PARTICULARS OF CONTRIBUTORS:

1. Resident, Department of Pathology, Sri Devaraj Urs Medical College, Sri Devaraj Urs Academy of Higher Education and Research, Kolar, Karnataka, India.
2. Professor and Head, Department of Pathology, Sri Devaraj Urs Medical College, Sri Devaraj Urs Academy of Higher Education and Research, Kolar, Karnataka, India.
3. Professor and Head, Department of Obstetrics and Gynaecology, Sri Devaraj Urs Medical College, Sri Devaraj Urs Academy of Higher Education and Research, Kolar, Karnataka, India.

### NAME, ADDRESS, E-MAIL ID OF THE CORRESPONDING AUTHOR:

Dr. Kalyani Raju,  
Professor and Head, Department of Pathology, Sri Devaraj Urs Medical College, Sri Devaraj Urs Academy of Higher Education and Research, Kolar-563101, Karnataka, India.  
E-mail: drkalyanir@rediffmail.com

FINANCIAL OR OTHER COMPETING INTERESTS: None.

Date of Submission: **Nov 09, 2018**  
Date of Peer Review: **Dec 25, 2018**  
Date of Acceptance: **Feb 28, 2019**  
Date of Publishing: **Apr 01, 2019**