

## Original Research Article

# Spectrum of right iliac fossa mass differential diagnosis and their management

G. V. V. Prasad Reddy<sup>1</sup>, Konappa V.<sup>2\*</sup>, V. Mahidar Reddy<sup>3</sup>, Dharmendra Kumar<sup>2</sup>

Department of General Surgery, <sup>1</sup>MVJ Medical College and Research Hospital, Hoskote, Karnataka, <sup>2</sup>Sri Devaraj Urs Medical College, Kolar, Karnataka, <sup>3</sup>Narayana Medical College, Nellore, Andhra Pradesh, India

**Received:** 19 May 2019

**Revised:** 04 June 2019

**Accepted:** 05 June 2019

**\*Correspondence:**

Dr. Konappa V.,

E-mail: [drkonu123@gmail.com](mailto:drkonu123@gmail.com)

**Copyright:** © the author(s), publisher and licensee Medip Academy. This is an open-access article distributed under the terms of the Creative Commons Attribution Non-Commercial License, which permits unrestricted non-commercial use, distribution, and reproduction in any medium, provided the original work is properly cited.

### ABSTRACT

**Background:** Right iliac fossa mass is a common clinical entity encountered in routine surgical practice. The mass arises from different anatomical structures with varied aetiologies that require a high clinical suspicion in its management. The reason being that the mass may range from being benign to most aggressively malignant lesion which encompasses various specialities of surgery like genitourinary, vascular, gynaecological and colorectal surgery. **Methods:** This was a prospective observational study conducted between August 2015 and October 2017 in Narayan Medical College and Hospital, Nellore. 50 cases were studied after detailed history and physical examination, relevant investigations were done, and different surgical procedures done were noted and histopathological examination of resected specimens was done.

**Results:** In this series out of 50 patients studied, 23 patients (46%) were diagnosed to have appendicular mass, 10 cases (20%) ileocaecal TB, 8 cases (16%), appendicular abscess, 6 cases (12%) CA Caecum, 3 cases (6%) psoas abscess. Most commonly encountered in 3<sup>rd</sup> decade of life with male predominance.

**Conclusions:** RIF mass is a challenging clinical scenario for the surgeons. Keeping in mind the various differential diagnosis with good clinical acumen supported by appropriate investigations, patients with RIF mass can be managed appropriately either by conservative or surgical management.

**Keywords:** Right iliac fossa mass, Clinical presentation, Management

### INTRODUCTION

Right iliac mass is the commonest entity frequently encountered in clinical practice which requires skill for diagnosis.<sup>1</sup> The varied etiology of these conditions presents a diagnostic challenge to the surgeon, as appropriately said by Sir Hamilton Bailey "A correct diagnosis is the hand maiden of a successful operation".<sup>2</sup> The mass has varied anatomical and etiological origin and requires versatility in its management. Right iliac fossa has 8 anatomical entities which includes appendix, caecum, terminal ileum, lymph nodes, iliac artery and vein, retroperitoneal connective tissues, ilio psoas

muscle, and iliac bone., and other organs in the neighborhood like kidney, gallbladder, uterus, ovaries, urinary bladder and testis whose pathology may extend into this region. Right iliac fossa masses arise either from the normal structures present in area between symphysis pubis, umbilicus and ASIS or sometimes the mass arises from the structures abnormally located in the region.<sup>3,4</sup> In this study the patients were subjected to radiological and pathological investigations.<sup>5</sup> The most common differential diagnosis encountered in order of frequency was appendicular mass, appendicular abscess, ileocaecal TB, right ovarian mass, CA caecum, right ectopic kidney,

Rectus sheath hematoma, psoas abscess and amoeboma.<sup>6,7</sup>

This prospective observational study was undertaken to study the varied etiologies of right iliac fossa mass, their clinical presentation, underlying pathologies and different methods of management.

## METHODS

A prospective observational study which was conducted between august 2015 and October 2017 in Narayan Medical College and Hospital, Nellore. 50 patients presenting to the general surgery OPD with RIF masses were studied.

### Inclusion criteria

Inclusion criteria were all cases of age more than 12 years that presented during the study period having mass in RIF; patients of both sex; patients with mass in RIF found incidentally on examination and by investigations are included in the study.

### Exclusion criteria

Exclusion criteria were patients having mass in RIF due to gynecological conditions; patients with debilitating illness like CRF, ARF, CAD, Liver failure etc.

### Method of collection of data

Thorough clinical history and physical examination of all case was done.

The following investigations were done to the patients who met the inclusion criteria:

- Blood and urine routine.
- Urea and electrolytes.
- Stool for occult blood, ova and cyst.
- Plain X ray of chest and abdomen.
- USG abdomen and pelvis.
- CECT of abdomen and pelvis.
- Colonoscopy and biopsy in suspected cases of carcinoma caecum.
- Diagnostic laparoscopy and biopsy in selected cases.

Various surgical procedures in the form of:

- Interval appendectomy.
- Radical right hemicolectomy and ileo transverse colon anastomosis.
- Limited ileo-colic resection and ileo ascending colon anastomosis.
- Extra peritoneal drainage of abscess.
- Intra peritoneal drainage of abscess.

These interventions are done as per need in each case. Histopathological examination of resected specimens were done.

### Statistical analysis

Data was entered into Microsoft excel data sheet and was analyzed using SPSS 22 version software. Categorical data was represented in the form of Frequencies and proportions.

## RESULTS

Total number of cases considered in this study is 50, admitted in the Department of General Surgery, Narayana Medical College and Hospital, Nellore. The results of the study are discussed as following.

**Table 1: Causes of right iliac fossa swellings.**

Diagnosis	No. of cases	Percentage (%)
Appendicular mass	23	46
Ileocaecal TB	10	20
Appendicular abscess	8	16
CA caecum	6	12
Psoas abscess	3	6
Total	50	100

In this series out of 50 patients, 23 patients (46%) diagnosed to have appendicular mass followed by ileocaecal TB (10 cases, 20%), appendicular abscess (8 cases, 16%), CA caecum (6 cases, 12%), psoas abscess (3 cases, 6%).

In this series age varied from 14 years to 60 years. appendicular pathology is commonest in 3<sup>rd</sup> decade, ileocaecal TB in 4<sup>th</sup> decade, CA caecum and psoas abscess in 6<sup>th</sup> decade (Table 2). In total of 50 patients, 28 (56%) were males and 22 (44%) were females.

In the present study pain was the commonest symptom of presentation seen in all cases, fever was present in 78% cases, vomiting was present in 42% cases, loss of weight and appetite was present in 24% cases, constipation was present in 16% cases, diarrhea was present in 8% cases, mass per abdomen was present in 26% cases.

In the present study USG abdomen was done in all cases. colonoscopy was done in all cases of CA caecum and multiple biopsies were taken. CECT abdomen was done in all case of CA caecum for staging. Diagnostic laparoscopy was done in 2 case (20%) of ileocaecal TB.

In the present study 27 cases (54%) were managed conservatively and 23 cases (46%) were treated surgically. All the cases of appendicular mass were managed conservatively. 4 cases of ileocaecal TB were

managed by medical management and rest all the cases are treated surgically.

Patients with appendicular abscess and psoas abscess are managed by surgical drainage. CA caecum patients are managed by radical right hemicolectomy with ileo-transverse colon anastomosis (Figure 1 and Figure 2). 6 cases of ileocaecal TB are treated by limited resection

with ileo-ascending colon anastomosis. All patients who underwent interval appendectomy (Figure 3), HPE suggestive of chronic appendicitis. All patients of CA Caecum undergone radical right hemicolectomy and HPE report came as well differentiated adenocarcinoma. 6 cases of ileocaecal TB underwent limited resection ileo-ascending colon anastomosis (Figure 4) and HPE report of resected specimens are suggestive of Ileo caecal TB.

**Table 2: Age wise distribution of causes.**

Age in years	Appendicular mass	Ileocaecal TB	Appendicular abscess	CA caecum	Psoas abscess	Total no of cases	Percentage (%)
12-20	5	0	2	0	0	7	14
21-30	13	1	4	0	0	18	36
31-40	3	7	1	0	0	11	22
41-50	1	2	1	2	1	7	14
>50	1	0	0	4	2	7	14
<b>Total</b>	<b>23</b>	<b>10</b>	<b>8</b>	<b>6</b>	<b>3</b>	<b>50</b>	<b>100</b>

**Table 3: Gender wise distribution of RIF mass.**

Gender	RIF mass
<b>Male</b>	28
<b>Female</b>	22

**Table 4: Presenting symptoms diagnosis wise.**

S. no	Diagnosis	Pain	Fever	Vomiting	Loss of appetite and weight loss	Constipation	Diarrhoea	Mass
1	Appendicular mass	23	18	15	0	0	2	5
2	Ileocaecal TB	10	10	6	6	6	0	3
3	Appendicular abscess	8	8	6	0	0	2	2
4	CA caecum	6	0	0	6	2	0	3
5	Psoas abscess	3	3	0	0	0	0	0
	<b>Total</b>	<b>50</b>	<b>39</b>	<b>21</b>	<b>12</b>	<b>8</b>	<b>4</b>	<b>13</b>

**Table 5: Endoscopy and imaging as per diagnosis.**

S. no	Diagnosis	USG	Colonoscopy	CT scan	Diagnostic laparoscopy
1	Appendicular mass	23	0	0	0
2	Ileocaecal TB	10	0	0	2
3	Appendicular abscess	8	0	0	0
4	CA caecum	6	6	6	0
5	Psoas abscess	3	0	0	0
	<b>Total</b>	<b>50</b>	<b>6</b>	<b>6</b>	<b>2</b>

**Table 6: Treatment as per diagnosis.**

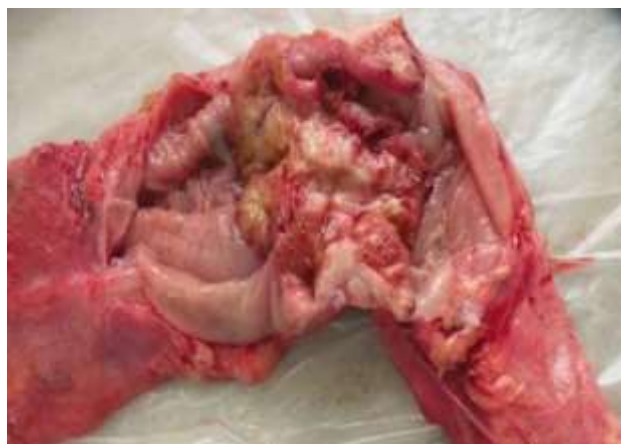Diagnosis	No. of cases	Conservative management	Surgery
<b>Appendicular mass</b>	23	23	0
<b>Ileocaecal TB</b>	10	4	6
<b>Appendicular abscess</b>	8	0	8
<b>CA caecum</b>	6	0	6
<b>Psoas abscess</b>	3	0	3
<b>Total</b>	<b>50</b>	<b>27</b>	<b>23</b>

**Table 7: Details of surgery as per diagnosis.**

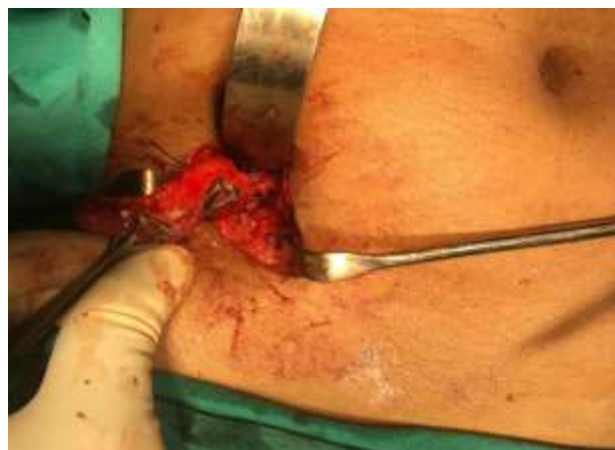Diagnosis	Intraperitoneal drainage of abscess	Interval appendectomy	Limited resection with ileo – ascending colon anastomosis	Radical right hemicolectomy with ileo-transverse colon anastomosis	Extraperitoneal drainage of abscess
<b>Appendicular mass</b>	0	11	0	0	0
<b>Ileocaecal TB</b>	0	0	6	0	0
<b>Appendicular abscess</b>	2	4	0	0	6
<b>CA caecum</b>	0	0	0	6	0
<b>Psoas abscess</b>	0	0	0	0	3
<b>Total</b>	2	15	6	6	9

**Table 8: HPE report of the resected specimens.**

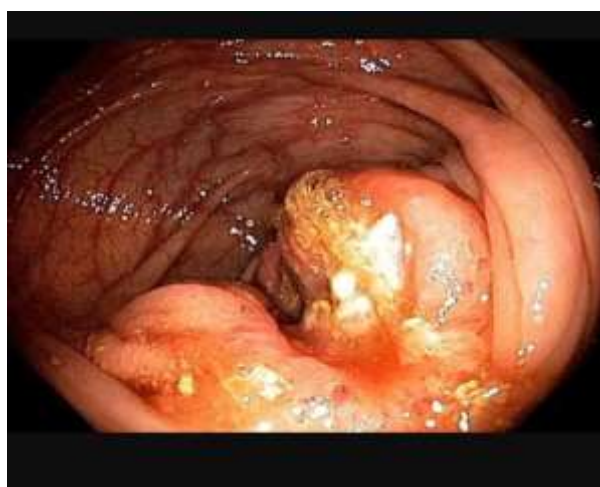
Pre op diagnosis	No of surgeries	Surgery	HPE report
<b>Appendicular pathology</b>	15	Interval appendectomy	Appendicitis
<b>Ileocaecal TB</b>	6	Limited resection with ileo-ascending colon anastomosis	Ileocaecal TB
<b>CA Caecum</b>	6	Radical Right hemicolectomy	Well differentiated adenocarcinoma



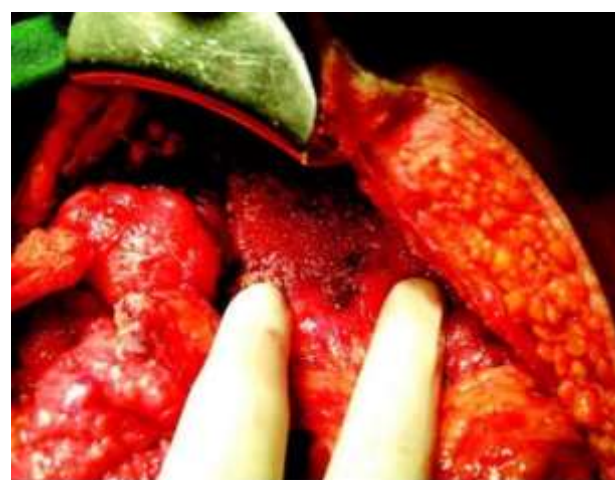**Figure 1: Carcinoma caecum.**



**Figure 3: Interval appendectomy.**



**Figure 2: Typical ulcerated growth at caecum.**



**Figure 4: Plastered abdomen with multiple tubercles.**



## DISCUSSION

This study was carried out to study the various conditions/diseases presenting as mass in the right lower abdomen with relation to incidence, age, sex, clinical presentation, management of the condition, histopathological examination of resected specimens. In this study, 50 cases with right iliac fossa mass were admitted in Department of General surgery, Narayana Medical College and Hospital, Nellore, during the period from August 2015 to October 2017 were taken up. After detailed history and thorough clinical examination, provisional diagnosis was made. Later on patients were subjected to relevant investigations and operations if necessary and final diagnosis was made after the investigations and/or operation. The following are the observation and inference which was taken out. The distribution of various pathology according to the order of frequency is shown in Table I. Appendicular pathology (appendicular mass and abscess) was the most common disease encountered followed by ileocaecal tuberculosis, CA caecum and psoas abscess. In a study conducted in Mahatma Gandhi Medical College and hospital, Jaipur, 50 patients with signs and symptoms of RIF mass were included, among which 62% of cases were related to appendicular pathology either in the form of appendicular mass (48%) or appendicular abscess (14%), ileocaecal TB (16%), CA caecum (12%) other (10%).<sup>8</sup> In an observational study of RIF mass conducted in Rawalpindi medical college Appendicular pathology 33.7% was the commonest finding followed by caecal carcinoma (9.8%), ileocaecal TB (9.8%), psoas abscess (7.6%), others (39%).<sup>9</sup> In a prospective study conducted by Shashikala et al in Victoria hospital affiliated to Bangalore Medical college and research institute in 50 patients the most common cause of RIF lump was appendicular mass, followed by ileocaecal tuberculosis, appendicular abscess and caecal carcinoma.<sup>10</sup> In a prospective study conducted at Shadan Institute of Medical Sciences, out of 60 patients having RIF mass : appendicular pathology was found in 70% either in form of appendicular mass or abscess, ileocaecal TB in 20%, CA caecum in 6.6% and others 3.3% cases.<sup>11</sup> In a prospective study conducted by Hussain et al in Liaquat University, Jamshoro, Abudabi The most common cause of right iliac fossa mass was ileocaecal tuberculosis (33.9%) followed by appendicular abscess in (23.2%) and carcinoma caecum in 17% and psoas abscess in 4.5%.<sup>12</sup> In a study conducted by Shetty and Shankar, Appendicular pathology was found in 52%, ileocaecal tuberculosis in 22% of the cases, CA caecum in 16% of cases, psoas abscess in 8% of the cases.<sup>13</sup> Results of our study correlated with most of the studies discussed here.

## CONCLUSION

In the present study the most common cause of RIF mass encountered was appendicular pathology followed by ileocaecal TB, carcinoma caecum and psoas abscess. Majority of the patients presented in their 3rd decade followed by 4th decade of life with male predominance.

All patients of appendicular mass were initially managed conservatively, and who responded well, were advised to undergo interval appendectomy. All Cases of appendicular abscess were treated by open drainage and appropriate antibiotic therapy. Patients with ileocaecal tuberculosis was common in age group of 30-50 years, with male predominance and most commonly presented with intestinal obstruction and were managed by limited resection with ileo-ascending colon anastomosis followed by ATT. 6 cases of RIF mass were diagnosed to have CA Caecum and were managed by radical right hemicolectomy with ileo-transverse anastomosis, followed by adjuvant chemotherapy. Psoas abscess case was managed by extraperitoneal drainage and appropriate antibiotic therapy. RIF mass is a challenging clinical scenario for the surgeons. Keeping in mind of differential diagnosis with good clinical examination aided with appropriate investigations patient with RIF mass can be managed appropriately either by conservative or surgical management.

*Funding: No funding sources*

*Conflict of interest: None declared*

*Ethical approval: The study was approved by the Institutional Ethics Committee*

## REFERENCES

1. Dnyanmote AS, Sinha N, Chavan S, Sable S. Clinico-pathological study of right Iliac Fossa Mass. Available at: <http://www.webmedcentral.com>. Accessed on 24 November 2014.
2. Bailey H. Bailey hamilton's demonstrations of physical signs in surgery. In: Clain A, ed. 18th edn. London: ELBS with Butterworth Heinmann; 1997.
3. Panarese A, Pironi D, Pontone S, Vendettuoli M, De Cristofaro F, Antonelli M, et al. A case of symptomatic mass in RIF: a Bermuda triangle which often lies the right diagnosis. *Ann Ital Chir.* 2014;24:85-8.
4. Sunderesh N Jr, Narendran S, Ramanathan M. evaluation of pathological nature of RIF mass and its management. *J Biomed Sci Res.* 2009;1(1):55-8.
5. Turnage RH, Mizell J, Badgwell B. Sabiston book of General Surgery. Chapter 43. South Asia Edition; 2017: 1079.
6. Howell S, Knapton PJ. Ileo-caecal tuberculosis. *Gut* 1964;5:524-9.
7. Dnyanmote AS, Sinha N, Chavan S, Sable S. Clinico pathological study of RIF mass. *Webmed Central General Surg.* 2014;5(11):26-30.
8. Prakash MR, Dutt SC. Clinical study of Mass in Right Iliac Fossa. *Int J Sci Res.* 2016;6(5):1-4.
9. Akhtar T, Sharif A, Akhtar M, Zia N, Hanif M. Mass in Right Iliac Fossa- Clinicopathological Evaluation. *J Rawalpindi Med Coll.* 2017;21(1):45-7.
10. Shashikala V, Victor AJ, Sonia Rani PB. Right Iliac Fossa Mass: A prospective study. *Int J Biomed Adv Res.* 2016;7(8):388-92.

11. Reddy NMV, Reddy RM. Study of Mass in Right Iliac Fossa. *J Den Med.* 2016;15(8):81-4.
12. Shetty SK, Shankar M. A clinical study of right iliac fossa mass. *Int J Surg.* 2013;30(4):1-11.
13. Hussain A, Shah SKA, Bhatti NK, Ahmed Z, Memon HNA, Shah SZA. Right iliac fossa mass, clinical spectrum. *Prof Med J.* 2016;23(8):953-8.

**Cite this article as:** Reddy GVVP, Konappa V, Reddy VM, Kumar D. Spectrum of right iliac fossa mass differential diagnosis and their management. *Int Surg J* 2019;6:xxx-xx.