



COMPARISON OF ASTIGMATISM CORRECTION FOLLOWING STRAIGHT AND FROWN INCISIONS IN MANUAL SMALL INCISION CATARACT SURGERY

Dr Nithiya Joe Babu Dr Nithiya Joe Babu, Resident, Sri Devraj Urs Medical College, Kolar,

Dr. Sandhya R Dr. Sandhya R, Professor and HOU, Sri Devraj Urs Medical College, Kolar

ABSTRACT

The type of incision is the major contributory factor to the postoperative astigmatism. Different incisions may cause different degrees of astigmatism. It becomes imperative to compare the SIA caused by the commonly used incisions like straight and frown incisions.

OBJECTIVES

- To evaluate and compare the postoperative astigmatism following straight and frown incision
- To compare the efficacy of straight and frown incision to reduce the postoperative astigmatism.

MATERIALS AND METHODS For this prospective study a total of 96 eyes fulfilling the inclusion criteria were selected and allotted into two groups by simple randomization technique.

Group1 – 48 patients – underwent MSICS with straight incision.

Group2 – 48 patients – underwent MSICS with frown incision.

This prospective study was conducted in the department of ophthalmology at R. L. Jalappa Hospital And Research, Kolar attached to Sri Devaraj Urs Medical College, between February 2019 and March 2019. Post-operative visual acuity was assessed with Snellen's chart. Post-operative keratometry was SIA calculator version 2.1 was used to calculate the SIA. **RESULTS** The mean magnitude of preoperative astigmatism in straight incision was 1.26 ± 0.92 D and in frown incision was 0.98 ± 0.83 D. The mean magnitude of postoperative astigmatism in straight incision was 1.52 ± 1.17 D and in frown incision was 0.99 ± 0.82 D and was found to be statistically significant, $p = 0.012$. The centroid of SIA for straight incision was 1.4×10 with a coherence of 90% and the centroid of SIA for frown incision was 0.62×20 with a coherence of 70%. **CONCLUSION** The mean magnitude of postoperative astigmatism in straight incision was 1.52 ± 1.17 D. The mean axis of postoperative astigmatism in straight incision was 96.5 ± 74.9 D. The mean magnitude of postoperative astigmatism in frown incision was 0.99 ± 0.82 D. The mean axis of postoperative astigmatism in frown incision was 74.96 ± 68.78 D. The magnitude of postoperative astigmatism was greater in straight incision when compared to frown incision and the difference was statistically significant. Straight incision should be used for highly significant and significant WTR astigmatism while frown may be used for significant astigmatism and non-significant WTR astigmatism.

KEYWORDS

SIA, SICS, Postoperative astigmatism, straight incision, frown incision, MSICS.

***Corresponding Author** Dr. Sandhya R

Professor and HOU, Sri Devraj Urs Medical College, Kolar email:sanchina@rediffmail.com

INTRODUCTION

In India and in other developing countries senile cataract is the leading cause of avoidable blindness. In 1990, 55.4% of the total blindness was attributed to cataract and refractive error in people aged 50 years and older. The prevalence of astigmatism in general population is around 20-40% and among rural population is around 58.70%. The preoperative astigmatism is seen in about 15-29 % patients undergoing cataract surgery. It is one of the causes of the reduced vision postoperatively.

The most pressing challenge facing the modern ophthalmologist is to achieve postoperative emmetropia. Spherical results have become more predictable as a result of increased attention to the technique of biometry and due to developments in technology like partial coherence interferometry. Post-operative astigmatism also plays an important role in the final visual outcome. Postoperative astigmatism is an undesirable by-product of cataract surgery. Due to the increasing expectations of the patients, surgeons now focus not only to correct the spherical error but also, to correct the astigmatism.

Today's cataract surgery can produce a better control of postoperative astigmatism either by producing an astigmatically neutral surgery or by using a mild induced astigmatism in the steep axis. Making an astigmatically neutral incision that cause lesser degree of astigmatism is preferred in patients with mild or no preoperative astigmatism. In patients with pre-existing astigmatism, postoperative astigmatism can be reduced by in patients by placing the incision on axis of the steep meridian, by using limbal relaxing incision or corneal relaxing incisions, toric intraocular lenses and by photo-astigmatic keratectomy(5).

The use of toric IOL can result in significant rotation of the IOL within

the capsular bag(6-8). It can also increase the higher-order aberrations. Photoastigmatic keratectomy can also increase the higher order aberrations besides adding to the cost of surgery. An incision in cataract surgery when they are properly planned may achieve the same results without additional procedures or incidental costs.

Either of the incision can result in postoperative emmetropia. Hence, we have undertaken this study to compare the correction of astigmatism following straight and frown incision in manual small incision cataract surgery (MSICS) with posterior chamber intraocular lens (PCIOL) implantation to determine the appropriate incision to provide postoperative emmetropia. In this study we aim to evaluate and compare the postoperative astigmatism following straight and frown incision and to compare the efficacy of straight and frown incision to reduce the postoperative astigmatism.

MATERIALS AND METHODS

SOURCE OF DATA

For this prospective study a total of 96 eyes fulfilling the inclusion criteria were selected and allotted into two groups by block randomization technique (48 eyes in each group). This study was conducted in the department of ophthalmology at R. L. Jalappa Hospital And Research, Kolar Attached To Sri Devaraj Urs Medical College, between February 2019 and March 2019. All patients between the age group of 40 - 70 years undergoing MSICS with PCIOL implantation were included in this study. Those with corneal disorders like corneal opacity, degenerations and dystrophies, high myopia with thin sclera, primary or secondary glaucoma, scleral disorders like scleromalacia, scleritis, subluxated lens, history of previous ocular surgeries, traumatic cataract, hypermature cataract were excluded from our study.

METHOD OF COLLECTION OF DATA:

All patients in this study underwent similar protocol. Informed consent was taken for all patients who participated in this study as per the standard protocol. Standard clinical examination which included recording of visual acuity with Snellen's chart, Goldmann Applanation tonometry, slit lamp examination, lacrimal syringing, and fundus evaluation were performed for all patients. Routine blood investigations were done for all participants in this study which included CBC, RBS, HIV, HBsAg, serum urea creatinine.

Preoperative keratometry was measured by using a standard calibrated manual Bausch and Lomb keratometer. Axial length was measured using A-Scan (Appasamy Associates) and intraocular lens power calculation is done using Sanders-Retlaff-Kraff formula II (SRK II).

Similar protocol for preoperative preparation was done for all patients. All patients received Xylocaine test dose, oral tab ciprofloxacin 500mg twice daily and ciprofloxacin 0.3% eye drops 4 times per day one day before the surgery. Before the start of surgery, the pupil was dilated with a combination of tropicamide 0.8% with phenylephrine 5% drops. Flurbiprofen 0.03% drops was used to maintain mydriasis.

All patients underwent MSICS with in the bag PC IOL implantation by a single surgeon. Out of the 96 patients in the study, 48 patients were randomly divided into Group 1 and 2. The straight incision of 6mm which was 2mm from the superior limbus was used in Group 1 and a frown incision of 6mm with the apex of the incision 1.5 mm from the superior limbus and ends of the two limbs 4mm from the limbus was used in Group 2.

Similar protocol for postoperative care was followed for all patients. Postoperative medications included tab ciprofloxacin 500mg given orally twice daily, a combination of ciprofloxacin 0.3% and dexamethasone 0.1% eye drops used for 6 weeks in a tapering dose. Postoperative corneal oedema was treated with sodium chloride 5% eye drops 4 times per day. Cycloplegics like Homatropine 2% and antiglaucoma medications like timolol 0.5% drops were given when required.

Postoperative follow up examination was conducted on day 1, 1st week, 4th week and 6th week. At each visit uncorrected visual acuity (UCVA), best corrected visual acuity (BCVA), careful slit lamp examination and keratometry were performed.

Postoperative follow up examination was conducted on day 1, 1st week, 4th week and 6th week. At each visit uncorrected visual acuity (UCVA), best corrected visual acuity (BCVA), slit lamp examination and keratometry were performed.

The magnitude of astigmatism was classified according to Holmstrom's gradation:9

- No astigmatism, when $<0.25D$
- Non-significant, when it is ≥ 0.25 and $<1.0D$.
- Significant, when it is $\geq 1.0D$ and $<2.0D$
- High, when it is $\geq 2D$

The axes of astigmatism were divided into 3 classes.

- With the rule (minus cylinder at $180^\circ \pm 20^\circ$ or plus cylinder at $90^\circ \pm 20^\circ$)
- Against the rule (minus cylinder at $90^\circ \pm 20^\circ$ or plus cylinder at $180^\circ \pm 20^\circ$)
- Oblique

SIA calculator version 2.1 by Dr Saurabh Sawhney and Dr Aashima Aggarwal was used to calculate the SIA10. The keratometric values were converted to the plus cylinder formats to obtain the requires preoperative and post-operative astigmatism. AstigMATIC, an application which uses Alpini's vector analysis method was used to obtain single angle vector plots of the SIA vector1,12.

STATISTICAL ANALYSIS

Collected data was entered into an Excel spreadsheet with all the quantitative measures like preoperative astigmatism, postoperative

astigmatism, SIA were presented by mean and standard deviation with confidence interval and qualitative data by proportions. Student t test / Mann Whitney U test was used to compare the difference of means. Chi square test was used for testing difference in proportion. Simple linear regression was used to find out the difference in astigmatism and best corrected visual acuity between the two groups. p value less than or equal to 0.05 was considered as statistically significant.

RESULTS

Our study consisted of 96 subjects of which 59(61.5%) were females and 37(38.5%) were males. Group 1 consisted of 29 females (60.4%) and 19 males (39.6%) and the group 2 consisted of 30 females (62.5%) and 18 males (37.5%) (Table 1, Fig 1-2.).

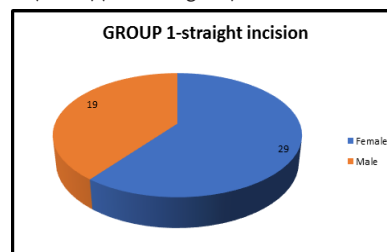


Fig 1: gender distribution in group 1

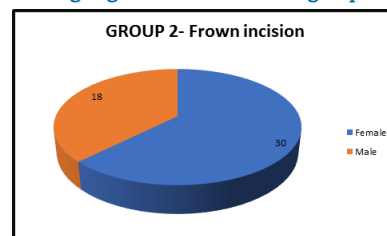


Fig 2: gender distribution in group 2.

TABLE 1. SEX GROUP CROSSTABULATION

	Group			Total
	Straight Incision (group 1)	Frown Incision (group 2)		
SEX	Females	29(60.4%)	30(62.5%)	59(61.5%)
Total	Males	19(39.6%)	18(37.5%)	37(38.5%)
	48(100%)	48(100%)	96(100%)	

TABLE 2. PREOPERATIVE ASTIGMATISM

INCISION	NO ASTIG MATIS M	WTR			ATR			OBLIQUE			TOT AL
		NON SIG	SIG	HIGH SIG	NON SIG	SIG	HIGH SIG	NON SIG	SIG	HIGH SIG	
STRAIGHT (group 1)	2	14	12	7	5	2	3	-	-	3	48
FROWN (group 2)	3	13	9	2	7	5	1	3	2	3	48
TOTAL	5	29	21	9	12	7	4	3	2	6	96

Preoperatively in group 1, 2(4.1%) patients had no astigmatism, 33(68.75%) patients had with-the-rule astigmatism (WTR), 10(20.83%) patients had against-the-rule astigmatism (ATR) and 3(6.25%) patients had oblique astigmatism. 19(39.58%) had non-significant astigmatism, 14(29.17%) had significant astigmatism and 13(27.08%) patients had highly significant astigmatism in group 1. In group 2, 3(6.25%) patients had no astigmatism, 24(50%) patients had WTR astigmatism, 13(27.08%) patients had ATR astigmatism and 8(16.67%) patients had oblique astigmatism. 23(47.9%) had non-significant astigmatism, 16(33.33%) had significant astigmatism and 6(12.5%) patients had highly significant astigmatism in group 2.

The majority of patients in both the groups had with the rule astigmatism preoperatively.

Among the patients with WTR astigmatism in either groups, most people had nonsignificant astigmatism (Table 2).

TABLE 3. POSTOPERATIVE ASTIGMATISM

INCISION	NO ASTIGMAT ISM	WTR			ATR			OBLIQUE			TOTAL
		NON SIG	SIG	HIGH SIG	NON SIG	SIG	HIGH SIG	NON SIG	SIG	HIGH SIG	
STRAIGHT (group 1)	2	5	4	-	10	11	12	-	1	3	48
FROWN (group 2)	3	7	3	-	13	12	3	2	2	3	48
TOTAL	5	12	7	-	23	23	15	2	3	6	96

Postoperatively in group 1, 2(4.1%) patients had no astigmatism, 9(18.75%) patients had WTR astigmatism, 33(68.75%) patients had ATR astigmatism and 4(8.3%) patients had oblique astigmatism. 15(31.25%) had non-significant astigmatism, 16(33.3%) had significant astigmatism and 15(31.25%) patients had highly significant astigmatism in group 1. In group 2, 3 patients had no astigmatism, 10(20.8%) patients had WTR astigmatism, 28(58.33%) patients had ATR astigmatism and 7(14.58%) patients had oblique astigmatism. 22(45.83%) had non-significant astigmatism, 17(35.4%) had significant astigmatism and 6(12.5%) patients had highly significant astigmatism in group 2

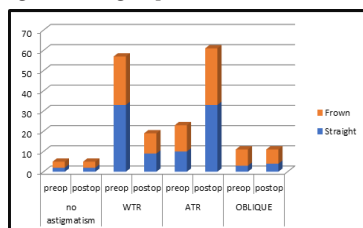


Fig 3: comparison of preoperative and postoperative astigmatism in straight and frown incision.

The majority of patients in both the groups had WTR astigmatism preoperatively. Among the patients with WTR astigmatism in both groups, most people had nonsignificant astigmatism while highly significant WTR astigmatism was nil in both groups. In group 1 the number of patients with highly significant ATR astigmatism was more while it was less in group 2.(Table 3, Fig 3).

TABLE 4: GRADING OF POSTOPERATIVE ASTIGMATISM IN STRAIGHT INCISION

PREOP ASTIGMATISM	Grading of Postop Astigmatism- STRAIGHT INCISION								Total
	HS ATR	HS O	N	NS ATR	NS WTR	S ATR	S O	S WTR	
HS ATR	3	0	0	0	0	0	0	0	3
HS O	0	2	0	0	0	0	1	0	3
HS WTR	0	0	2	0	1	1	0	3	7
N	0	0	0	1	0	1	0	0	2
NS ATR	3	0	0	0	0	2	0	0	5
NS WTR	2	0	0	4	2	6	0	0	14
S ATR	2	0	0	0	0	0	0	0	2
S WTR	2	1	0	5	2	1	0	1	12
Total	12	3	2	10	5	11	1	4	48

7 patients had highly significant with-the-rule astigmatism preoperatively. Following straight incision, 2 patients achieved emmetropia. 14 patients had non-significant WTR astigmatism. Postoperatively, 2 showed a reduction in the magnitude of astigmatism developing non-significant WTR astigmatism, 4 developed non-significant ATR, 6 developed significant ATR and 2 developed highly significant ATR astigmatism.

12 patients had significant WTR astigmatism preoperatively. Postoperatively, 2 showed a reduction of magnitude of astigmatism developing non-significant WTR, 5 developed non-significant ATR astigmatism. 1 developed significant WTR, 1 patient developed significant ATR, 2 developed highly significant ATR and 1 developed highly significant oblique stigmatism.

The patients with ATR astigmatism preoperatively showed an increase

in the ATR astigmatism postoperatively.

2 patients had highly significant oblique astigmatism preoperatively. Postoperatively following straight incision there was no change in the type of astigmatism (Table 4).

Table 5 Grading of Postop Astigmatism in frown incision

PREOP ASTIGMATISM	HS ATR	HS O	N	NS ATR	NS O	NS WTR	S ATR	S O	S WTR	Total
HS ATR	1	0	0	0	0	0	0	0	0	1
HS O	0	2	0	0	0	0	0	1	0	3
HS WTR	0	0	1	0	0	0	0	0	1	2
N	0	0	0	1	0	1	1	0	0	3
NS ATR	0	0	0	1	0	1	5	0	0	7
NS O	0	0	0	2	1	0	0	0	0	3
NS WTR	0	0	1	7	0	4	1	0	0	13
S ATR	2	0	0	0	0	0	3	0	0	5
S O	0	0	0	0	1	0	0	1	0	2
S WTR	0	1	1	2	0	1	2	0	2	9

13 patients had non-significant WTR astigmatism preoperatively. 1 achieved emmetropia postoperatively. 4 patients did not show a change in the type of astigmatism and had non-significant WTR astigmatism postoperatively. 7 developed non-significant ATR and 1 patient developed significant ATR astigmatism.

9 patients had significant WTR astigmatism preoperatively. 1 patient achieved emmetropia postoperatively. 2 developed non-significant ATR, 1 developed non-significant WTR, 2 developed significant ATR, 2 developed significant WTR and 1 developed highly-significant oblique astigmatism.

2 patients had highly significant WTR astigmatism preoperatively. Following frown incision, 1 patient achieved emmetropia. 1 patient developed significant ATR astigmatism postoperatively.

The patients with ATR astigmatism preoperatively showed an increase in the ATR astigmatism postoperatively.

2 patients had non-significant oblique astigmatism preoperatively, following frown incision 2 developed non-significant ATR astigmatism and 1 patient developed non-significant oblique astigmatism. 2 patients had significant oblique astigmatism preoperatively. 1 patient did not show any change in the type of astigmatism and had significant oblique and 1 patient developed non-significant oblique astigmatism postoperatively. 3 patients had highly significant oblique astigmatism. Postoperatively 2 patients showed an increase in the magnitude of astigmatism while 1 patient showed a reduction in the magnitude of astigmatism (Table 5).

Table 6. Results of cartesian coordinate based analysis in straight incision

	ARITHMETIC MEAN OF MAGNITUDE OF ASTIGMATISM	CENTROID	COHERENCE (%)
PREOPERATIVE ASTIGMATISM	1.26 D	0.67X830	56
POSTOPERATIVE ASTIGMATISM	1.52 D	0.77X70	59
SURGICALLY INDUCED ASTIGMATISM	1.69 D	1.4x10	90

The mean magnitude of preoperative astigmatism in straight incision was 1.26 ± 0.92 D. The mean axis of preoperative astigmatism in straight incision was 85.94 ± 45.71 . The mean magnitude of postoperative astigmatism in straight incision was 1.52 ± 1.17 D. The mean axis of postoperative astigmatism in straight incision was 96.5 ± 74.9 D. The mean magnitude of SIA in straight incision was 1.69 ± 0.82 D. The mean axis of SIA in straight incision was 87.88 ± 60.94 . The centroid value (mean SIA vector) of preoperative astigmatism in group 1 with straight incision is 0.67×830 with a coherence of 56% and that

of postoperative astigmatism is 0.77X70 with a coherence of 59%. The centroid of SIA for straight incision is 1.4x10 with a coherence of 90% (Table 6).

Table 7. Results of cartesian coordinate based analysis in frown incision

	ARITHMETIC MEAN	CENTROID	COHERENCE (%)
PREOPERATIVE ASTIGMATISM	0.98 D	0.35X790	31
POSTOPERATIVE ASTIGMATISM	0.99 D	0.16X370	15
SURGICALLY INDUCED ASTIGMATISM	0.61 D	0.37X20	60

The mean magnitude of preoperative astigmatism in frown incision was 0.98 ± 0.83 D. The mean axis of preoperative astigmatism in frown incision was 85.94 ± 51.94 . The mean magnitude of postoperative astigmatism in frown incision was 0.99 ± 0.82 D. The mean axis of postoperative astigmatism in frown incision was 74.96 ± 68.78 D. The mean magnitude of SIA in frown incision was 0.61 ± 0.35 D. The mean axis of SIA in frown incision was 83.75 ± 62.37 . The centroid value of preoperative astigmatism in group 2 with frown incision is 0.35×790 with a coherence of 31% and that for postoperative astigmatism is 0.16×370 with a coherence of 15%. The centroid of SIA for frown incision is 0.37×20 with a coherence of 60%.

DISCUSSION

In a study by Kaufmann et al., which compared the flattening effect of LRI group and on-axis incision group, the flattening after 6 months of follow up in LRI group was 1.1 D (range 0.15- 0.78) and in the on-axis incision group was 0.35 D (range 0.0-0.96 D)13.

Tefedor J et al., studied the refractive change caused by 2.8 mm corneal incision in different locations in phacoemulsification. He concluded that temporal incisions are preferred for negligible astigmatism. Nasal and superior incisions are preferred when steep axis is located at 180 and 900 respectively. the superior and nasal incision induce more astigmatism than temporal incisions14.

In a study by He W et al., comparing the clinical efficacy of implantation of Toric IOL with steep- axis incision and non-steep axis incision, the residual astigmatism of steep-axis and non- steep axis incision group were -0.61 ± 0.27 D and -0.66 ± 0.37 D respectively 3 months after surgery and was not found to be statistically significant15.

In the study by Chawla N et al., comparing the astigmatism correction after on axis incision and an additional limbal relaxing incision during phacoemulsification, it was observed that limbal relaxing incision reduce the corneal astigmatism of mild and moderate degree of up to 1.0 D with a predictable accuracy when compared to incision on the steep meridian16.

In the prospective study by Mohammad H et al., comparing the correction of astigmatism with limbal relaxing incision, extended on-axis incision and toric IOL. The SIA of limbal relaxing incision, extended on- axis incision and toric IOL after 24 weeks postoperatively was 2.43 ± 1.62 , 1.34 ± 1.29 and 2.54 ± 1.21 respectively. There was no significant difference between the correction success obtained with any of the 3 methods17.

CONCLUSION

Both frown and straight incisions may be used to reduce postoperative astigmatism.

The mean magnitude of postoperative astigmatism in straight incision was 1.52 ± 1.17 D. The mean axis of postoperative astigmatism in straight incision was 96.5 ± 74.9 D.

The mean magnitude of postoperative astigmatism in frown incision was 0.99 ± 0.82 D. The mean axis of postoperative astigmatism in frown incision was 74.96 ± 68.78 D.

The magnitude of postoperative astigmatism was greater in straight

incision when compared to frown incision and the difference was statistically significant.

Straight incision should be used for highly significant and significant WTR astigmatism while frown may be used for significant astigmatism and non-significant WTR astigmatism.

The magnitude of induced astigmatism and its meridian may vary from surgeon to surgeon.

REFERENCES

1. Sabanayagam C, Cheng C-Y. Global causes of vision loss in 2015: are we on track to achieve the Vision 2020 target? *Lancet Glob Health* 2017;5:1164–5.
2. Hashemi H, Fotouhi A, Yekta A, Pakzad R, Ostadimoghaddam H, Khabazkhoob M. Global and regional estimates of prevalence of refractive errors: Systematic review and meta-analysis. *J Curr Ophthalmol* 2018;30:3–22.
3. Raju P, Ve Ramesh S, Arvind H, George R, Baskaran M, Paul PG, et al. Prevalence of Refractive Errors in a Rural South Indian Population. *Invest Ophthalmology Vis Sci* 2004;45:4268.
4. Venkataraman A, Kalpana. Visual outcome and rotational stability of open loop toric intraocular lens implantation in Indian eyes. *Indian J Ophthalmol* 2013;61:626–9.
5. Wang MX, Swartz TS. Irregular Astigmatism: Diagnosis and Treatment. 1st ed. Danvers: SLACK Incorporated; 2008. 326.
6. Kapoor G, Singh A, Baranwal V, Kalra N. Six month Rotational stability of Acrysof Toric Intraocular Lens. *Med J Armed Forces India* 2019;
7. Rastogi A, Khanam S, Goel Y, Kamlesh, Thacker P, Kumar P. Comparative evaluation of rotational stability and visual outcome of toric intraocular lenses with and without a capsular tension ring. *Indian J Ophthalmol* 2018;66:411.
8. Potvin R, Kramer BA, Hardten DR, Berdahl JP. Toric intraocular lens orientation and residual refractive astigmatism: an analysis. *Clin Ophthalmol* 2016;10:1829-36.
9. Holmstrom G, el Azazi M, Kugelberg U. Ophthalmological follow up of preterm infants: a population based, prospective study of visual acuity and strabismus. *Br J Ophthalmol* 1999;83:143–50.
10. Aggarwal A, Sawhney S. About Insight Eye Clinic [Internet]. [cited 2019 Nov 19]. Available from: https://www.insighteyeclinic.in/SIA_calculator.php
11. AstigMATIC Software and trial datasets for BMC Ophthalmology peer-review [Internet]. [cited 2019 Nov 19]. Available from: <https://www.lasikmd.com/media/astigmatic/index.php>
12. Gauvin M, Wallerstein A. AstigMATIC: an automatic tool for standard astigmatism vector analysis. *BMC Ophthalmol* 2018;18:255.
13. Kaufmann C, Peter J, Ooi K, Phipps S, Cooper P, Goggin M. Limbal relaxing incisions versus on-axis incisions to reduce corneal astigmatism at the time of cataract surgery. *J Cataract Refract Surg* 2005;31:2261–5.
14. Tejedor J, Pérez-Rodríguez JA. Astigmatic Change Induced by 2.8-mm Corneal Incisions for Cataract Surgery. *Invest Ophthalmol Vis Sci* 2009;50:989–94.
15. He W, Zhu X, Du Y, Yang J, Lu Y. Clinical efficacy of implantation of toric intraocular lenses with different incision positions: a comparative study of steep-axis incision and non-steep-axis incision. *BMC Ophthalmol* 2017;17:132.
16. Chawla N. Comparison of Astigmatism Correction After On Axis Incision and an Additional Limbal Relaxing Incision During Phacoemulsification. *Delhi J Ophthalmol* 2017;27:314–5.
17. Mohammad-Rabei H, Mohammad-Rabei E, Espandar G, Javadi M, Jafarinasab M, Hashemian S, et al. Three methods for correction of astigmatism during phacoemulsification. *J Ophthalmic Vis Res* 2016;11:162.