



Choanal Polyps Originating from Unusual Sites: A Rural Tertiary Care Center Experience

Lini Joseph¹ K. C. Prasad¹ Prashanth Babu¹ N. Harshitha¹

¹ Department of Ear, Nose, and Throat, Sri Devaraj Urs Medical College, Tamaka, Kolar, Karnataka, India.

Address for correspondence Lini Joseph, MBBS, Department of ENT and HNS, Sri Devaraj Urs Medical College, Tamaka, Kolar, Karnataka, India (e-mail: linijomedico@gmail.com).

Int Arch Otorhinolaryngol 2022;26(4):e683–e687.

Abstract

Introduction Choanal polyps are benign lesions arising from the sinonasal mucosa, extending through the choana into the nasopharynx. Though polyps arising from the maxillary sinus and extending to the choana are common, polyps arising from the sphenoid sinus ostium, posterior part of middle turbinate, and inferior and middle meatus are quite uncommon.

Objective To document the site of origin of choanal polyps arising from unusual sites; their clinical, radiological, and histopathological characteristics, as well as diagnostic challenges and management.

Methods This retrospective, single-center study included 14 patients aged 16 to 75-years-old with choanal polyps. After obtaining informed consent, their clinical, radiological and surgical details and histopathology reports were reviewed. Patients were followed for at least 6 months after surgery.

Results The predominant symptoms were unilateral nasal obstruction ($n = 9$), snoring, rhinorrhea, and epistaxis. Though anterior rhinoscopy was unremarkable, a mass could be visualized during posterior rhinoscopy in the nasopharynx in 11 patients, and a mass could be directly visualized in the oropharynx in 2 patients. After diagnostic by nasal endoscopy, these polyps were noted to arise from the posterior aspect of the middle meatus ($n = 6$), middle turbinate ($n = 3$), posterior septum ($n = 3$), sphenoid sinus ostium ($n = 1$), and inferior meatus ($n = 1$). All patients were managed surgically. The histopathological examination revealed inflammatory polyp ($n = 12$), actinomycosis ($n = 1$), and rhinosporidiosis ($n = 1$). Patients were followed up for 6 to 22 months. We observed no complications or recurrence.

Conclusion Diagnostic nasal endoscopy should be performed in all patients presenting with nasal obstruction, to rule out choanal polyps arising from unusual sites. Complete polyp removal and appropriate treatment based on histopathology prevents recurrence.

Keywords

- ▶ nasal polyp
- ▶ actinomycosis
- ▶ nasal septum
- ▶ sphenoid sinus
- ▶ rhinosporidiosis
- ▶ endoscopic excision

Introduction with Objectives

Choanal polyps are benign, soft tissue lesions which arise from nasal or paranasal sinus mucosa and extend through the choana into the nasopharynx.¹ Choanal polyps represent

approximately 4 to 6% of all nasal polyps.² Although most choanal polyps are of inflammatory etiology, their exact pathogenesis is still not clear. Allergy, atopy, venous obstruction, and infections are thought to play a role in the etiopathogenesis of choanal polyps.

received
April 28, 2021
accepted after revision
December 14, 2021
published online
May 12, 2022

DOI <https://doi.org/10.1055/s-0042-1742768>.
ISSN 1809-9777.

© 2022. Fundação Otorrinolaringologia. All rights reserved.
This is an open access article published by Thieme under the terms of the Creative Commons Attribution-NonDerivative-NonCommercial-License, permitting copying and reproduction so long as the original work is given appropriate credit. Contents may not be used for commercial purposes, or adapted, remixed, transformed or built upon. (<https://creativecommons.org/licenses/by-nc-nd/4.0/>)
Thieme Revinter Publicações Ltda., Rua do Matoso 170, Rio de Janeiro, RJ, CEP 20270-135, Brazil

Patients with choanal polyps often present with unilateral or bilateral nasal obstruction, snoring, nasal discharge, headache, and epistaxis. Though antrochoanal polyps, that is polyps arising from the maxillary sinus and extending to the choana, are more common, polyps arising from sphenoid sinus ostium, posterior part of middle turbinate, posterior nasal septum, and the most posterior part of the inferior and middle meatus are quite uncommon. Polyps arising from these uncommon sites are often missed in anterior rhinoscopy and pose a diagnostic challenge to clinicians. There are very few studies in literature that describe choanal polyps originating from these unusual sites, posteriorly in the nasal cavity.

We have encountered polyps originating from unusual areas in the posterior part of nasal cavity, which were missed on anterior rhinoscopy but could be visualized on posterior rhinoscopy. Furthermore, a detailed diagnostic nasal endoscopic examination could be used to identify the site of origin of these polyps. The aim of this study is to document the site of origin of choanal polyps arising from unusual sites in the posterior part of the nasal cavity, as well as to describe their clinical, radiological and histopathological characteristics, diagnostic challenges, and management.

Method

In this retrospective study conducted at the Sri Devaraj URS Medical College and Research Center, we enrolled 14 patients with an age range from 16 to 75-years-old, who were diagnosed to have choanal polyps and treated between 2016 and 2019. Patients with previous history of nasal trauma, and nasal or paranasal sinus surgeries were excluded. A written informed consent was obtained from the study participants to use their clinical data. The presenting symptoms, past history, clinical examination details, nasal endoscopy findings, and radiological details of these patients were retrospectively reviewed. Details of surgery, intraoperative findings, and histopathology reports of these patients were reviewed. Patients were followed for a minimum period of 6 months after the surgery. The study was approved by the Institutional Ethics Committee (Id: DMC/KLR/IEC/308/2020).

Result

A total of 14 patients from 16 to 75-years-old, 12 of which were males and 2 females, with diagnosed choanal polyps were enrolled in our study. (► **Table 1**) The majority of patients ($n=9$) presented with unilateral nasal obstruction

Table 1 Table showing the age distribution of patients who presented with choanal polyp

Age group	No. of patients
16–30 years	2
31–45 years	7
46–60 years	4
60–75 years	1

Table 2 Chief presenting complaints of patients who presented with choanal polyp

Chief complaint	No. of patients	Percentage (%)
Bilateral nasal obstruction	2	14.2
Unilateral nasal obstruction	9	64.2
Snoring	8	57.1
Rhinorrhea	5	35.7
Epistaxis	2	14.2
Hyposmia	7	50

as the chief complaint. (► **Table 2**) Anterior rhinoscopic examination was unremarkable in all the cases. On posterior rhinoscopy, a polypoidal mass could be visualized in the nasopharynx in most of the patients ($n=12$) and a bulky mass could be directly visualized in the oral cavity in two patients. In 12 patients the polyp was unilateral and in 2 patients, bilateral polyposis was seen. Associated anatomical abnormalities, such as deviated nasal septum, were also noted in 10 patients with unilateral polyp. In all these patients, after meticulous nasal endoscopic examination, the polyp was found to be arising from unusual sites in the posterior part of the nasal cavity. (► **Table 3**)

On detailed diagnostic nasal endoscopy, 6 polyps were found to be arising from the posterior part of the middle meatus, of which one polyp looked yellowish and bulky, protruding between the middle turbinate and the uncinate process, touching the floor of nose and the nasal septum, and extending posteriorly into the choana. (► **Fig. 1**) These patients underwent functional endoscopic sinus surgery and the polypoidal mass was sent for histopathological examination. The suspicious yellowish mass had features suggestive of actinomycosis, for which the patient was started on doxycycline. All 6 patients were regularly followed up in our outpatient facility, and none of them had recurrence.

We encountered 3 septochoanal polyps attached to the posterior part of the nasal septum by a thick, long stalk which extended to the nasopharynx. (► **Fig. 2**) Patients were taken to

Table 3 Site of origin of choanal polyp in the nasal cavity

Origin of the polyp	No. of patients
Posterior part of middle meatus	6
Posterosuperior part of nasal septum	2
Posteroinferior part of nasal septum	1
Posteromedial aspect of middle turbinate	1
Posterolateral aspect of middle turbinate	1
Posteroinferior part of middle turbinate	1
Inferior meatus	1
Sphenoid sinus ostium	1

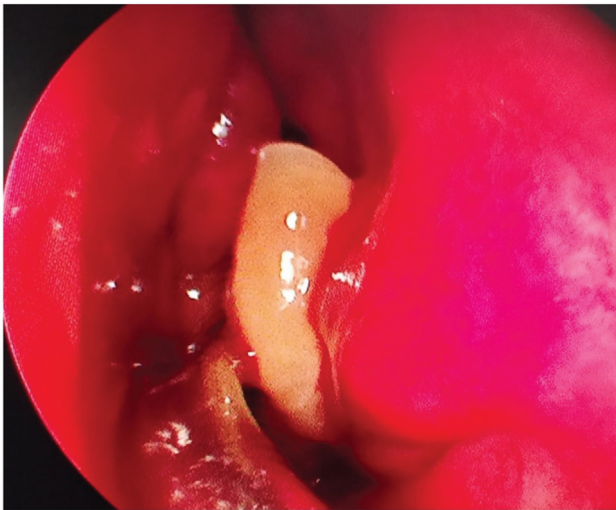

Fig. 1 Yellowish polypoid mass arising from the posterior part of middle meatus which on histopathology revealed actinomycosis.

the operating room and the polyp was excised endoscopically. The base of the stalk was cauterized using bipolar cautery.

The polyp was found to be arising from mucosa over the posterior aspect of the middle turbinate in 3 patients. The mass could be probed all around except at its attachment to the middle turbinate. The polyp extended far posteriorly through the choana, obstructing bilateral choanae and extending into the nasopharynx.

In a 47-year-old male patient, a reddish bossellated mass was seen arising from the inferior meatus by a short, narrow pedicle, very close to the opening of the nasolacrimal duct, and extending posteriorly into the oropharynx. (► **Fig. 3**) Functional endoscopic sinus surgery was done, and histopathology revealed rhinosporidiosis. The patient was treated using dapsone 100 mg once daily for a period of 6 months. On follow-up visits, there were no signs of recurrence.

In an elderly patient who came to our outpatient facility with complaints of snoring and throat irritation, the polyp was found to be arising from the mucosa near the sphenoid sinus ostium via a slender, long stalk extending to the nasopharynx and

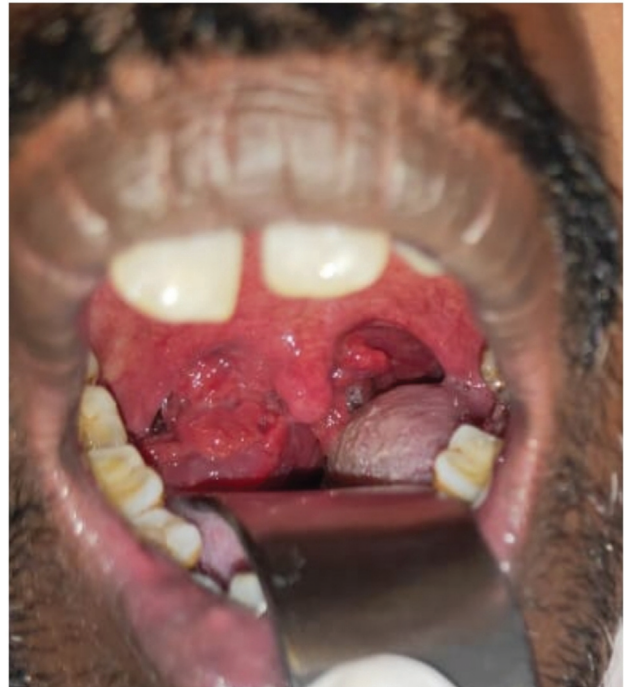


Fig. 3 Reddish bossellated mass extending into oropharynx.

leading to a bulky polypoid mass extending to the oropharynx. (► **Fig. 4**) Endoscopic excision was done, followed by cauterization of the base of the stalk under general anesthesia.

Diagnostic imaging was performed in all these patients in the form of computed tomography (CT) with axial and coronal cuts to identify the site of origin of the polyp, to assess the extent of the polyp, and for surgical planning. The findings were remarkable, especially in patients with septochoanal and sphenchoanal polyps where a thin long stalk could be identified arising from the posterior choana leading to a large homogenous opacity in the nasopharynx or oropharynx. (► **Fig. 5**) Patients with sphenchoanal polyps had minimal mucosal thickening in the sphenoid sinus, whereas the rest of the sinuses were free from pathology. In 9 of the patients with choanal polyps, mucosal thickening was

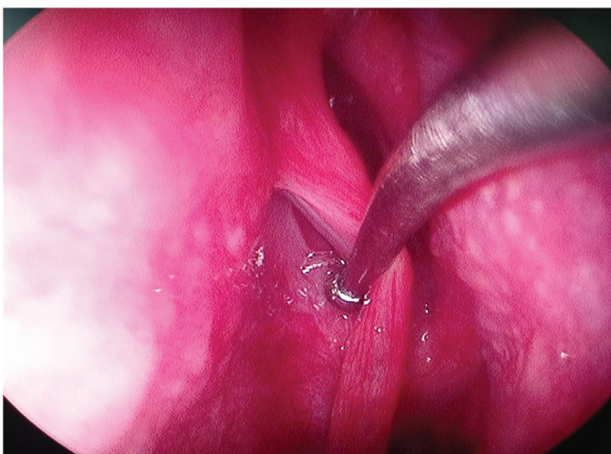


Fig. 2 Thick stalk of septochoanal polyp extending through the choana into the nasopharynx.

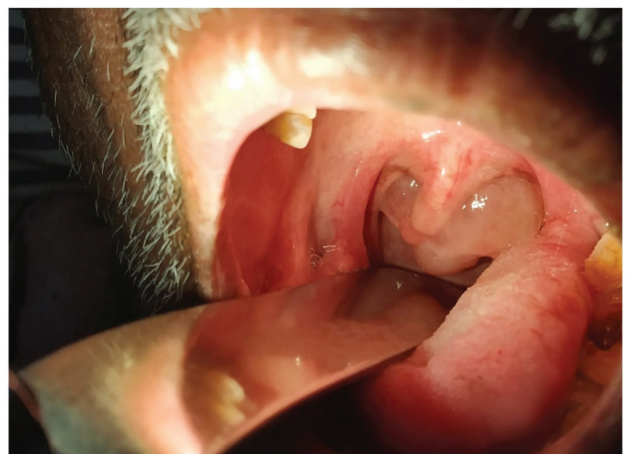

Fig. 4 Oropharyngeal extension of sphenchoanal polyp.

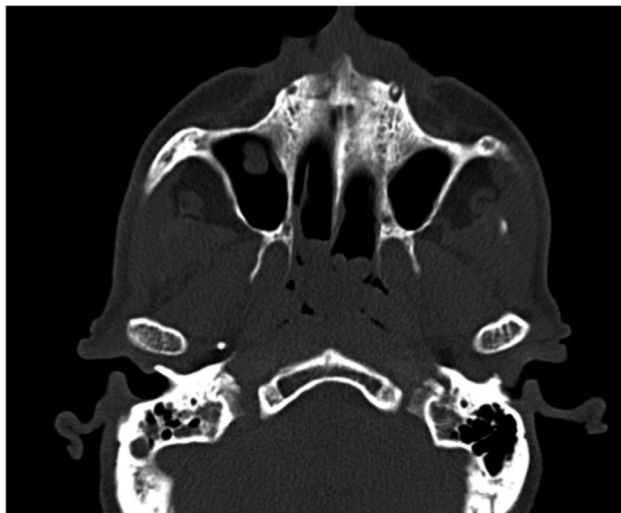


Fig. 5 Computed tomography (coronal view) of paranasal sinuses showing the stalk of sphenchoanal polyp appearing as a bulbous projection close to the sphenoid ostium, in the sphenothmoidal recess and a homogenous mass in the sphenoid sinus.

present in all 4 sinuses; however, there was no evidence of mass or polyps within the sinus of these patients.

Among the 14 patients in our study, 5 patients had history of allergic symptoms in the past, and 12 patients gave family history of nasal allergy. In 12 of the 14 patients, histopathology revealed inflammatory polyps, of which 7 patients had eosinophilic infiltration. All patients were followed up for 6 to 22 months after treatment (mean follow-up time of 18 months). None of the patients had any postoperative complications or recurrence.

Discussion

Choanal polyp was originally described by Killian in 1906.³ Patients with choanal polyps often present with nasal obstruction, nasal discharge, snoring, headache, epistaxis, and obstructive sleep apnea. Among choanal polyps, antrochoanal polyps are the most common. This may be due to the closely opposing mucosal surfaces and turbulent airflow in the ostiomeatal complex region.⁴ The Bernoulli phenomenon and gravity are likely related to nasopharyngeal extension of the choanal polyps. Local inflammation due to allergy or infection may be a predisposing factor for polyp formation in unusual sites. Many patients in our study gave a history of allergic symptoms in the past. Allergic rhinitis and previous recurrent respiratory tract infections might have caused local inflammatory changes over the nasal mucosa and made them more predisposed to polyp formation.

Most choanal polyps in our study exhibited smooth, well-defined, greyish-white appearance, which is consistent with simple nasal polyps in both gross and microscopic appearance. Eosinophils are usually more likely to be present in polyps arising from middle meatus, when compared to those found in antrochoanal polyps. In our study, eosinophilic infiltration of polyp was present in 5 patients, all cases with the polyp arising from the middle meatus.

Clinical symptoms for choanal polyps are often same as those caused by antrochoanal polyps.⁵ In our study most patients presented with bilateral nasal obstruction. A case of asymptomatic choanal polyp was reported in 2016, which was identified due to the problems it posed to intubation prior to an unrelated surgery. The polyp was arising from the posterior ethmoid sinus and was later removed by endoscopic polypectomy.⁶ In our patients, intubation could be performed with minimal difficulty.

Actinomycosis is an infection caused by *Actinomyces israelii*, which is a gram-negative anaerobic bacteria. It commonly causes cervicofacial, thoracic, and abdominal infections. Actinomycosis affecting the nasal mucosa is relatively rare; literature says that it is more likely to occur in immunocompromised patients, in the presence of mucosal injury and copathogens.⁷ However, our patient was not immunocompromised. The antibiotics effective in treatment of actinomycosis are penicillin, tetracycline, cephalosporins, macrolides, imipenem. Treatment duration varies from 6 weeks to 1 year depending on the severity of the infection.⁸ Our patient was treated with doxycycline for 6 weeks.

Rhinosporidiosis is an infection caused by *Rhinosporidium seeberi*, grouped under the class mesomycetozoa. It is primarily a water borne disease. The characteristic appearance of whitish dots over a red mass was not prominent in our case. Another case of rhinosporidiosis being found incidentally in a patient with nasal polyposis was reported by Manickam et al. in 2015; it was diagnosed after postoperative histopathological examination, which helped in embarking on appropriate treatment postsurgery. When encountering a reddish fleshy mass in unusual sites of nasal cavity, which is insensitive and bleeds on touch, the possibility of sinonasal malignancy, papilloma, hemangioma, and tuberculosis should also be kept in mind.⁹ Diagnosis of rhinosporidiosis should be considered in such cases, especially in endemic areas. Diagnosis should be confirmed by histopathological examination. Dapsone may be administered to prevent recurrence. Our patient was treated with dapsone for a period of 6 months postoperatively, and there was no recurrence of infection.

Polyps arising from the middle turbinate are very rare. We encountered 3 such cases, one of which actually mimicked an antrochoanal polyp, but through detailed nasal endoscopy, it's origin from the middle turbinate was confirmed. In all 3 cases, the bilateral ostiomeatal complex were clear and both maxillary sinuses were free from polyps, which was similar to the observations of Özcan et al. in 2004, and Gupta and Singh in 2013.^{10,11}

Sphenchoanal polyps refer to polyps arising from mucosa covering the anterior wall of the sphenoid sinus, near the sphenoid sinus ostium or from the sphenothmoidal recess, and extending into the choana. In their study on sphenchoanal polyps, Lim and Sdralis concluded that sphenchoanal polyps may be more common than believed, because most of them are small and asymptomatic, and some may regress spontaneously.¹² A case of sphenchoanal polyps reported by Kesarwani et al. mentioned the possibility of these polyps being missed on anterior rhinoscopy and misdiagnosed as nasal obstruction due to deviated nasal septum, especially in the presence of a septal spur.⁵ In our patient, as the stalk of the

polyp was slender and originated far posteriorly in the nasal cavity, close to the sphenoid sinus ostium, it was not visualized on anterior rhinoscopy and the site of origin became evident only after detailed nasal endoscopic examination. Hence, in all cases presenting with recent onset of nasal obstruction and snoring, a detailed nasal endoscopy is mandatory as the possibility of sphenochoanal polyp cannot be excluded.

Septochoanal polyps are polyps arising from the posterior part of the nasal septum and extending posteriorly into the choana. Stammberger reported 3 cases of septochoanal polyps arising from the posterior nasal septum in 1990.¹³ A case of septochoanal polyp was reported by Birkent et al. in 2009.³ It is often found to be attached to the posterior part of the septum by a narrow pedicle, which was the case in our study. Endoscopic excision of the polyp, with cauterization of the base of the pedicle and correction of septal deviation, if present, is the recommended treatment, which was done in all 3 patients at our institution.

A series reported in 2015 included 4 choanal polyps arising from unusual sites. They reported 2 polyps arising from the nasal septum, 1 polyp from the sphenoethmoidal recess, and a polyp from the inferior turbinate. The author emphasizes the rarity of polyps arising from the lateral wall of the nose and suggests combined use of diagnostic nasal endoscopy and CT for diagnosis and treatment planning for these cases.¹⁵ A case of sphenochoanal polyp reported in Turkey in 2014, which was found to be arising from the sphenoid sinus and extending into the nasopharynx, was also managed in the same way as in our study, by widening the sinus ostium and removal of the polyp through endoscopic approach.¹⁶

In 2008, Chen and Yanagisawa reported a case of polyp in a 14-year-old girl who presented with symptoms of nasal obstruction and snoring. Using CT axial cuts, the polyp was found to be arising from the posterior part of the choana, with mild mucosal thickening in the sinuses and the ostio-meatal complex being free from obstruction, which was similar to our study.¹⁷

Choanal polyps are quite obscure within the nasal cavity due to their far posterior location, which explains why they are often missed on routine clinical examinations, including anterior rhinoscopy. Visualization may further be hampered by the presence of anatomical abnormalities, such as septal spur, and this may lead to misdiagnosis. Clinicians' awareness about the existence of choanal polyps from unusual sites may help in diagnosis of rare septochoanal or sphenochoanal polyps causing snoring and sleep disturbances. In all patients presenting with nasal obstruction or swallowing difficulties, a diagnostic nasal endoscopy should necessarily be performed together with an imaging modality like CT, to avoid missing the diagnosis of unusual choanal polyps. Detecting the site of origin is of utmost importance, as complete removal of the polyp and cauterization or removal of the mucosa over which the pedicle of septochoanal or sphenochoanal polyp is attached are necessary to prevent recurrence. Histopathological examination should be done in all the patients, keeping in mind the possibility of inverted papilloma, actinomycosis, and rhinosporidiosis in these rare polyps. In elderly patients, malignancy should be excluded.

Conclusion

Choanal polyps can arise from anywhere in the nasal mucosa. Clinicians should remember that choanal polyps can originate from unexpected sites in the nasal cavity. Detection of the site of origin of choanal polyps by a thorough nasal endoscopy and imaging techniques is crucial for planning the surgery. Early diagnosis of etiology of choanal polyp by histopathological examination allows for appropriate treatment postoperatively, which has a bearing on treatment results and prognosis.

Conflict of Interests

The authors have no conflict of interests to declare.

References

- 1 Perić A, Vukadinović T, Kujundžić T, Labus M, Stoiljkov M, Đurđević BV. Choanal polyps in children and adults: 10-year experience from a tertiary care hospital. *European Archives of Oto-Rhino-Laryngology* 2019 Jan;276(01):107–113
- 2 Segal N, Gluk O, Puterman M. Nasal polyps in the pediatric population. *B-ENT* 2012;8(04):265–267
- 3 Killian G. The origin of choanal polyp. *The Lancet* 1906 Jul 14;168 (4324):81–82
- 4 Naik MS, Naik SM. An unusual presentation of nasal polyp arising from floor of nasal cavity. *Otolaryngology Clinics: An International Journal*. 2011;3(02):129–131
- 5 Kesarwani A, Kaushal D, Singh RK, Goyal A. Sphenochoanal Polyp: A Rare Entity with Review of Literature. *J Otolaryngol ENT Res*. 2017;8(04):00251
- 6 Hori Y, Taniguchi K, Okabe T, Sakamoto A. A case of unexpectedly difficult intubation caused by a large asymptomatic choanal polyp. *JA Clin Rep* 2016;2(01):2
- 7 Ouertatani L, Jebilaoui Y, Kharrat S, Sahtout S, Besbes G. Nasopharyngeal actinomycosis. *Case Rep Otolaryngol* 2011; 2011:367364
- 8 Sánchez Legaza E, Cercera Oliver C, Miranda Caravalló JL. Actinomycosis of the paranasal sinuses. *Acta Otorrinolaringol Esp* 2013; 64(04):310–311
- 9 Loh KS, Chong SM, Pang YT, Soh K. Rhinosporidiosis: differential diagnosis of a large nasal mass. *Otolaryngol Head Neck Surg* 2001; 124(01):121–122
- 10 Özcan C, Duce MN, Görür K. Choanal polyp originating from the middle turbinate. *Eur Arch Otorhinolaryngol* 2004;261(04): 184–186
- 11 Gupta M, Singh S. Choanal polyp arising from middle turbinate. *Clinical Rhinology. Int J* 2013;6:124–125
- 12 Lim WK, Sdralis T. Regression of a sphenochoanal polyp in a child. *Laryngoscope* 2004;114(05):903–905
- 13 Stammberger H, Posawetz W. Functional endoscopic sinus surgery. *European Archives of Oto-rhino-laryngology* 1990 Mar;247 (02):63–76
- 14 Birkent H, Karahatay S, Durmaz A, Kurt B, Tosun F. Choanal polyp originating from the nasal septum: septochoanal polyp. *Kulak Burun Bogaz Ihtis Derg* 2009;19(03):163–166
- 15 Manickam A, Sengupta S, Ghosh D, Halder S. Choanal Polyps of Unusual Presentation—A Series of 4 Cases. *Global Journal of Medical Research: J Dentistry and Otolaryngology*. 2015;15(02)
- 16 Özdek A, Özel HE. Unusual presentations of choanal polyps: report of 3 cases. *Ear Nose Throat J* 2014;93(02):E10–E13
- 17 Chen E, Yanagisawa E. An unusually large choanal polyp that almost completely obstructed the oropharyngeal airway. *Ear Nose Throat J* 2006;85(08):474–476