"NON-VENEREAL DERMATOSES OF FEMALE GENITALIA" - A CLINICAL STUDY

By

Dr. MUKTAMANI GURUMAYUM

DISSERTATION SUBMITTED TO SRI DEVARAJ URS ACADEMY OF HIGHER EDUCATION AND RESEARCH CENTER, KOLAR, KARNATAKA

IN PARTIAL FULFILLMENT OF THE REQUIREMENTS FOR THE DEGREE OF

DOCTOR OF MEDICINE
IN
DERMATOLOGY, VENEREOLOGY AND LEPROSY

Under the guidance of

Dr. SHIVAKUMAR.V MD, DNB
Professor

DEPARTMENT OF DERMATOLOGY, VENEREOLOGY AND LEPROSY
SRI DEVARAJ URS MEDICAL COLLEGE AND RESEARCH CENTER, TAMAKA, KOLAR- 563101

2014

SRI DEVARAJ URS ACADEMY OF HIGHER EDUCATION AND RESEARCH CENTER, TAMAKA, KOLAR, KARNATAKA

DECLARATION BY THE CANDIDATE

I hereby declare that this dissertation entitled "**NON-VENEREAL DERMATOSES OF FEMALE GENITALIA - A CLINICAL STUDY**" is a bonafide and genuine research work carried out by me under the guidance of **Dr. SHIVAKUMAR V**, Professor, Department of Dermatology, Venereology and Leprosy, Sri Devaraj Urs Medical College & Research Center, Kolar, in partial fulfillment of University regulation for the award "**M.D. DEGREE IN DERMATOLOGY, VENEREOLOGY AND LEPROSY**", in the examination to be held in April, 2014 by SDUAHER.

This has not been submitted by me previously for the award of any degree or diploma from the university or any other university.

Date:

Place: Kolar **Dr. MUKTAMANI GURUMAYUM**

SRI DEVARAJ URS ACADEMY OF HIGHER EDUCATION AND RESEARCH CENTER, TAMAKA, KOLAR, KARNATAKA

CERTIFICATE BY THE GUIDE

This is to certify that the dissertation entitled **"NON-VENEREAL DERMATOSES OF FEMALE GENITALIA - A CLINICAL STUDY"** is a bonafide research work done by **Dr. MUKTAMANI GURUMAYUM** in partial fulfillment of the requirement for the Degree of **DOCTOR OF MEDICINE** in **DERMATOLOGY, VENEREOLOGY AND LEPROSY.**

Date :

Place : Kolar

SIGNATURE OF THE GUIDE

Dr. SHIVA KUMAR. V

Professor

Department Of Dermatology,Venereology, & Leprosy,

Sri Devaraj Urs Medical College, & Research Center,Tamaka, Kolar.

SRI DEVARAJ URS ACADEMY OF HIGHER EDUCATION AND RESEARCH CENTER, TAMAKA, KOLAR, KARNATAKA

ENDORSEMENT BY THE HEAD OF THE DEPARTMENT

This is to certify that the dissertation entitled ***" NON-VENEREAL DERMATOSES OF FEMALE GENITALIA - A CLINICAL STUDY "*** *is a bonafide research work done by* ***Dr. MUKTAMANI GURUMAYUM*** *under the guidance of* ***Dr. SHIVA KUMAR V****, Professor, Department Of Dermatology, Venereology and Leprosy.*

Dr. RAJENDRA OKADE **MD, DNB**
Professor & HOD,
Department of Dermatology,
Venereology & Leprosy
Sri Devaraj Urs Medical College,
& Research Center, Tamaka,
Kolar

Date:
Place: Kolar

SRI DEVARAJ URS ACADEMY OF HIGHER EDUCATION AND RESEARCH CENTER, TAMAKA, KOLAR, KARNATAKA

ENDORSEMENT BY THE HOD AND PRINCIPAL

This is to certify that the dissertation entitled ***"NON-VENEREAL DERMATOSES OF FEMALE GENITALIA - A CLINICAL STUDY"*** *is a bonafide research work done by* ***Dr. MUKTAMANI GURUMAYUM*** *under the guidance of* ***Dr. SHIVA KUMAR V****, Professor, Department Of Dermatology, Venereology and Leprosy.*

Dr. RAJENDRA OKADE MD, DNB
Professor & HOD,
Department of Dermatology,
Venereology & Leprosy
Sri Devaraj Urs Medical College,
& Research Center, Tamaka,
Kolar

Dr. M. B. SANIKOP MS
Principal,
Sri Devaraj Urs Medical College,
& Research Center,Tamaka,
Kolar

Date:
Place: Kolar

Date:
Place: Kolar

SRI DEVARAJ URS ACADEMY OF HIGHER EDUCATION AND RESEARCH CENTER, TAMAKA, KOLAR, KARNATAKA

ETHICAL COMMITTEE CERTIFICATE

This is to certify that the Ethical committee of Sri Devaraj Urs Medical College & Research Center, Tamaka, Kolar has unanimously approved

Dr. MUKTAMANI GURUMAYUM

Post - Graduate student in the Department of

DERMATOLOGY, VENEREOLOGY AND LEPROSY,

at Sri Devaraj Urs Medical College & Research Center, Kolar

to take up the Dissertation work entitled

"NON-VENEREAL DERMATOSES OF FEMALE GENITALIA

- A CLINICAL STUDY"

to be submitted to the

SRI DEVARAJ URS ACADEMY OF HIGHER EDUCATION AND RESEARCH CENTER, TAMAKA, KOLAR, KARNATAKA,

Date :
Place : Kolar

Member Secretary
Sri Devaraj Urs Medical College & Research Center,Tamaka, Kolar–563101

SRI DEVARAJ URS ACADEMY OF HIGHER EDUCATION AND RESEARCH CENTER, TAMAKA, KOLAR, KARNATAKA

COPY RIGHT

DECLARATION BY THE CANDIDATE

I hereby declare that the Sri Devaraj Urs Academy of Higher Education and Research, Kolar, Karnataka shall have the rights to preserve, use and disseminate this dissertation/thesis in print or electronic format for academic/ research purpose.

Date :

Place : Kolar ***Dr. MUKTAMANI GURUMAYUM***

ACKNOWLEDGEMENT

I THANK THE LORD ALMIGHTY FOR SHOWERING HIS BLESSINGS ON ME.

Gratitude cannot be expressed through words, yet I may be permitted to record here the invaluable guidance, help, co-operation and encouragement I received from distinguished luminaries referred to in this dissertation.

My deep felt gratitude to ***My dear Parents (G. Robindro Sharma & M. Geeta Devi)*** *and my brother for their constant support and encouragement without whom I would not be the person I am today.*

First, I record my deep sense of gratitude to ***Dr. Shivakumar V,*** **MD, DNB** *Professor, Department of Dermatology, Venereology& Leprosy, Sri Devaraj Urs Medical College, Kolar, who guided me at every step in the preparation of the dissertation.*

I sincerely thank ***Dr. Rajendra Okade****, Professor and Head, Department of Dematology, Venereology & Leprosy, Sri Devaraj Urs Medical College, Kolar, who encouraged, inspired and enlightened me at every step in the preparation of this dissertation.*

I would also like to thank my ***Husband, Dr. Jayadeva Ph*** *for tolerating my tantrums and being my pillar of support in all possible ways.*

I extend my sincere thanks to ***Staff Dr. Rajshekar T.S, (Professor), Dr. Rajesh (Asst prof) & Dr. Ragvendra (Associate prof)*** *& also my postgraduate colleagues of the Department of Dermatology, Venereology & Leprosy, Sri Devaraj Urs Medical College, Kolar, for all their help and co-operation in collection of data for the study.*

I also thank the management of R.L. Jalappa Hospital and Research Center for permitting me to carry out this study and allowing me to utilize the facilities at this hospital in preparing my dissertation.

I will be failing in my duty if I do not thank all my patients who have been kind enough to participate in the study.

Dr. MUKTAMANI GURUMAYUM

ABSTRACT

BACKGROUND

Non - Venereal genital dermatoses is always confused with venereal dermatoses because of its similar presentation and it causes a diagnostic delimma to the treating physician as well as considerable concern to the patients. Non- venereal dermatoses need not be restricted to the genitalia alone, it can affect other mucous membreane and skin. So, a proper knowledge of various dermatoses and its varied presentation with proper knowledge of the anatomical structure is required for its correct diagnosis.

OBJECTIVES

- To assess the Frequency of female genital dermatoses.
- To analyse the various non venereal dermatoses occurring in female genitalia.

METHOD

It was a descriptive study which included a series of 150 patients presenting to the Dermatology department over a period of 15 months from DEC 2011 to March 2013. Some venereal conditions which were transmitted through non-venereal route were also included. Cases having any venereal diseases were excluded from the study.

A written consent was taken. Thorough history like chief complaints, duration of the disease, vaginal discharge, sexual functions, urinary symptoms, any treatment, drug history (OCP or HRT) was taken.

RESULTS

The frequency of non - venereal dermatoses among female patients attending OPD is very common. The age ranged from 3months to 65 years with majority of age group between 21-40 years (61%) which is reproductive age group. The non – venereal genital lesions were grouped into 4 groups according to the involvement of site with labia majora 96 (64%), most common dermatoses being folliculitis 25 (16%), oro-genital12 (8%) and skin involment 43 (28%). Oro-genital involvement predominantly included vitiligo in 5 cases followed by candidiasis in 2 cases , SJS in 2 cases and PV in 2 cases and lichen planus in 1cases. Among skin disorders with the oro-genital involvement i.e.11(7%), 5(3%) cases of vititligo, 2 cases of SJS and 2 cases of PV and 1 cases of LP . A total of 26 non – venereal genital dermatoses were encountered with folliculitis 25(16%) being the most common dermatoses followed closely by LSC 22(14%) and vitiligo 21(14%). A total of 43 cases (28%) with systemic involvement was recorded with most common association being DM-2, 13 (8%) followed by HTN 9 (6%) and thyroid 7(4%). Among 150 patients, 115 patients were in postpubertal, 17 patients were in postmenopausal and 7 patients in prepubertal age group.

CONCLUSION

Localized genital involvement were found to be quite significant among non-venereal dermatoses. Three disorders which were very common were folliculitis, vitiligo and Lichen simplex chronicus. The study was quite useful in clinical diagnosis of non-venereal dermatoses and differentiating them from venereal dermatoses.

Keywords: NON VENEREAL, GENITALIA, VENEREAL

TABLE OF CONTENTS

Sl No	Particulars	Page No
1	INTRODUCTION	01
2	OBJECTIVES	02
3	REVIEW OF LITERATURE	05
4	MATERIALS AND METHODS	37
5	RESULTS	40
6	DISCUSSION	56
7	SUMMARY	63
8	CONCLUSION	65
9	BIBLIOGRAPHY	66
10	ANNEXURE	76

LIST OF FIGURES

SL. NO.	FIGURES	PAGE NO.
1.	Normal anatomy of female external genitalia	04
2.	Common dermatoses distribution	41
3.	Age wise distribution	42
4.	Distribution with associated systemic diseases	43

INTRODUCTION

Vulvar disease is an orphan disease. Diseases of vulva are not a priority in any of the women's health initiatives. Many care givers looking after women's genital disease are busy passing through the vulva and seldom stop to look, even if they see changes, these may go unrecognized. Women themselves have little to genital education and many were brought up with prevailing cultural taboos about female genitalia and are members of " down there generation" where almost no words are spoken to refer to female genitalis, internal or external.[1] Because of these factors women suffer with undiagnosed symptoms.

Non-venereal dermatoses tend to be confused with venereal dermatoses, which may be responsible for considerable concern to the patients as well diagnostic dilemma to the treating physicians.[2] The study was to find the pattern of non-venereal dermatoses presenting with genital lesions and to correlate with various clinical parameters.

Contrary to popular belief, all lesions on the genitalia are not manifestation of sexually transmitted diseases. These non-venereal disorders are of considerable concern to the patients causing mental stress and guilt feeling in patients who are convinced that they have developed STDs.[3]Non-venereal dermatoses are often diagnostic dilemma to the treating physicians, who have to effectively manage the condition and also allay the associated anxiety. Determining any causal or aggravating factor can save the patient from the agony of persistant discomfort and restricted social life thereby considerably improving the Dermatology-specific quality of life.[4]

AIMS AND OBJECTIVES

- To assess the Frequency of female genital dermatoses.

- To analyze the various non-venereal dermatoses occurring in female genitalia.

ANATOMY OF FEMALE EXTERNAL GENITALIA

The first pearl for managing vulvar disease is recognizing normal vulvar anatomy. The vulva is defined as the structures between the thighs bounded laterally by the genitocrural fold, anteriorly by the mons pubis and posteriorly by the posterior comissure. The main anatomic structures include the mons pubis, labia majora, labia minora, clitoris,vestibule, urethral meatus and the hymen with its surrounding vestibular gland including Bartholin's gland. The innermost aspect of the vulva is the vestibule. It encompasses the opening of the urinary tract with urethral meatus, and the opening to the vagina with its hymental ring. The vestibule extends posteriorly from the clitoral frenula to the posterior commissure and laterally to Hart'sline, where the non keratinized transitional epithelium at the base of medial aspects of labia minora. This nonkeratinized squamous epithelium of the vestibule contrasts with the keratinized surface of the labia majora and of the skin elsewhere. It lacks a protective keratinized surface, resulting in diminished barrier function, explaining why this tissue is easily irritated and infected under certain circumstances.

The normal appearance of the vulva varies considerably depending on age and ethnic background. Hormone factors modify the size and shape of the labia, hymental ring, the degree of pigmentation, and the hair growth. At birth the hymen, vestibule and the clitoris are plump from maternal hormones. In infancy the labia minora are very small and the mons and labia majora are hairless with an intact hymen. These change significantly at puberty and again after menopause.

A good general vulvar diagram, is important for not only the care giver but also the patient. When examining vulvar patients it is always important to do an educational

vulvar examination so that not only is the patient examined well but is also taught to examine herself, empowering her to look at herself in this area, so often neglected , and participate more fully in her own care.

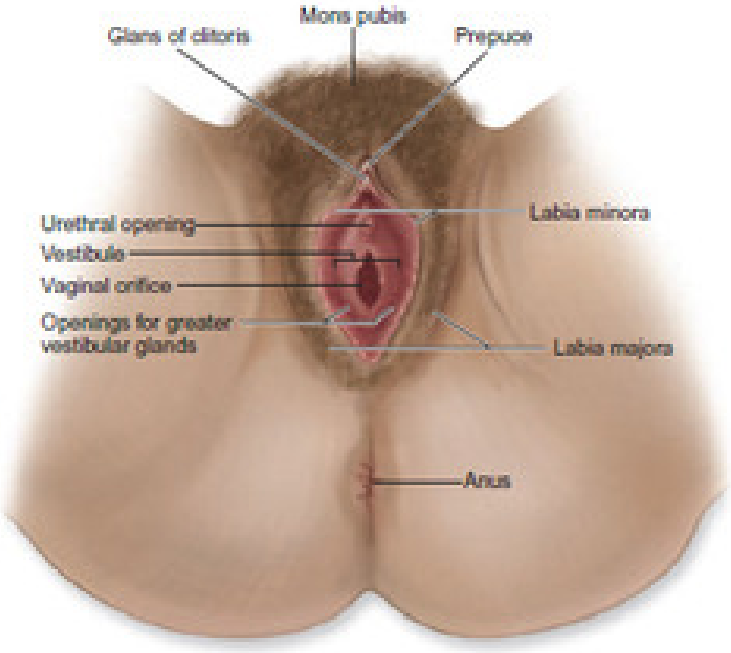

Fig 1 : Anatomy of female external genitalia

REVIEW OF LITERATURE

Disorders of vulval epithelium have proved confusing to the many varied specialists who have been involved in their diagnosis and treatment. The difficulty has arisen because the majority of problems are dermatological and the specialists - gynaecologists, urologists, paediatricians and genitourinary physicians - have had little or no training in dermatology.[5,6] Over the years, classification of vulval disorders have been devised to help, but unfortunately these have resulted in further confusion.

Urogenital complaints are among the most important problems encountered by dermatologist. Vulvar dermatoses which trouble the clinicians the most are benign inflammatory disorders which represent a wide spectrum of diseases and can be classified according to the INTERNATIONAL SOCIETY FOR THE STUDY OF VULVOVAGINAL DISEASE (ISSVD) clinical classification 2011 as follows :[7, 8]

1) **SKIN-COLOURED LESIONS**

   a) **Skin coloured papules and nodules**

      Eg- Vulvar Intraepithelial neoplasia, skin tag, Nevus, Mucinous cysts of vestibule, Epidermal cyst, Bartholin gland cyst, Syringoma.

   b) **Skin coloured plaques**

      Eg- Lichen simplex chronicus.

2) **RED-LESIONS: PATCHES AND PLAQUES**

   a) **Eczematous & lichenified disease.**

      Eg- Allergic contact dermatitis, Irritant contact dermatitis.

   b) **Red patches and plaques.**

      Eg- Candidiasis, Psoriasis, Lichen Planus, Bacterial infection,Infestations

c) **Bullous and Erosive Diseases**

Eg- Lichen planus, Toxic epidermal necrolysis, Pemphigus vulgaris, Fixed drug eruption.

3) **RED LESION: PAPULES AND NODULES.**

Eg- Folliculitis, Angiokeratoderma, Hidradenitis suppurativa, Hailey-Hailey disease.

4) **WHITE LESIONS**

Eg- Fordycespots, Milium, Vitiligo, Lichen Sclerosus, Post-inflammatory hyperpigmentation **.**

5) **DARK COLOURED (BROWN, BLUE, GRAY OR BLACK LESION)**

Eg- Melanocytic nevus, Vulvar melanosis, Acanthosis nigricans ,Seborrheic Keratosis, Benign tumors.

6) **BLISTERS**

Eg- Lymphangioma circumscriptum, Immune blisteringdisorders, Drug eruption.

7) **EROSIONS AND ULCERS**

Eg- Excoriations due to systemic disease, Trauma, ErosiveLichenplanus, Fissuring arising on abnormal tissue (candidiasis, LSC, Crohns disease), Erosion due to neoplasia, Behchets disease.

8) **EDEMA (Difffuse Genital Swelling)**

Eg- IdiopathicLymphatic abnormality, Post-radiation lymphatic obstruction, Post – infectious edema,Venous obstruction, Cellulitis.

IRRITANT CONTACT DERMATITIS

Contact dermatitis is an inflammation of the skin because of an external agent acting as an irritant or allergen. An irritant is any substance that causes inflammation, erythema and induration upon exposure to the dermis, whereas an allergen is any substance that stimulates a type IVdelayed hypersenstitivity reaction in sensitized individuals.[9] The incidence of vulvar contact dermatitis in the general population is unknown; however, the reported incidence in a vulvar clinic in the United Kingdom was 20–30%, and in an Australian vulvar clinic, the incidence was 15%.[10] It is generally accepted, however, among specialists in vulvar disease that as women increasingly apply products to the vulva, the incidence of contact dermatitis is increasing. Common products containing chemicals that may cause contact dermatitis include soaps, menstrual pads, pantyliners, toilet paper, diapers, fabric detergents, fabric softeners, feminine sprays, cosmetics, spermicides, pessaries, and condoms.[11] Additionally, medications that frequently cause contact dermatitis include benzocaine, hormonal creams corticosteroids topical antifungals and antibiotics. Women with contact dermatitis present with burning, itching, dyspareunia, and fissuring around the introitus . Physical examination findings may range from mild erythema to weeping lesions. Histologically, findings are nonspecific. One may see spongiosis, acanthosis, parakeratosis and a dermal inflammatory infiltrate. The lax tissues of the vulva predispose to marked dermal edema. Continued exposure to the irritant and chronic rubbing or scratching may even lead to dermatitis.[11]

ALLERGIC CONTACT DERMATITIS

In spite of frequent use of topical agents in the vulval area, allergic contact dermatitis is extremely rare in clinical practice. An explanation to this occurance may be that patients had perianal skin involvement as well as vulvar involvement, and allergic contact dermatitis to topical medications is more frequently encountered in perianal skin.[12] One study has shown a higher incidence of positive patch tests in patients with anogenital dermatoses if both genital and perianal areas involved compared to dermatoses affecting the genitals alone. ACD should be ruled out by patch testing in any recalcitrant, chronic or recurrent vulvar dermatosis. Testing to a standard patch series and a medicament, cosmetic and preservative series plus use testing of all topical medicaments applied by the patient is recommended. The therapy consists of avoidance of the chemical in future and local skin care, which requires knowing all products that may contain the allergen, in addition to basic topical corticosteroid ointment use and night time sedation.[13]

SEBORRHEIC DERMATITIS

Genital involvement is frequently common with this dermatoses. The groin and labia majora are the common site of involment.[14]A good history and other typical area of involvement will help in the diagnosis of the condition. Diagnosis is mainly on clinical ground, including response to the therapy, and it is not necessary to perform a biopsy. No treatment may be required other than reassurance that it is not sexually transmitted or related to poor hygiene.[15]However treatment that diminishes the malassezia load and reduces irritation and eczematization can be successfully and safely used long term.

PSORIASIS

The pattern of psoriasis affecting the anogenital skin is most frequently flexural. Psoriatic lesion on the genital skin often present as well- demarcated, brightly erythematous, thin plaques and usually lack the typical scaling that is apparent on other part of the body due to maceration .[16]The areas involved include the genitocrural folds, mons pubis and outer aspects of labia majora, the perianal skin and the natal cleft.[17] Rarely there may be some scarring associated with vulval psoriasis, with loss of labia minora and fusion of clitoral hood. Due to Kobners phenomenon, genital psoriasis may be worsened by irritation from urine and faeces, tight –fitting clothes and sexual intercourse.

Case report of Pustular psoriasis having genitals involvement in male patients is reported but case report of female genital involvement is not there till date.[18]
The diagnosis is usually made on the basis of its clinical appearance and involvement of the other area of the body or with symptoms associated like dystrophy of nails or joints involvement. In one study it was found that genital involvement with psoriasis occur in about (29-40)% patients with psoriasis.[19,20] Psoriasis affecting genital skin may be associated with considerable morbidity, discomfort and embarrassment and may considerable impact quality of life and psychosexual wellbeing.

LICHEN PLANUS

Lichen planus (LP) can affect the vulva in isolation or at the same time as generalized eruption, when approx 20% of patients will have genital lesions. The vulval lesions are similar to those seen on the other sites and may be seen as violaceous and erythematous papules, white or annular plaque, and erosion with or

without a lacy white border.[21]These lesions may all ulcerate, Wickham's striae occur infrequently. If the vulva is affected in isolation, the disease is more often erosive, with most of the lesion around labia majora, clitoris and clitoral hood. Confluent white and red patches will also be seen in this variant. A careful examination of oral mucosa is helpful,as LP may be found on the tongue, palate, gingival and lateral buccal mucosa.[22]

a) Pigmented flexural LP- This variant of LP can affect the vulval area , particularly mons pubis, inguinal and genitocrural folds. The characteristic and striking findings is brown pigmented patches, some so badly pigmented that it resemble melanocytic nevi.[23]

b) Vulvo - vaginal gingival lichen planus (VVG-LP) or (Desquamative vaginitis)- This distinct erosive form of LP is clinically very similar to mucous membrane pemphigoid. VVG-LP principally affects the inner aspect of the labia minora, vestibule and vagina. The condition is chronic and painful, and there is increase in vaginal discharge, dysuria, dyspareunia and post-coital bleeding. Clinically, the epithelia are eroded and often there is distinctive white lacy border. There might be marked loss of architecture. The vaginal lesion are velvety red erosions or bright red glazed erythema, whichis friable and bleeds when touch. Vaginal synechiae and adhesions develop, leding in some cases to vaginal stenosis.[24] The cervix may also be involved. Oral LP lesion can occur at any site but, the characteristic finding is intense erythema of the gingivae, which may be asymptomatic.[24]The manifestations of this syndrome do not necessarly occur all synchronously.

CHRONIC VULVAL PURPURA

It is not uncommon to find patients with purpuric patches, often at the vestibule, in which the hemosiderin and plasma cells are found without any specific epidermal changes and the term chronic vulval purpura may be a more accurate description.

LICHEN SCLEROSES [25, 26]

Lichen sclerosus was first described as a variant of LP with a tendency to affect the genital areas. The etiology is still unknown but there is mounting evidence that LS is genetically determined autoimmune disorder. A positive family history is recognized and the disorder has been described in twins, both identical and non - identical. An association with LS and other autoimmune disease in female has been noted. LS can affect female of any age but majority of the patients are prepubertal and menopausal. The presenting symptoms is usually itching which is often severe and distressing.[27] The classical lesion seen on extragenital are ivory white papules and plaques with follicular drilling. Anogenital lesions tends to be characterized by flatter lesions of atrophic white epithelium, which may become confluent, extending around the vulval and perianal region in figure of eight configuration.[28]There may also be edema ,purpura, erosion and bullae. The site most commonly affected are genitocrural folds, the inner aspect of the labia majora, labia minora, clitoris and clitoral hood. Vestibular involvement is rare and vaginal lesions do not occur, as LS seem to spare non-stratified squamous epithelium. Perianal lesions occur in approximately 30% of female patients, in contrast to males who do not develop perianal lesion. Extragenital lesions occur in 10% of women with vulvar disease. Lesions of LS in oral cavity are extremely rare and occur on a site in the mouth that has cornified stratified squamous

epithelium, the tongue.[29]It is not uncommon for patients with vulval LS to have coexistent oral LP.[30]LS is a scarring dermatosis and the changes that can occur on vulva include loss of labia minora, and sealing over the clitoral hood, burying the clitoris. Introital narrowing resulting from anterior and posterior labial fusion sometimes resulting in tiny opening in the vestibule. LS has been reported in association with squamous cell carcinoma, verrucous carcinoma and melanoma.[31]

ULCERATIVE AND BULLOUS DISORDER

Any of the blistering skin disorder can occur on vulva and vagina, either as a part of the generalized disease or in isolation. Diagnosis can be more difficult in latter case.There are many causes of vulval ulceration and some features are important in narrowing the differential diagnosis. It is helpful to divide them into acute and chronic.

ACUTE GENITAL ULCERATION:

a) Benign Apthae – Many eponymus names have been assigned to acute vulval ulcers and several of these disorders are probably examples of benign apthae. Reiters syndrome may be associated with an ulcerative vulvitis. Benign apthae of vulva may not be associated with oral lesion. The lesions are usually multiple, small and solitary and few are larger refer to as gaint apthae. Sometimes there are premenstrual exacerbation once the menarche is reached. The etiology remains unknown but herpetic lesions should always be ruled out.

b) Erythema multiforme – The pattern of recurrent acral erythema multiforme is rarely associated with genital lesions, whereas oral lesions are nearly always present. The vulva - vagina are more frequently affected in Steven - Johnsons

Syndrome, often with erosions. Vaginal stenosis and adenosis may be post-inflammatory complications.

c) Bullous fixed drug eruption – These are less common on vulva than on penis, where the commonly implicated medications include paracetamol, fluconazone and tetracycline. It is now rare to see cases involving phenopthalein, sulfonamides and barbiturates.

d) Toxic epidermal necrolysis -Vulvovaginal sequelae of toxic epidermal necrolysis studied by Meneux et al found that during the acute period, genital lesions were present in 28 of 40 patients studied (70%). In 24/28 patients (89%) the lesion were vulvar only and in 3/28 (11%) they were vulvovaginal. In one case vaginal involvement was not proven because the patient was a virgin.[32]

CHRONIC GENITAL ULCERATION:

Any chronic fixed ulcer on genital mucosa must be considered malignant until proved otherwise. The differential diagnosis of chronic ulceration includes diseases listed below

a) Genetic - Epidermolysis bullosa, Hailey-Hailey disease and Dariers disease may all be responsible for chronic ulceration. Exacerbation may follow friction, infections, irritants and herpes simplex infections.

b) External trauma - Nymphohymenal tears, dermatitis artefacta and radiation damage.

c) Malignancy -The two most common carcinoma of vulva is squamous cell carcinoma and basal cell carcinoma. Melanoma may also be present as pigmented ulcerated lesions. Langerhans cell histiocytosis may present with vulval and vaginal ulceration

d) Infections - Chronic infective ulcers occur in tuberculoses, actinomycosis and other deep fungal infection.

e) Inflammatory- Lichen sclerosus, Lichen planus, Lupus erythematosus can all cause chronic ulceration. Pyoderma gangrenosum may be mistaken for malignancy on the vulva. Hidradenitis suppurativa and Crohn's disease can sometimes be difficult to distingunish, particularly if they occur together. Several of the autoimmune bullous disease affect the vulva.

f) Behcets disease - Is Multisystem inflammatory disorder characterized by recurrent oral ulcers, genital ulcers and ocular inflammation, and which frequently involves the joints, skin, central nervous system (CNS) and gastrointestinal tract. Classified as a systemic vasculitis, it can involve both the arteries and veins of almost any organ. Lesions are seen to be in remission during pregnancy and seen as transient neonatal Behcets in newborn suggesting placental transfer of maternal antibodies.[33, 34.]

PLASMA CELL VULVITIS (ZOON'S VULVITIS)

In 1957, Garnier described a rare benign chronic inflammatory condition characterized by erythematous plaques found in postmenopausal women.[35]The histologic findings parallel those described by Zoon in the foreskin in 1952.[36] In view of the involvement of multiple mucosal and cutaneous surfaces sharing the same histologic features, the name of plasma cell orificial mucositis and idiopathic lympho plsmacellular mucositis - dermatitis have been proposed. Cliniclly it present as one or multiple shiny, glazed deeply erythematous patches and plaques with a orange hue and multiple purpuric "cayenne pepper spots". The lesions are sharply demarcated and bilateral. The most frequent area affected are inner face of labia majora,

periurethral mucosa , clitoris, fourchette. The patients frequently complains of pruritus, burning pain and dyspareunia.[37]

PEMPHIGUS VULGARIS

Pemphigus Vulgaris is another immunobullous disease that preferentially affects mucous membranes. Pemphigus vulgaris generally occurs in younger individuals in the fourth to fifth decade. Blisters of dry, keratinized skin occur in most patients, although mucosal disease often precedes widespread disease.[38] Oral lesions often occur first, and patients may need to be specifically questioned about vulvovaginal symptoms. Although classically considered a nonscarring condition on most epithelial surfaces, pemphigus produces vulvar and vaginal scarring, again indistinguishable from that of cicatricial pemphigoid and lichen planus.[39]However Pemphigus Vulgaris also is characterized ultimately by blisters of keratinized skin. These are superficial, and therefore the blisters and flaccid erosions develop quickly.

The diagnosis is usually easily confirmed through routine biopsy from the edge of an erosion or blister, with direct immunofluorescent biopsy from adjacent normal epithelium.

BULLOUS AND CICATRICAL PEMPHIGOID

They are subepidermal autoimmune bullous disorders. Both are caused by autoantibodies against components of hemidesmosome and type VII collagen, resulting in damage of the basement membrane and subsequent loss of adhesion between the dermis and epidermis.[40] The lesions of bullous pemphigoid present initially as tense blisters on erythematous base on dry skin and without Nikolsky sign. Trunk, groin and flexural areas are commonly affected.[41,42]

PEMPHIGOID GESTATIONIS

Herpes gestationisis a vesiculobullous disease seen in pregnancy and with a strong association with HLA-DR3 and HLA-DR 4. The autoantibodies bind to 180-KDa hemidesmosome antigen (BPAg2).[43]

The presentation usually in the second trimester, includes severe pruritus and macular erythematous rash that leads to blistering and superficial ulcerations. The keratinized surfaces of vulva and pubic area may be involved in addition to trunk and upper thigh. Spontaneous resolution follows soon after delivery, although it may occur during late third trimester.

HAILEY-HAILEY DISEASE

It is an autosomal dominant acantholytic genodermatosis whose pathogenesis is thought to involve mutations in calcium pump ATP2C1.[44]Intracellular junctions are thought to be weakened by dysregulation of calcium metabolism. Onset of disease occurs during adolescence and the disease has predilection for flexural or intertriginous areas. Isolated vulvar involvement has been reported.[45,46] The lesions start as tiny pruritic, linear erosion in background of white maceration that spread centrifugally to surrounding skin with associated crust and foul odor.

DARIER'S DISEASE

It is an uncommon genodermatosis whose pathogenesis is thought to be result of mutation of gene on chromosome 12q encoding a calcium pump protein, ATP2A2.[47] Although it can be autosomal dominant, only half of the cases in a large series have a positive family history.[48] The patient often presents at puberty, but can also present later in life, with numerous hyperkeratotic papules usually distributed

over the trunk. The disease has seborrheic distribution and frequently involves the vulva. [49]Localized vulvar presentation can be seen. Nails tend to be thin, brittle and dystrophic. Superinfection with bacteria, virus or fungus is common.

BACTERIAL INFECTIONS : STAPHYLOCOCCI AND STREPTOCOCCI

Staphylococcus aureus is the causative agent in the infective folliculitis, boils and abscess of vulva.[50]It is often associated with underlying problems like diabetes milletus and immunosupression. Pseudofolliculitis is a sterile folliculitis that may follow shaving or waxing and is caused by newly regrowing hairs inducing an inflammatory reaction. It is a foreign body reaction ranging from mild inflammation to formation of abscess and sinuses. Beta hemolytic Lancefield group A bacteria may be the cause of vulval cellulitis. The erythema and edema may be intense and vesicle and bullae may develop.They are usually as sociated with systemic sign.The infection arises in the site where there is a wound and follows vulvectomy and lymphadenectomy. Streptococal dermatitis usually affects the anogenital area of children.

Gram negative bacteria - Pseudomonas aeruginosa is common in patients with bladder problems but it is not a cause of vulvovaginitis. There has been a report of blue staining of napkin with this infection.[51] Despite its name ,Trichomycosis is caused by species of cornybacteria, which leads to black, yellow or red nodules on the shaft of pubic and axillary hair.

Mycobacterial infections – Vulval tuberculosis is caused by mycobacterium tuberculosis. It may occur by means of hematogenous spread from foci outside the

genital tract, by distal spread from upper genital tract, or as primary exogenous infection contracted from sputum or sexual intercourse. The female genital tract may be involved in the infection by Mycobacterium Leprae but vulval lesions are rare.[52] Pubic hair may be lost.

Higher bacterial infection - Higher bacteria is the name assigned to those bacteria ,like filamentous fungi capable of forming true branches. They include the genera streptomyces, actinomyces and nocardia.[52]

ACTINOMYCOSIS - The gram positive acid fast organisms responsible for causing Actinomycosis are predominantly Actinomyces Israeli and Actinomyces gerenseriae. Genital infection usually arise from bowel disease.

MYCOPLASMAS - There are rare reports of M. Hominis bring isolated from cases of Bartholin abscess. Abscesses of Bartholins gland may be caused by pyococcal organisms, gonococcus and Chlamydia trichomatis. The abscess result from distal blockade of the duct. The patient presents with fever, malaise and tender swelling arising posterior to the labia minora.[53] Episodes of bartholinitis may be mild and recurrent until fibrosis supervines.

FUNGAL INFECTIONS

Candidial vulvovaginitis - Candida and torulopsis are both yeast that can infect the vulva and vagina.Torulopsis account for few infection, whereas candida albicans is the most frequently isolated. Infection in women is usually a vulvovaginitis.[54] Changes in the host factors are probably responsible for transition to pathogenicity

and are generally not associated with sexual contact. Pregnancy, diabetes, immunosupression, high dose oral oestrogen oral contraceptive pills may all be predisposing factors.[55]The primary infection arises in vagina causing a heavy, curdy white discharge which then leads to a secondary vulvitis with well demarcated sheets of erythema on the outer aspect of vulva,sometimes extending into the genitocrural folds and perianally. There may be scaly or vesicopustular edges. Beyond this edge lie grouped or isolated superficial small pustules , which ruptures rapidly leaving a slightly scaly periphery.[56] In all cases of candidial vulvovaginitis, but particularly in middle aged patients, late onset diabetes should be considered and appropriate tests carried out.

Dermatophyte fungi - Dermatophyte infection of the vulval skin are uncommon in cooler climates. The sites affected are mainly inguinal folds and perianal areas. The causative organisms are Trichophyton rubrum and epidermophyton floccosum.[57]The vulval epithelium in the adults seems to be relatively immune to dermatophyte infections. The lesions are erythematous and scaly, with a spreading circinate edge.

Miscellaneous fungal infection- Pityriasis versicolor classically occurs on the trunk, but in severe widespread infection there may be vulval involment. The black and white form of piedra (trichosporosis) are caused by Piedra hortai and Trichosporun beigelli respectively, the latter acting synergistically with cornebacterium. The hair bearing part of the vulva can be affected with black and white nodules along the hair shaft.[58]Subcutaneous infection occur in children and young adults. Cryptococus neoformans can induce painless ulceration in vulva in immunosuppressed patients.

INFECTION WITH PROTOZOA

Infection with Trichomoniasis vaginalis causes frothy, malodorous , grayish green ,watery discharge and bright red vaginal mucosae studded with petechiae. The vaginal discharge may cause secondary vulvitis, with erythema and swelling of the vestibule and labia minora. Colonization of urethra and paraurethral glands often occurs. The diagnosis is made by microscopic examination of wet mount and culture. The flaggelate portozoal Leishmania tropica causes cutaneous, mucocutaneous and viseral form of leishmaniasis. The vulva is mainly affected by cutaneous form,which is endemic in area of India & eastern Mediterranean.[59]The lesions are nodular and ulcerative. Vulval schistosomiasis is usually caused by Schistosoma hematobium. The lesions are chronic, scarring and granulomatous and may ulcerate and calcify.

VIRUSES

Three groups of viruses are important causes of infection in the genital area : poxvirus, papillomaviruses and herpesviruses.[60]Other viruses seldom give rise to distinctive clinical pictures, although vulval lesion can be a part of generalized viral infection. The most common poxvirus is **Molluscum Contagiosum** virus, two types of which has been identified. There is no relationship between viral type and anatomical distribution of lesions. Vulval lesion are common in children and acquired innocently, but they are more likely to be acquired sexually in adults. Lesions are mostly found on mons pubis, labia majora and if inflamed mimics folliculitis. The clinical diagnosis becomes straight forward when the lesions are pearly white with umbilicated centre, but solitary large lesions can cause diagnostic problems.

HERPES SIMPLEX VIRUS

Herpes Simplex Virus belong to the ubiquitous Herpesviridae family of virus, which comprises herpes simplex virus-1(HSV-1), herpes simplex virus-2 (HSV-2), varicella Zoster virus, cytomegalovirus, Epstein-Barr virus.[61,62] HSV- associated diseases are among the most wide-spread infections, affecting nearly 60% to 95% of human adult.[63]They are incurable and persist during lifetime of the host, often in latent form. Clinical presentation of HSV infection range from asymptomatic infection to mucocutaneous conditions such as orolabial, ocular and genital herpes. HSV induced disease, in particular, HSV2 infection is the most common cause of genital ulceration.[64]Frequent outbreaks are associated with inconvenience, cosmetic concern and psychological distress. Such infection may lead to significant mortality and morbidity.

HUMAN PAPILLOMA VIRUS

Genital human papillomavirus (HPV) infection is a common and usually transient dermatologic infection which has recently garnered media attention due to developments in vaccine prevention as well as changes in cancer-screening recommendations. WHO estimates that 630 million people are infected with genital HPV resulting in a worldwide prevalence of9-13%.[65] HPV is transmitted via genital contact and is the most common STI. However, HPV can be transmitted among technical virgins via non-penetrative sexual skin-to-skin contact.[66] Life time risk of acquiring HPV is at least 50%.[67] The prevalence of HPV increases with age from 14-24 years of age and then declines.[68] HPV infection is associated with being sexually active, having a higher number of sexual partners in the past year, being unmarried, being of lower socioeconomic level and having a lower educational level.

INFESTATION

A) **Phthirus Pubis/ Crab lice –** Ectoparasitic infestation in genital area causing itching, irritation, erythema and inflammation. Non-sexual contact like sharing of personal article with an infected person. It can affect other sites like armpits, thigh, eyelashes, eyebrows, beard and scalp. Full STI screening is recommended for men and women when they are assessed for pubic lice. Evidence of nits or adult lice in the pubic hair confirm the diagnosis. If excessive presence of lice seen in most of the hair bearing areas immunosuppresion or malnutrition should be suspected.[69] Other than the pharmacologic intervention , non-pharmacological treatment like changing of bedsheets, washing of clothes and disinfecting the room is very essential.

B) **Scabies** - It has been found to occur in both sex group and all ages. Lesions of scabies are usually in bilateral finger web spaces, sides of the finger, wrist joint, anterior axillary fold, genitalia, buttocks and areola of females. Papular lesions are most common type followed by eczematous lesions. Genital involment are most commonly found in children and is the diagnostic clue in case of doubt.[70]The cutaneous manifestation of scabies are due to burrowing of the female mite in the stratum corneum followed by humoral and delayed type hypersensitivity reaction.[71] The source of infection in scabies can be infected family member, sexual partner or friend and spread is commonly by direct contact, fomites and sexual contacts.

C) **Maggots infestation** - Myiasis is a parasitic infestation caused by the larvae of several species. The infestations reduce host physiological functions; destroy host tissues and causes significant economical losses . The location of this infestation at genital region is, however, an extremely rare occurrence.

There are two forms of myiasis: Obligate, in which the maggots feed themselves on living tissues, and Facultative type, where the maggots opportunistically take advantage of wounds or degenerative necrotic conditions to incubate their larvae.[72] The lack of personal hygiene is the contributing factor for the cause of myiasis, more so with the genital myiasis. Female flies possibly are attracted by the fetid odor, and lay eggs in existing lesions. Thereafter, the larvae invade the tissue and feed themselves on living tissues. The distribution of myiasis is worldwide with more cases being reported from tropical, subtropical and warm temperate areas. This condition is mostly unfamiliar in USA and European countries.[73] However, the rapidity of international air travel permits this exotic tropical infestation to present in any region

CROHN'S DISEASE

Anogenital lesions occur in approximately 30% of patients with intestinal Crohns disease, either as a direct extension of active intestinal disease or as metastatic disease.[74]Vulval disease may present many years before intestinal involvement, and in some cases there is vulval edema only, with no evidence of granulomatous inflammation. The more usual presentation is ulceration, abscess, fistula and sinus formation with granulomatous histology. There may be deep linear fissuring along the skin creases.

MALAKOPLAKIA OF VULVA[75]

Malakoplakia (soft plaque) is a granulomatous response to infection. It is not specificly caused by one organism but many organism causing it are Escherichia coli,

pseudomonas and staphylococcus aureus. It usually affects the urinary or genitourinary tract but cutaneous lesions may occur on vagina, vulva and perineum. Involvement of Bartholins gland has been described. The lesion include persistant plaque, ulcers, nodules and sinuses. There is often underlying immunosupression, the etiology of which may include malignanacy, dermatomyositis, lupus erythematosus, rheumatoid arthritis and organ transplantation.

BENIGN TUMORS

Most of the tumors that arises in genital skin are similar to those that occur on the skin elsewhere. Fibromas arise from deeper connective tissue structures, particularly those surrounding the introitus and the perineum. They usually occur on the labia majora , are often pedunculated or pendulous ,and can attain a very large size. Fibroepithelomatous polyps (skin tags) are usually solitaryand appear as soft wrinkled polypoidal nodules.[76] Lipomas develop from the fatty tissue of labia majora.Two types of lymphangiomas may occur on the vulva : lymphangioma circumscriptum, which are localized thin walled vesicles and cavernous lymphangiomas which arise in childhood and present as soft compressible mass, which although located in labia minora, can involve the whole of vulva.[77]

Melanocytic naevi include junctional naevi, compound naevi and intradermal naevi, which usually share the same clinical and histological features as naevi at the other site of body, with the exception that premenopausal women vulval naevi may have atypical histopathological features. Epidermal cyst of vulva may develop from the epithelial implants following surgical trauma, from epidermal inclusions occurring at fusion sites occurring during embryogenesis or from obstructed sebaceous gland ducts that have undergone squamous metaplasia.[78]They may be single or multiple and

occur most commonly in labia majora. Steatocystoma may present as solitary cyst in the vulval region. Calcified nodules have been recorded.

SEBORRHEIC KERATOSES

Seborrheic Keratoses are common benign tumors of epidermal cells that are most prevalent in older adults and found on all keratinized skin surfaces.[79,80] They are the proliferation of keratinocytes of unknown origin occurring in above 40 years with familial predilection for large numbers. These lesions often mimic nevi, pigmented condylomata, vulvar intraepithelial neoplasia, squamous cell carcinoma & melanoma. In case of doubt the diagnosis can be done with dermoscopy and biopsy.[81]Typical but symptomatic lesions can be removed by liquid nitrogen cryotherapy, curettage or shave biopsy.

SYRINGOMAS

These are considered to be adenomas of the intraepidermal eccrine sweat ducts. They do not require treatment as they are asymptomatic but sometimes may be pruritic. Vulval syringomas are usually bilateral, symmetrical and multiple, although a solitary lesion may also be seen.[82]

PAPILLARY HIDRADENOMA

This sweat gland adenoma with apocrine differentiation occurs almost exclusively in the anogenital region of middle age white women. It has been associated with anogenital gland. It is a firm asymptomatic papule or nodule, which can occasionally be painful and occurs most commonly on labia majora, interlabial sulcus and lateral surface of labia minora or perineal region.[83]Although they occur

singly, there are multiple lesions. Curiously, when multiple, all the lesions tend to develop over one side of vulva. In most patients the covering epidermis remains intact, but in proportion the elevated epithelium may become ulcerated. Malignant changes within the papillary hidradenoma can occur producing apocrine carcinoma and adenosquamous carcimoma.[84]

FOX-FORDYCE DISEASE

In this condition the apocrine duct become blocked, with retention of sweat. Itchy skin coloured papules appeared on the mons pubis, labia majora, axilla and breast. They develop around the time of puberty and there are menstrual exacerbation. There is some improvement in pregnancy and after menopause.

HIDRADENITIS SUPPURATIVA (Inverse acne)

HS is chronic, non-contagious, follicular occlusion condition resulting in painful nodules and abscesses in characteristic location of the axilla and groin. After the occlusion of the hair follicle with desquamated keratin debris, the distending follicle enlarges with accumulating trapped keratin, until there is rupture of distended follicle with resulting foreign body reaction. This results in non-infectious abscess formation, chronic sinus tract and healing with hypertrophic scarring with lymphdema and deformity. The prevalence of HS is around 4% population.[85]It often begins after menarche and improves after menopause.Women are more commonly affected with ratio of 2:1 , predisposing factors being obesity, diabetes milletus, smoking.[86]Few reports of familial involment is there.

MUCINOUS CYSTS

Mucinous cyst of the vulva are not uncommon. They are usually found in the vestibule where they develop secondary to obstruction of the duct of the many minor mucinous duct. The cyst are of urogenital sinus origin and not of mullerian origin as once thought before.

BARTHOLINS DUCT TUMOR

These are very rare and there is debate as to whether they are true neoplasms or better regarded as they are true hyperplasia or hamartomas.

NEUROFIBROMAS AND NEUROFIBROMATOSIS

Vulval neurofibromas may occur either as solitary lesion with no other features of neurofibromatosis, or as part of generalized neurofibromatosis .In one series,18% had vulval lesion.[87] Vulval neurofibromatosis have also been described as one component of localized neurofibromatosis of female genitourinary tract.[88]

GLOMUS TUMOR

There are rare reports of this tumor on labia majora giving rise to dyspareunia.

LEIOMYOMA

Vulval leiomyomas are uncommon**,** and there is no association with uterine leiomyomas. Vulval leiomyomas occur during the reproductive years and usually present as well-circumscribed ,painless, non- tender nodules or swelling in the labia. Lesions may enlarge in pregnancy.[89]A clitorial leiomyoma can cause a mistaken diagnosis of an intersex disorders.

OTHER BENIGN TUMORS

Rare tumours include granular cell myoblastoma, which present as flesh coloured pedunculated or ulcerated lesion. Verruciform xanthomas have a predilection for oral and genital mucosas.[90]They are rare on vulva. Urethral caruncle or urethral prolapse, which are common can sometimes be mistaken for neoplasms. Urethral caruncle occur in post menopausal women as red fleshy lesion around the urethral meatus and is chronically inflamed eversion of urethral mucosa. It may measure from a few millimeter to few centimeter in diameter and is usually asymptomatic, it may cause dysuria or bleeding if ulcerated.

PRECANCEROUS DERMATOSES

Vulval Intraepithelial Neoplasia

Differentiated VIN remains as the term reserved for severe atypia confined to the basal layers, most often seen on a background of chronic scarring, dermatoses. It was also proposed that vulval EMPD and melanoma in situ should not be included in the VIN classification.[91]

UNDIFFERENTIATED VULVAL INTRAEPITHELIAL NEOPLASIA

Synonyms

- Bowens Disease
- Bowenoid Papulosis
- Carcinoma in Situ
- Carcinoma Simplex

Originally, two distinct histological types of VIN were described : **Bowenoid** characterized by individual cell keratinization and abnormal cell differentiation and **Baseloid** with atypical parabasal cell extending throughout the full thickness of epithelium. However, Both types can sometimes be found in same histological section, so its no longer considered helpful to distinguish two. Multifocal anogenital disease is strongly associated with oncogenic papillomaviruses, particularly HPV16 & 18 and almost exclusively occurs in smokers.[92]The condition is caused by the failure of the host to mount an immune response to the HPV. In addition to being multifocal, VIN may be associated with multicentric disease, with lesions of intraepithelial neoplasia involving the cervix, vagina and perianal skin. Upto two-third of patients with VIN have current or past history of CIN.[93] Clinically, lesions of Intraepithelial neoplasia can be multiple or solitary. The morphology of the lesion is diverse with lesion that resemble viral warts, plaques that may be shiny and smooth, skin coloured, red or white, or others that are warty and pigmented that resemble seborrhoeic keratoses . Less commoly ,the lesions may be large and papillomatous, particularly perianally ,where they may be polypoid.[94]The main symptoms is pruritus ,which can be severe and troublesome. Vaginal involment is uncommon. Initialy, it was felt that BP could be differentiated histopathologically from Bowens disease but time has proved this not to be the case. The risk of progression to invasive disease is estimated as 10% or less in multifocal disease, but the risk is higher in immunocompromised patients, perianal disease and in older women with solitary plaque.[95]

DIFFERENTIATED VIN

This form of VIN is reportly rare, but perhaps it is underdiagnosed due to subtle histological changes that occur. The atypia confined to the basal layer, and this type of VIN seen in the background of lichen scleroses where there is already a microinvasive carcinoma , or just prior to the development of invasive disease. There may or may not be epithelial hyperplasia as well. To date there has been no strong association of this type of VIN with the known oncogenic HPV viruses.

PAGETOID VIN (PAGETOID BOWENS DISEASE)

A rare histological variant of VIN resemble extramammary Pagets disease is known as pagetoid VIN or pagetoid bowens disease. Pagetoid bowens disease has been reported genital and extragenital in males. There is one report of vulval involment.[96]

PIGMENTARY DISORDERS

HYPOPIGMENTATION

As in other site it can be nevoid, post - Inflammatory or vitiligo.

VITILIGO

Vitiligo is an acquired depigmenting disorder affecting (0.5-1) % of worlds population.[97]According to the consensus definition given to generalized vitiligo vulgaris by Vitiligo European task force (VETF) it is a chronic pigmentation disorder characterized by white patches , often symmetrical , which usually increase in size with time, corresponding to the substantial loss of functioning epidermal and sometimes hair follicle melanocytes.[97]It usually starts at the early age and doesn't

have predilection to either sex. Several theories regarding etiology have been proposed with the most evidence supporting an autoimmune phenomenon associated with underlying genetic predisposition. Amongst the various types of vitiligo, vitiligo vulgaris and segmental vitiligo has more of genital involment and has devastating impact in the quality of life of women as it is believed to be a sign of leprosy or sexually transmitted infection previously.[98]So, it imparts an emotional and mental burden leading to sleep disturbances, depression, anxiety and dysthymia.[99,100]

Mucosal subtype of vitiligo which is a type of localized vitiligo which describes isolated depigmentation of the lips, genital and oral mucosa, which is rare type affecting about10% of cases with dark skin phenotype in India.[101]The mixed type of vitiligo is a new and confusing entity, as it comprises different types of vitiligo in the same patients body but the number of such reported cases in the literature is too small to understand the real nature of this type.

LEUCODERMA

Leucoderma, which is the closest differential diagnosis of vitiligo can occur anywhere in the body but mainly starts after contact with chemical or depigmenting agents. The lesions are localized to the area of contact and becomes repimentented after the etiological factor is removed. Common chemical causing leukoderma are dye, perfumes, insecticides, phenolic compounds, hydroquinone and mercuric iodine containing germicidial soap.[102]

HYPERPIGMENTATION

The increased pigmentation can be caused by haemosiderin, which result in reddish brown discoloration and it is the result of extravasation of RBC's. It is seen in capillaritis, urethral caruncle, lichen scleroses, Zoons vulvitis and chronic vulval purpura. However, increase in pigmentation is more commonly related to melanin. Post inflammatory pigmentation may follow any of the inflammatory dermatosis, particulary if there has been distruption in the dermoepidermal junction and in darker skins. It is common sequlae of LP and sometimes LS and of fixed drug eruption. Trichomycosis and chromhidrosis may cause some discolouration. Intense macular hyperpigmentation of vulval skin can be difficult to categorise, and a biopsy is essential for accurate diagnosis and to exclude malignant melanoma. If the lesions are widespread and accompanied by oral pigmentation, they may be considerd as example of Laugier-Hunziker syndrome. The term vulval melanosis is used for those cases where there is extensive macular pigmentation affecting the vulval skin, with histological changes of basal hypermelanosis and slight increase in the number of melanocytes. The accepted view is that vulval melanosis is a benign condition, but there are long term follow up studies recorded. Vulval lentigenes may be sporadic or part of syndrome Dowling- Degos disease which is a rare inherited disorder presents in about the fourth decade with freckle like lesion in flexural areas, which may be confined to the vulva.

PHYSIOLOGICAL HYPERPIGMENTATION

Different skin types show different degrees of pigmentation on the vulva. Physiological hyperpigmentation is normal hyperpigmentation that is most common in individuals who are darkly complexioned and is accentuated at the posterior

introitus, the tips of the labia minora and perianal skin. The proximal, medial thighs sometimes exibit uniform hyperpigmentation that fades to the colour of nonmodified mucous membrane. The lesions are macular, symmetric and no change in texture from normal skin and is asymptomatic. Genital tissue has a higher density of melanocytes than the rest of the body, magnifying the effect of physiologic hyperpigmentation.[103]The degree of hyperpigmentation can change with different hormonal stages such as adolescence and menopause as well as pregnancy and contraceptive use.

POST INFLAMMATORY HYPERPIGMENTATION

PIH occurs in patients of all skin types**,** including on the vulva. It presents as macules and patches of varying shades of brown, which are usually less symmetric than physiologic hyperpigmentation and occurs most often in a distribution of previous injury or dermatosis. Cause of PIH include inflammatory skin disease, trauma, dermatologic treatments and fixed drug eruption.[104]The basement membrane disruption of these diseases allows melanin release into the dermis causing pigmentation. If the pattern of pigmentation is atypical, the diagnosis should be confirmed by biopsy.

ACANTHOSIS NIGRICANS

Acanthosis nigricans can also be found on the vulva and consists of same velvety, leathery, wrinkly texture with darkened appearance as on other parts of the body and is often associated with skin tags within skin folds.[105] It is most often associated with diabetes mellitus, obesity and medications such as niacin and

prednisone. AN can usually be distinguished from physiologic hyperpigmentation by its velvety texture and usually sparing of mucous membranes.

VULVAR MELANOSIS/ LENTIGINOSIS

Roughly 68% of pigmented vulvar lesions in reproductive age women are lentigines.[106]It usually presents as multiple, asymptomatic, asymmetric macules that have the following features-tan to black colouration, irregular borders. Their macular, nontextured nature is an important distinguishing factors from other vulval lesions.[107]Diagnosis is largely made by inspection and biopsy confirmation and dermoscopy may play a role as well.

Few Genodermatoses characterized by lentigines [108,109]

a. Bannayan-Ridley– Ruvalcaba syndrome – Triad of macrocephaly, genital lentiginosis and intestinal polyposis.
b. LAMB syndrome - Triad of myxomas, black and blue nevi.
c. Dowling – Degos Disease – Flexural reticular pigmentation with pigmented genitalia.
d. LEOPARD syndrome - Characterised with Hypertelorism, sensorineural deafness and cardiac abnormalities.
e. NAME syndrome - Hypercortisolism, mucocutaneous lentigines and non-endocrine & endocrine tumors.

LICHEN SIMPLEX CHRONICUS

It is an eczematous disorder characterized by itching, scratching, and lichenification. The condition is the end stage of an itch-scratch-itch cycle and is also known as neurodermatitis, pruritus vulvae, squamous hyperplasia, and hyperplastic dystrophy.[110]The etiology includes numerous irritative and infectious disorders including candidiasis, atopic dermatitis, contact dermatitis and eczema. The intense chronic itching caused by these condition leads the patients to repetitively rub and scratch the affected area. The skin responds by thickening and developing a coarse texture, with increase skin markings called lichenification. The skin may appear edematous and excoriated with or without fissuring and pubic hair may be broken or absent.[111]Women with this condition are frequently aware of their vulva and may feel self conscious with respect to physical intimacy. Patient should be educated about the condition and to break the itch – scratch -itch cycle.

VULVAL OEDEMA, LYMPHANGIECTASIA, LYMHOEDEMA

Oedema, hereditary angioedema, dermographism may involve the vulva. Vulval oedema may be the only manifestation of Crohns disease. Lymphoedema occurs when there is impairment of lymphatic drainage and it is a frequent complication following surgery and lymphadenectomy for vulval carcinoma. Lymphangiectasia is acquired dilatation of the skin lymphatics secondary to obstruction of lymphatic vessel and anasarca secondary to generalized medical condition. It is most frequently reported following treatment of cervical carcinoma with surgery or radiotherapy.[112] Complete decongestive therapy is generally effective on non fibrotic lymphedema. This aims at moving the lymphatic fluid and breaking up fibrotic tissue. It consists of manual manipulation of lymphatic ducts, use of

compression bandages, therapeutic exercises and skin care.[113]In cases that seem resistant to conventional therapy, the rare connective tissue tumors and neoplasms should be considered

VULVAL PAIN SYNDROMES

Vulvodynia - The term vulvodynia was first introduced in 1983 to categorise those patients who complained of chronic sensation of burning or rawness of the vulval skin.[114]A diagnosis of vulvodynia should be reserved for those patients who have the symptoms of pain and discomfort for 3 months in absence of any visible abnormality or explanation that would account for their symptom. In clinical practice there appear to be two type of vulvodynia - vestibulitis and dysasthetic vulvodynia.

VESTIBULODYNIA (VESTIBULITIS)

The term vulval vestibulitis was first defined as triad of clinical signs and symptoms that included dyspareunia, vestibular tenderness to light touch and erythema of the vestibular epithelium. It is usually a disorder of younger women, who presents with complaints of secondary dyspareunia. Most patients gives a history of precipitating event and some recall that it started during a particular stressful time.

DYSAESTHETIC VULVODYNIA

Dysaesthetic vulvodynia is most frequently seen in older, postmenopausal women who are often not sexually active and there is usually no precipitating event of thrush or a urinary tract infection that the patient can recall. The pain is spontaneous and often occurs independently of touch. Many of these patients are depressed , but it is difficult to establish whether this is primary phenomenon or secondary to chronic pain.

MATERIALS AND METHODS

The Study was conducted between December 2011 to March 2013. All female patients reporting to the Department of Dermatology in R.L. Jalappa Hospital and Research center attached to Sri Devaraj Urs Medical College were evaluated for entry into the study and patients having genital lesions were enrolled in the study.

A written consent was taken. Thorough history like chief complaints, duration of the disease, vaginal discharge, sexual functions, urinary symptoms, any treatment, drug history (OCP or HRT) was taken. Personal and family history of atopy, psoriasis or autoimmune disease was asked for.

- ***Inclusion criteria*:**

All female patients attending the Dermatology OPD was screened for inclusion.

- ***Exclusion criteria*:**

a) Sexually transmitted infections.

b) All post traumatic cases.

c) Post-Surgical cases.

d) Congenital malformations.

e) Malignancies.

EVALUATION

For the study, detailed history including the age, occupation, duration of the disease and site of affection and history of exposure was taken. Physical examination was done to see any associated lesions elsewhere in the body. Investigation like KOH mount, Grams stain, biopsy, histopathological examination was done to establish diagnosis whenever required. The patients satisfying the inclusion and exclusion criteria as mentioned were taken after an informed written consent. The study included 150 patients presenting with genital, orogenital and skin lesions of non-venereal conditions presenting over a period of 15 months from DEC 2011 to March 2013. Data was collected from the selected subjects by recording relevalent patients details and a thorough general, systemic and dermatological examinations. A proforma was prepared to record the relevant details of the patients, examination, investigation result and diagnosis. The data were finally tabulated and analysed.

OBSERVATIONS

The following observation were made in the study

1. Total number of cases studied – 150
2. Total number of dermatoses observed – 26
3. Most common dermatoses observed –Folliculitis
4. Most common area of involvement- Labia majora
5. Most common age group affected – (21-40) years
6. Number of patients with systemic association- 43
7. Most common presenting complaints – Itching
8. Most of the patients were housewifes – 84
9. Most common genital dermatoses with involvement of skin – Vitiligo
10. Most common Oro-genital dermatoses – Vitiligo
11. No of patients affecting after puberty– 115.

RESULTS

The present study includes totally 150 clinically diagnosed cases of female genital dermatoses.

I) **Age–** The common age group range from 3months to 63 years with the mean age of 26years. Majority of the patients are in the age group of 21- 40 years(61%) followed by 41-60 years(28%).

II) **Occupational status** – The majority of the patients were housewifes 84 (56)%, followed by teacher 23(15%) and agriculturist 11(7%).

Table 1 : LIST OF DERMATOSES

Sl. No.	Conditions	No. of patients	Percentage
1.	Folliculitis	25	16
2.	LSC	22	14
3.	Vitiligo	21	14
4.	Candidiasis	13	8
5.	Intertrigo	13	8
6.	Psoriasis	9	6
7.	T.Cruris	5	3
8.	Scabies	5	3
9.	LSEA	4	2
10.	LP	4	2
11.	SJS	4	2
12.	Cyst	3	2
13.	ICD	3	2
14.	Vulval Edema	3	2
15.	BP	3	2
16.	PV	2	1
17.	Others	10	6

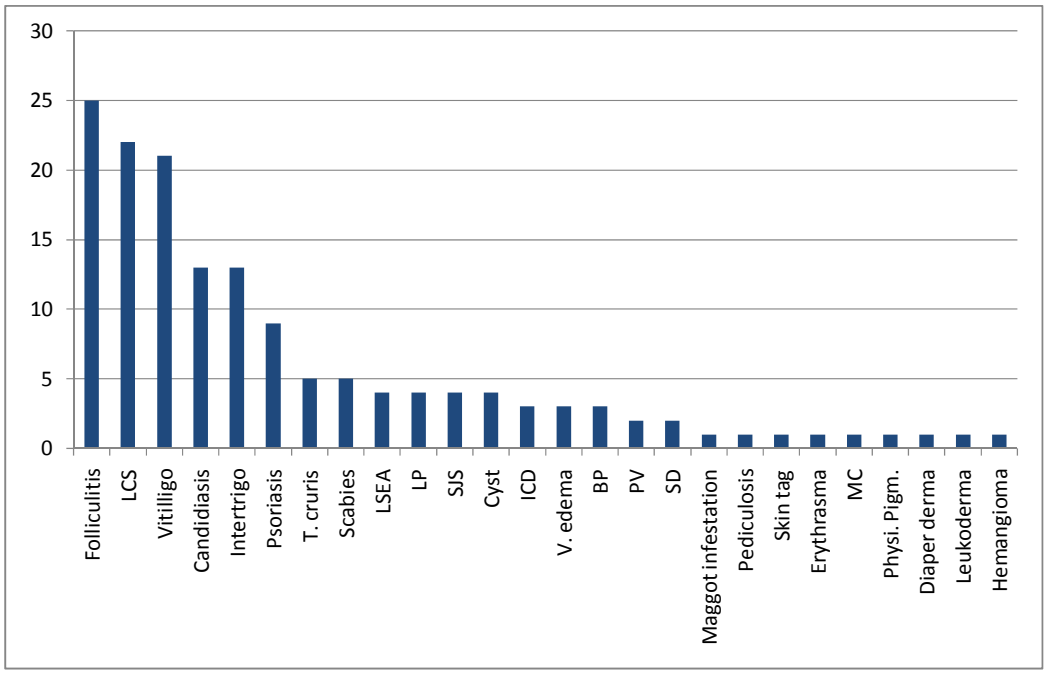

Fig 2 : COMMON DERMATOSES

TABLE 2 : AGE DISTRIBUTION

Age (Yrs)	No. of patients	Percentage
0-20	10	06
21-40	92	61
41-60	43	28
> 60	05	03
Total	150	100

Fig 3 : Age wise Distribution

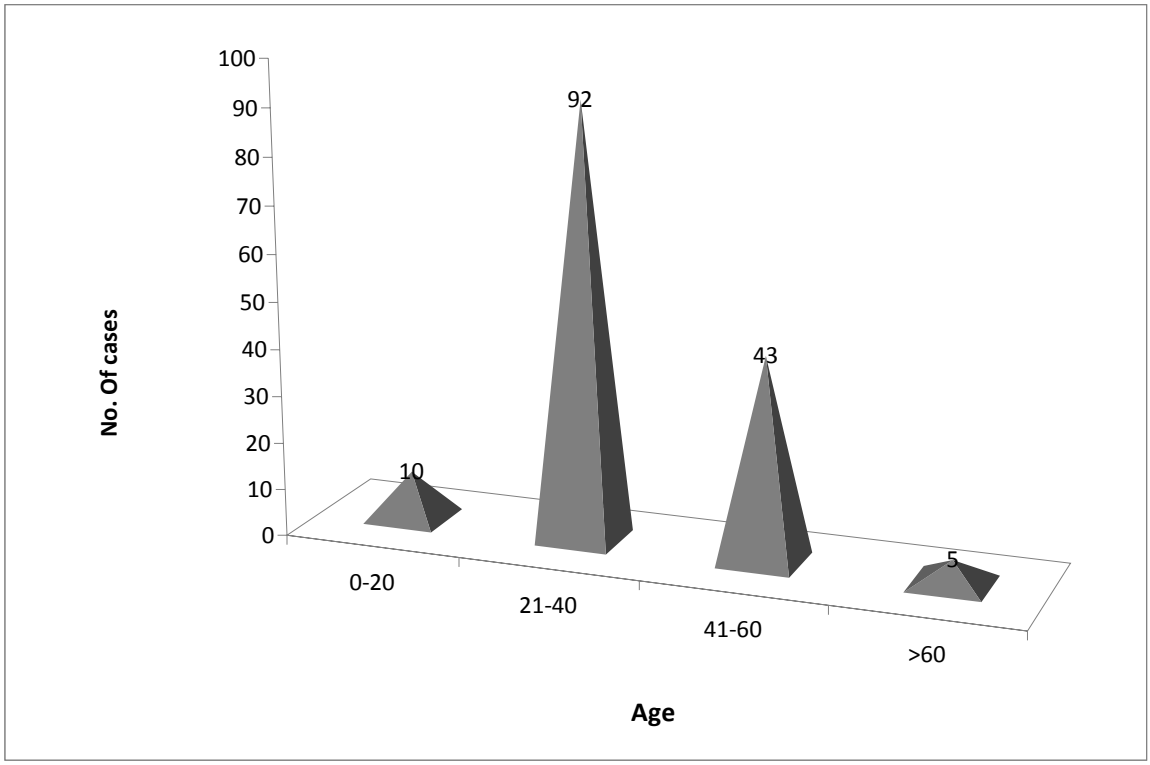

In the present study of 150 patients, 10 patients belongs to age group 0-20yrs, 92 patients belongs to 21-40yrs , 43patients belongs to 41-60 yrs and 5 patients were more than 60 yrs.

TABLE 3: ASSOCIATED SYSTEMIC DISEASES

Sl.no.	Associated disease	No. of patients	Percentage
1.	Diabetes mellitus	13	8
2.	Hypertension	09	6
3.	Thyroid related disorders	07	4.6
4.	Asthma	05	3
5.	Anemia	04	2.6
6.	Cataract	03	2
7.	Others	02	1

Fig 4 : ASSOCIATED SYSTEMIC DISEASES

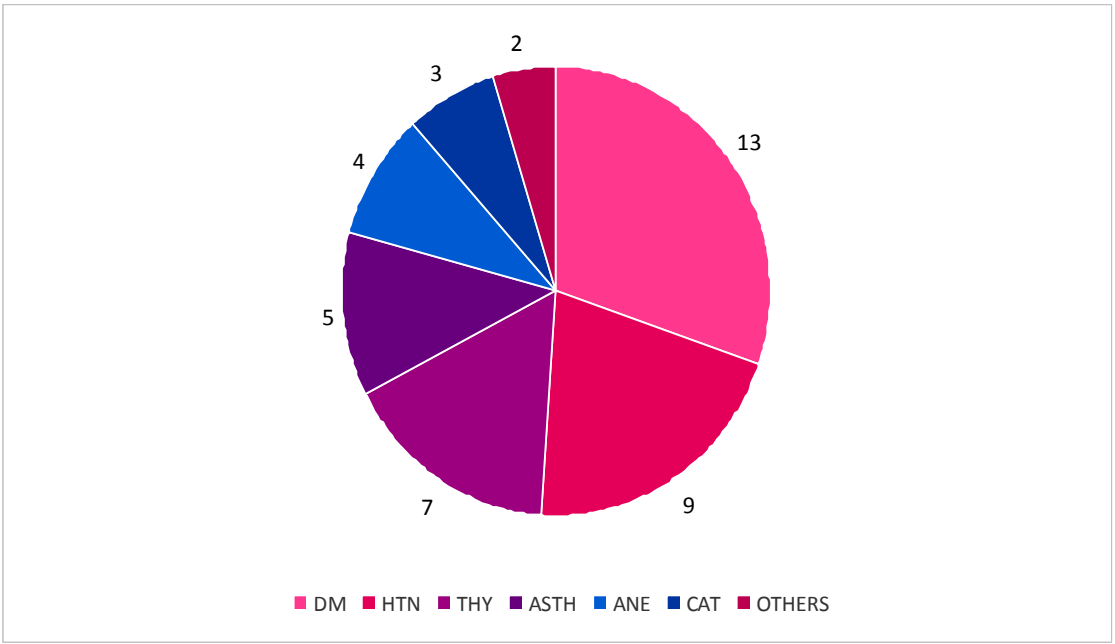

In the present study,13patients had DM-2 as associated systemic disease, 9 patients had HTN, 7 patients had thyroid disorder, 5 patients had Asthama, 4 patients had anemia and 3 patients had cataract. Among total of 150 patients, 41 patients had associated systemic diseases.

TABLE 4: AREA OF INVOLVEMENT

AREA INVOLVED	NO. OF CASES	PERCENTAGE
Labia majora	**96**	**64**
Labia minora	**19**	**12.7**
Introitus	**13**	**8.7**
Mons pubis	**09**	**6**
Vulva	**04**	**2.7**
Others	**09**	**6**

Fig 5 : Area of Involvement

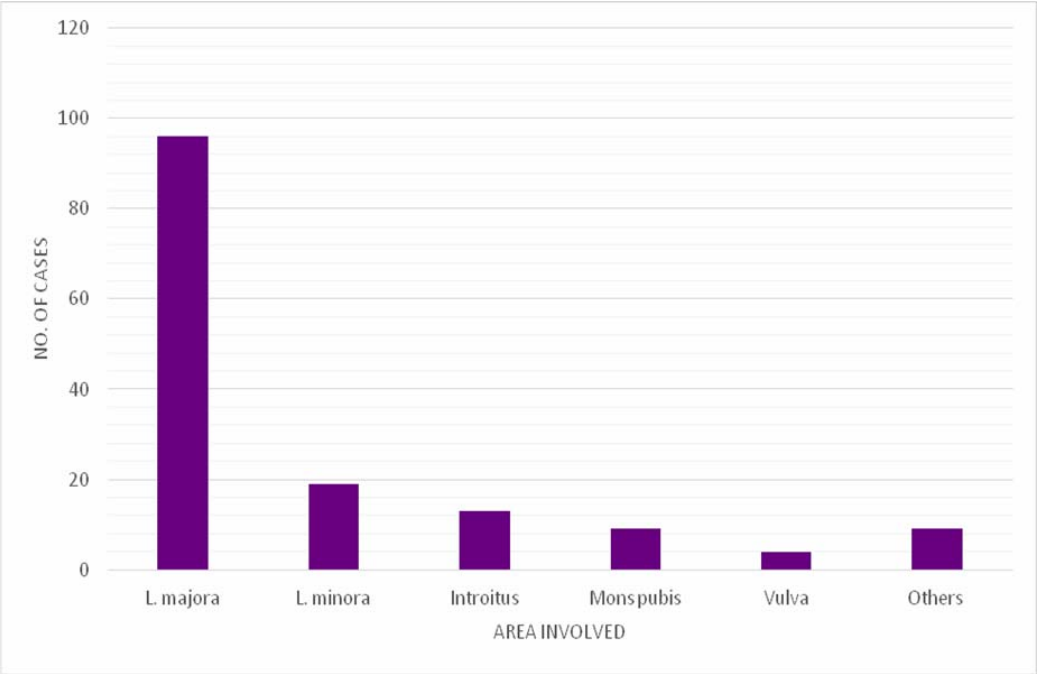

In the present study, 94 patients had labia majora as the most common site of involvement followed labia minora with 19 patients and Introitus with 13 patients.

TABLE 5: PRESENTING COMPLAINTS

COMPLAINTS	NO. OF PATIENTS	PERCENTAGE
Itching	56	37
White lesions	28	18.6
Pain	20	13
Fluid filled	16	10
Scaling	10	06
Discharge	08	05
Others	12	08

Fig 6 : Presenting Complaints

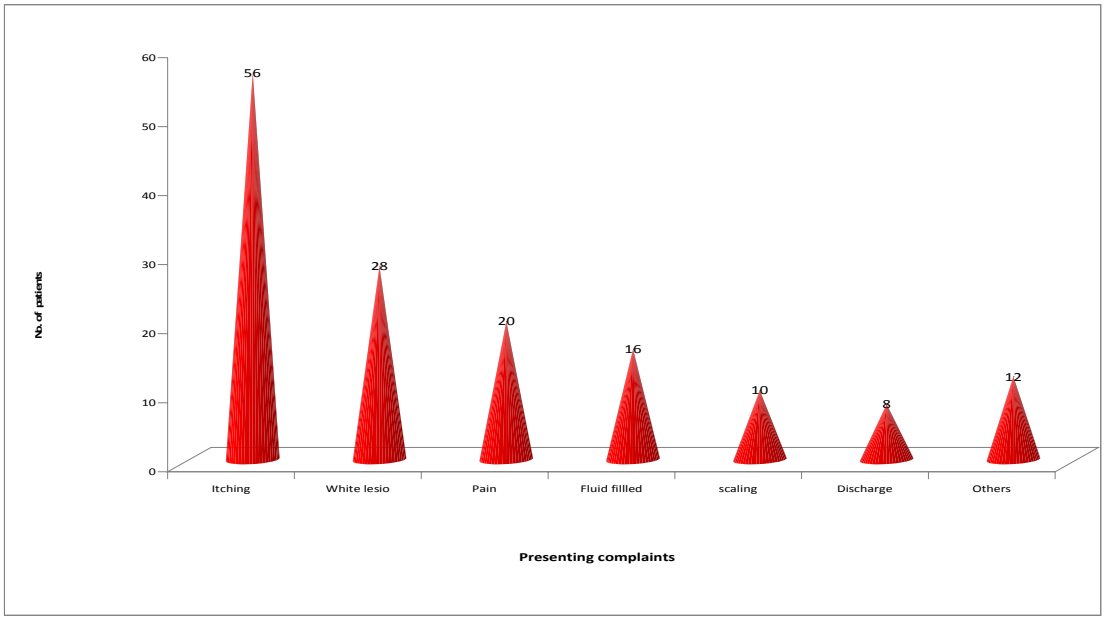

In this study, itching was the most common presenting complaints with 56 patients, followed by white lesions with 28 patients and pain with 20 patients.

TABLE 6: OCCUPATION

OCCUPATION	NO. OF PATIENTS	PERCENTAGE
Housewife	**84**	**56**
Teacher	**23**	**15**
Agriculturist	**11**	**7**
Labourer	**07**	**4**
School going	**07**	**4**
Others	**21**	**14**

Fig 7 –Occupation

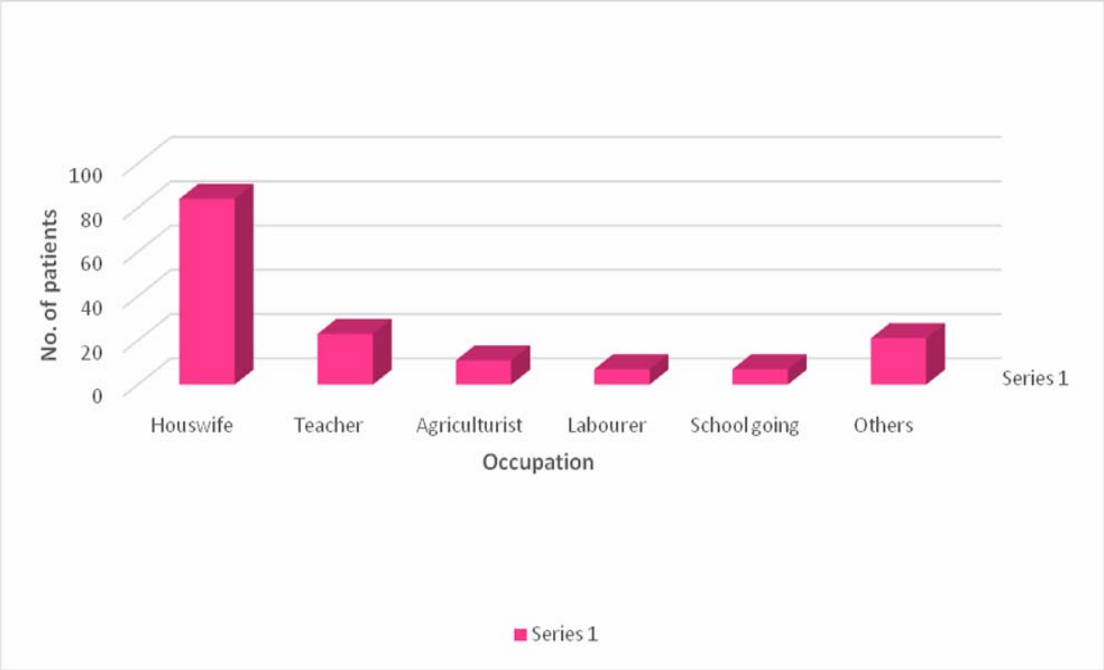

In the present study, most of the patients were housewifes with 84 patients, followed by teacher with 23 patients and agriculturist with 11patients.

TABLE 7: Genital Dermatosis associated with Skin disorders

Associated Dermatoses	No of Patient
Vitiligo	07
Psoriasis	05
Lichen Planus	03
T.Corporis	03
Bullous Pemphigoid	02
Pemphigus Vulgaris	02
Scabies	02
SJS	02
Seborrheic Dermatitis	01

Fig 8 Associated Skin Dermatoses

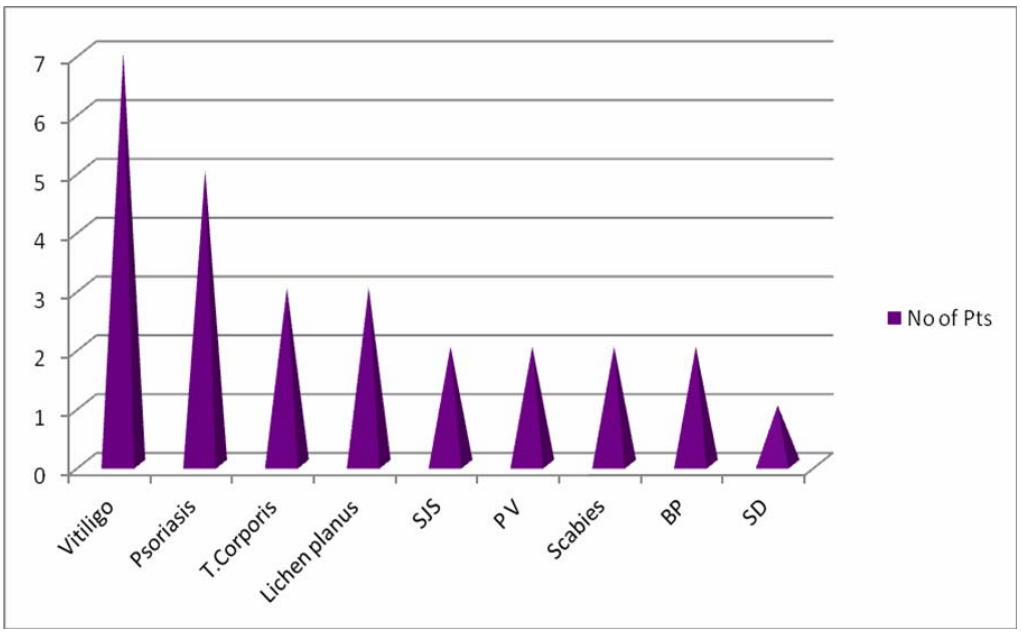

In the present study, Vitiligo was the most common dermatosis with 7 patients having both the genitalia and skin involvement, followed by psoriasis with 5 patients and T.corporis with3 patients and Lichen planus.

TABLE 8 - ASSOCIATED ORO - GENITAL LESIONS

CONDITIONS	NO OF PATIENTS
Vitiligo	**5**
Candidiasis	**2**
Pemphigus vulgaris	**2**
SJS	**2**
Lichen planus	**1**

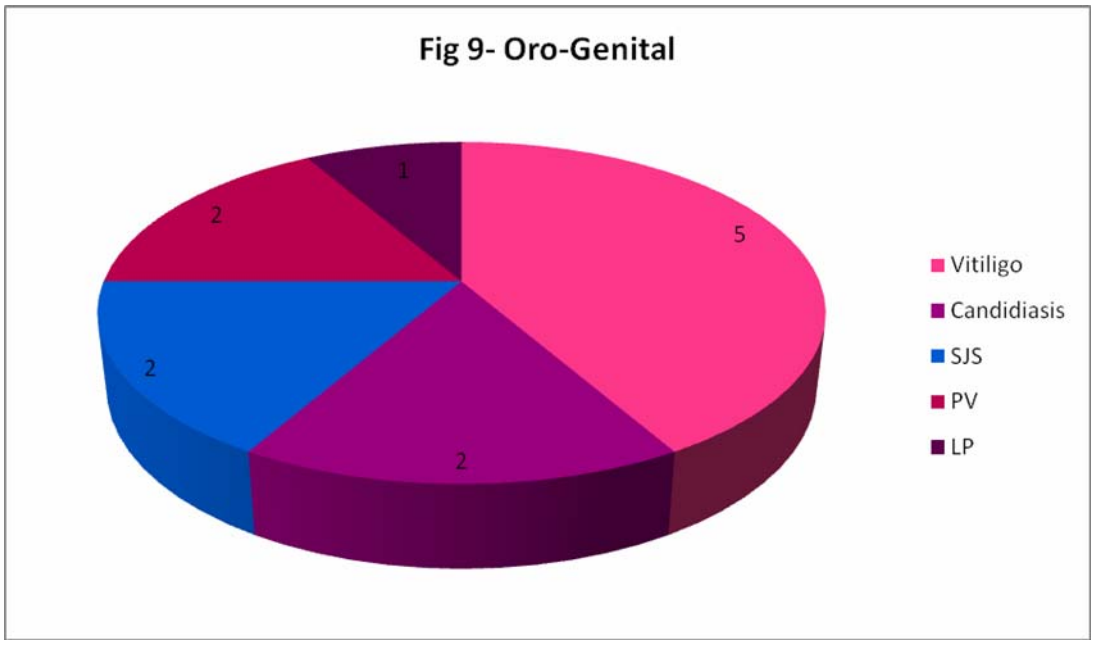

In the present study, vitiligo had both oro-genital involvement with 5 patients, followed by Candidiasis with 2 patients, SJS with 2 patients and Pemphigus vulgaris with 2 patients.

TABLE 9: AGEWISE DISTRIBUTION WITH RESPECT TO SEXUAL MATURITY

	Pre-pubertal (<12 yrs)	**Post- ubertal (>12yrs)**	**Post- menopausal (>50 yrs)**
No. of patients	**7**	**115**	**17**

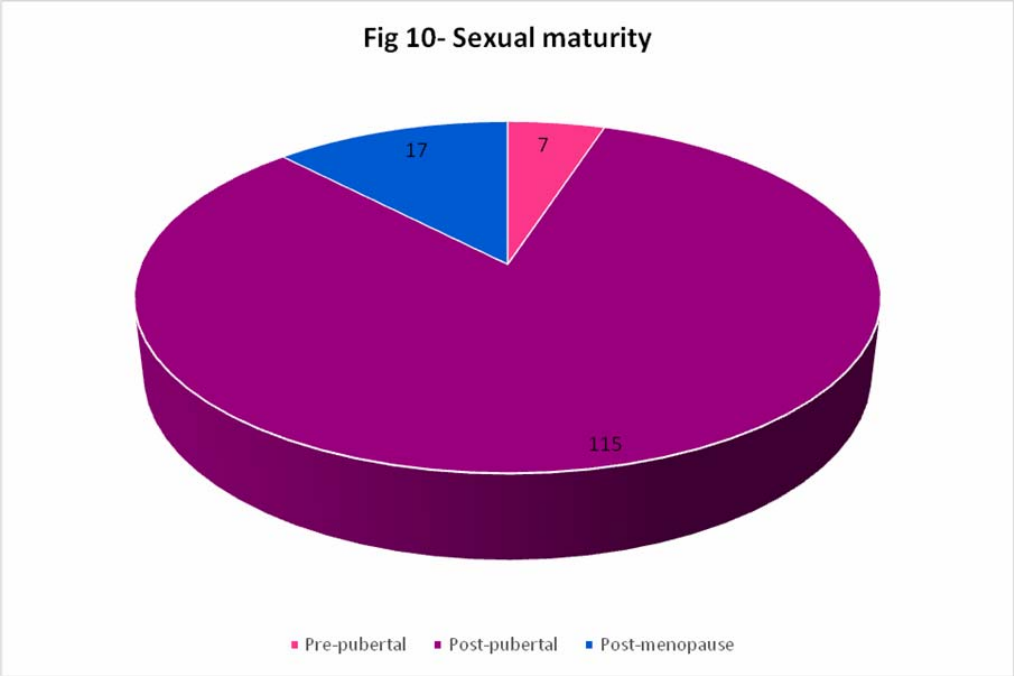

In the present study, 115 patients were post pubertal followed by 17 patients who had already attained menopause and 7 patients who had not attained menarche.

Fig 11- Folliculitis involving External genitalia and buttocks

Fig 12- Folliculitis involving Labia Majora

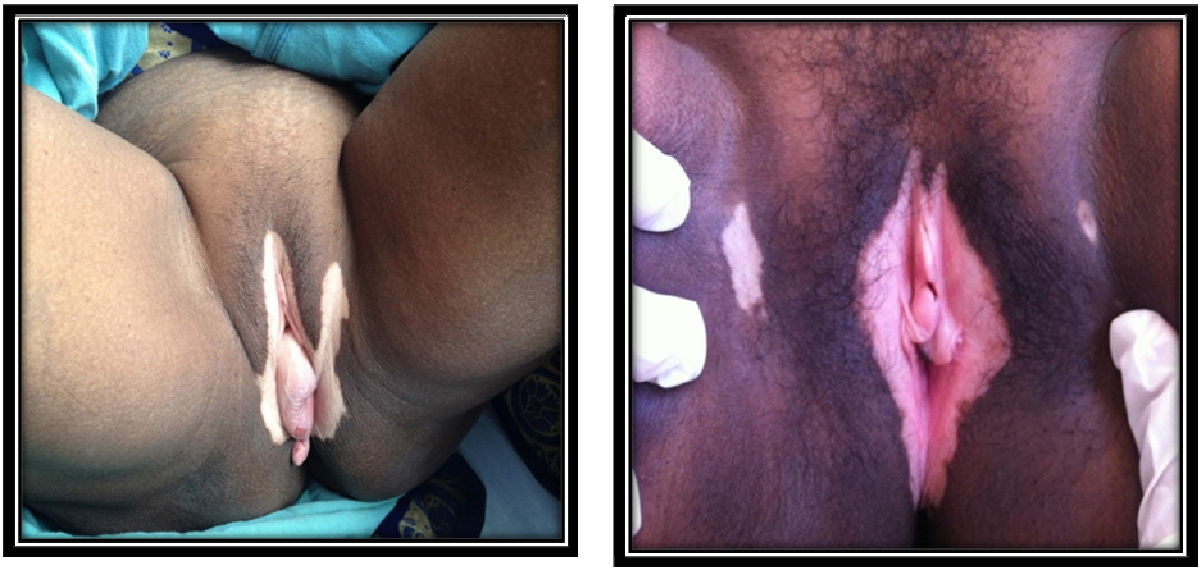

Fig 13 – Mucosal Vitiligo

Fig 14- Hemangioma in 3 month old girl

Fig 15 – Maggot infestation after Vaginal delivery

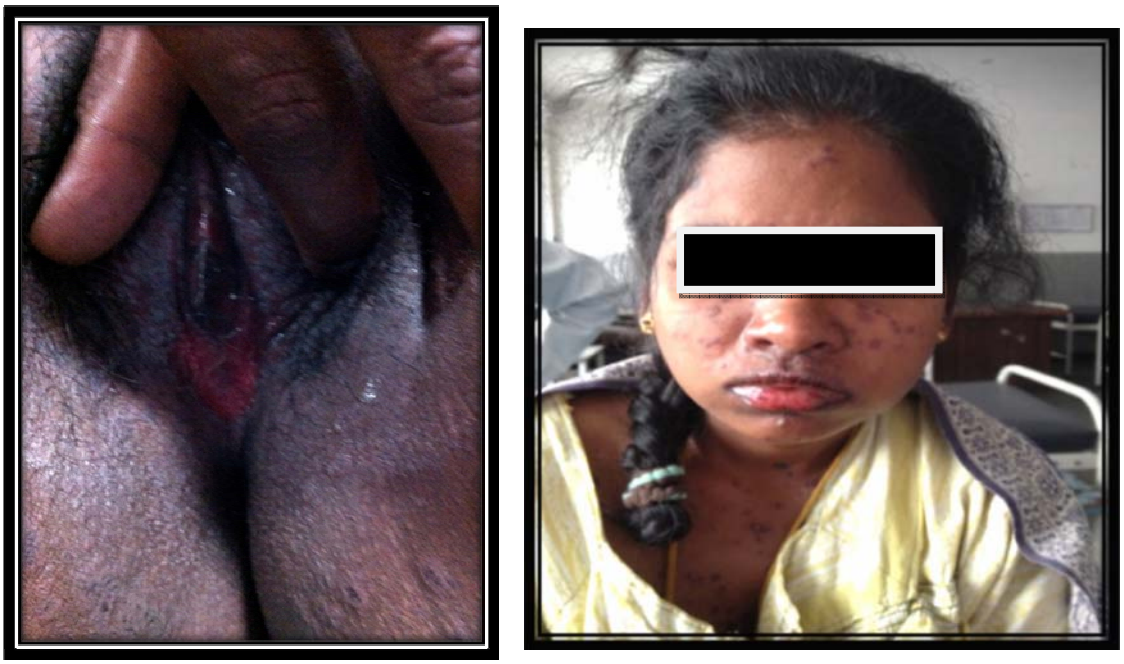

Fig 16 : Steven Johnsons Syndrome involving Genital and Oral Mucosa.

Fig 17- Bullous Pemphigoid in 70 year old lady

Fig 18 –Lichen Planus involving oral and Genital mucosa.

Fig 19-Lichen Sclerosus et Atrophicus

Fig 20 - Cystic lesion in labia minora

Fig 21- Irritant Contact Dermatitis

Fig 22 – Vulval Edema

Fig 23- Impetigo involving external genitalia.

DISCUSSION

Non -Venereal genital disorder includes a wide array of diseases with varied etiology. Not many comprehensive studies exist with regard to pattern and distribution of the lesion. Singh et al had done a study on pattern of non-venereal Dermatoses of female genitalia in south India.[114] Puri et al has done a similar study in Punjab.[115]

AGE:

Age ranged from 3months to 60 years and above in the present study, whereas the age was from 1month to 80 years in the study population by Acharya et al.[116]
The age range varied from 1to 85 years in the study by Singh et al with the mean age of 37 years among the female patients from a total of 120 patients.

Another study in Punjab by Puri et al in both male and female patients with genital dermatoses had age group 21- 40 years with maximum number of cases recorded and males outnumbering the females.

Most of the patients belong to age group of 21- 40 years (61%) in the present study whereas in contrast , another study by Singh et al most common dermatoses were in post-menopausal age group with 41%.

OCCUPATION:

The majority of patients were housewifes 84 (56%) followed by teacher 23(15%) in the present study.Various other studies had labourers (48%,74% and 35%) forming the predominant occupational group in their respective studies[114,115,116].This is mostly due to dependent population being rural population.

COMMONEST NON-VENEREAL DERMATOSES:

In the present study, a total of 26 different types of non- venereal dermatoses encountered. Singh et al had 19 different dermatoses in their study .The most common disorder was genital folliculitis which accounted 25(16%) followed by Lichen simplex chronicus 22(14%) and Vitiligo with 21(14%) in the present study whereas Singh et al reported lichen sclerosus(21%) as the most common disorder followed by vitiligo (15%). In another study by Puri et al also, Lichen Sclerosus atrophicus was the most common dermatoses 3(15%) followed by Lichen simplex chronicus 2(10%).

LICHEN SIMPLEX CHRONICUS

LSC was seen in 22(14%) patients in present study with the most common symptoms being itching 56(37%) and most common site being labia majora 96(64%). In the study by Singh et al 16(13.3%) cases with LSC were recorded with pruritus being the common symptom similar to the present study. In another study by Puri et al also, LSC was one of the common dermatosis 2(10%) with itching and hyperpigmentation being the most common symptoms. In study by Karthikeyan et al also in male population, LSC is recorded as the most common dermatosis. [117]

VITILIGO

Vitiligo was one of the commonest disorder which accounted for 21(14%) cases of total study population in present study and most common site of involvement being labia majora and minora 96(64%) whereas Vitiligo was the most common dermatoses accounted with 19 cases with symptoms being asymptomatic white discoloration over the labia majora and labia minora as the most common site of

involvement in the study by Singh et al. In another study by Puri et al Vitiligo formed 15 %of the non -Venereal dermatoses in female in similar to reported by Singh et al.

LICHEN PLANUS

Genital lichen planus was encountered in 4 (2%) patients in the present study with 3(2%) associated genital and skin involvement and 1 patient with oro - genital involvement whereas in study by Singh et al 3 female patients had genital involvement in LP.[119]In another study by Cheung et al in 200 patients lichen planus accounts for (11.5%) 0f the total population.[120]

CANDIDIASIS

In the present study, genital candidiasis accounted for 13(8%) of the total population with symptoms being itching and burning sensation and among the 13 patients, 2(1%) had oro-genital involvement. In another study by Puri et al, 3(15%) had genital candidiasis with associated systemic DM-2. Singh et al encountered 11 patients of candidasis involving female external genitalia.

FOLLICULITIS

In the present study, folliculitis is being recorded as the most common dermatoses with 25(16%) patients and common symptom being pain with common site of involvement over the labia majora in the age group of (21-40) years whereas in another study by Puri et al 2 patients had folliculitis and furunculosis in contrast to the figure recorded in the present study. Similarly Singh et al also recorded very less case of folliculitis 7(5.2%) which is different from the dermatosis recorded in this study.

PSORIASIS

In this study, Psoriasis accounted for 9(6%) patients with 5(3%) patients having genital and generalized body involvement which is in contrast to the study by Puri et al which accounted in only 2(10%) patients with only genital involvement. Singh et al reported 5 cases of psoriasis involving female genitalia which is one of the common inflammatory condition.

SEBORRHEIC DERMATITIS

In the present study, only 2(1%) patient had seborrheic dermatitis with genital involment mainly the labia majora and itching, pain and burning being the common presenting complaints with other body area involvement in 1 patient which is same as study by Puri et al who also reported only 2 cases of seborrheic dermatitis in his study.

LICHEN SCLEROSUS ET ATROPHICUS

In this study, 4(2%) patients of LSEA were recorded mainly in the post menopausal age group with burning sensation and itching being the presenting complaints 4(2%) and change in colour 2(1%) whereas in study by Singh et al recorded 26 (21.7%) patients which is in contrast to the present study. Another study by Puri et al , he recorded 3(15%)patients of LSEA which has close similarity to the present study. In all the study compaired above, postmenopausal age group were the common presenting age group.

STEVEN JOHNSONS SYNDROME

Four cases of SJS (2%) recorded in present study mainly with the suspected drug as sulfonamides, nimuselide, ayurvedic drug. Out of 4, 2 patients had oro-genital involvement and 2 had other body part involvement with first symptom being fluid filled lesion and then burning whereas in study by, Puri et al and Singh et al, no cases of drug eruption was recorded in their studies. In the study by Meneux et al, toxic epidermal necrolysis with involvement of labia majora and vulva was reported.[121]

IRRITANT CONTACT DERMATITIS

Irritant contact dermatitis was seen in 3(2%) patient in the present study which was caused by sanitary napkin, hair removing cream and antifungal. Singh et al encountered 2 cases of irritant dermatitis to antiseptic lotion. In study by Puri et al, 3 patients had ICD due to antiseptic lotion and female condoms which is similar to our study.

IMMUNO BULLOUS BLISTERING DISORDER

In the present study, 2(1%) patients of Pemphigus Vulgaris was recorded with initial area of lesion being scalp with oral and genital mucosa. 2(1%) of patient had oro-genital involvement and 2(1%) patients had skin and genital mucosa involment. Pemphigus vulgaris with oro-genital involvement was noticed in one female patient who had associated seizure disorder. Vulvar involvement of Pemphigus Vulgaris was reported by Marren P et al.[122] 3(2%) patient had Bullous Pemphigoid with genital involvement in 70 year old lady with the common site of involvement being labia majora and mons pubis .

CYST

In the present study, 3 (2%) patient of cystic lesion were recorded mainly on the inner lip of the labia minora whose proper diagnosis could not be made out. Singh et al reported cystic swelling in female patient in his study which is similar to our study.

SCABIES

In our study, 5(3%) patient had scabies with genital involvement mainly the mons pubis and labia majora with involvement of whole body and family being other associated finding where as in study by Singh et al and Puri et al, scabies with genital involvement has not been recorded

OTHER INFECTIONS

Present study had T.cruris 5(3%) patient and intertrigo 13(8%) patient accounted with common symptoms being itching and burning sensation with common site being labia majora and mons. In another study by Singh et al 8 patients with pyoderma and 6 patients with T.cruris was recorded which is in contrast to study by Khoo et al where in his study not a single case of tineas cruris in female patients were recorded.[118]

VULVAL EDEMA

In the present study, 3(2%) patient of vulval edema due to folliculitis were recorded whereas in study by Singh et al 5 patients in the age group of 45 to 60 years were recorded secondary to radiotherapy induced lymphatic damage.

OTHER RARE CONDITIONS

A rare case of maggot infestation after vaginal delivery in 23 year old lady was recorded which has not been recorded in any of the previous studies.

A case of extensive pediculosis capitus and pubis was recorded in young emaciated girl which is very rare presentation of non-venereal dermatoses.

One patient of molluscum contagiosum of labia majora was noted in a young girl with involvement of other body area following self inoculation.

A case of physiological hyperpigmetation, hemangioma , diaper dermatitis each was recorded which is mainly seen in prepubertal age group. Similar study by Fischer and Rogers et al in prepubertal age group in130 patients, irritant dermatitis and lichen slerosus was recorded in 44 patient in contrast to our study.[123]

A case of erythrasma, Leukoderma and acrochordon was also encountered in the present study which has not been recorded in any other studies done previously.

No premalignant lesions were noticed in the present study. The reason may be due to less prevalence of the disease among the study population.

SUMMARY

- Non- venereal genital dermatoses cause a wide variety of confusion to the patient and treating doctor because of its close resemblance to venereal dermatoses and cause a mental distress and guilt feeling to the affected patients.
- A series of 150 female patients with non-venereal dermatoses were studied among the patients attending the OPD.
- The age ranged from 3 months to 65 years with the mean age 26 years and median age 35years, majority in the age group of (21-40)years, 92(61%) which is reproductive age group.
- The non – venereal genital lesions were grouped into 4 groups according to the involvement of site with labia majora 96 (64%), most common dermatoses being folliculitis 25 (16%), oro-genital 12 (8%) and skin involvement 43 (28%).
- Oro-genital involvement predominantly included vitiligo in 5 cases followed by candidiasis in 2cases , lichen planus in 1cases, SJS in 2 cases and PV in 2 cases.
- Among the oro-genital and skin involment 11(7%) with 6 (3%) cases of vitiligo, 1 cases of LP, 2 casesof SJS and 2 cases of PV.
- A total of 26 non –venereal genital dermatoses were encountered with folliculitis 25(16%) being the most common dermatoses followed closely by LSC 22 (14%) and vitiligo 21(14%).
- A total of 43 cases (28%) with systemic involvement was recorded with most common association being DM-2 13 (8%) followed by HTN 9 (6%) and thyroid7 (4%) and others.
- Among the 150 cases recorded labia majora was the most common site 96(64%) followed by labia minora 19(12%) and introitus 13(8%).

- Among the presenting complaints, itching being the most common 56 (37%) followed by white lesion 28 (18%), pain 20 (13%) and scaling10 (6%).
- Most of the patients were housewifes 84 (56%) followed by teacher 23(15%) and agriculturist 11(7%) in the present study.
- Among 150 patients, 115 patients were in postpubertal, 17 patients were in postmenopausal and 7 patients in prepubertal age group.

CONCLUSION

A total of 150 cases of non-venereal dermatoses were recorded. Among that three disorders which were very common were folliculitis, vitiligo and Lichen simplex chronicus. Localized genital involvement were found to be quite significant among non-venereal dermatoses. This study was quite useful in clinical diagnosis and management of non-venereal dermatoses and differentiating them from venereal dermatoses which helps in allaying the guilt and fear among patients.

BIBLIOGRAPHY

1. Schlosser BJ, Mirowski GW. Approach to the patient with vulva vaginal complaints. Dermatol Ther 2010 ; 23 : 438-48.
2. Broardman LA, Kennedy MC. Diagnosis and management of vulvar skin disorders. Obstet Gynaecol 2008 ; 111: 1243-50.
3. Foster DC. Vulvar disease. Obstet Gynecol 2002 ; 100 : 145-63.
4. Wojnarowska F, Cooper SM. Anogenital (Nonveneral) Disaese. In: Bolognia JL, Jorizza JL, Rapini RP, editors. Dermatology. 2nd ed. USA: Mosby; 2007 p. 1099-124.
5. Hillman RJ, Walker MM, Harris JRW, Taylor-Robinson D. Genital dermatoses:a clinical and histopathological study. Genitourin Med 1992 ; 68 : 166-9.
6. Kamarashev JA, Vassileva SG. Dermatologic diseases of the vulva. Clin Dermatol. 1997 ; 15 : 53-65.
7. Lynch PJ, Moyal-Barracco M, Bogliatto F, et al. 2006 ISSVD classification of vulvar dermatoses: pathologic subsets and their clinical correlates. J Reprod Med 2007 ; 52 : 3-9, 110.
8. Lynch PJ. 2011 International Society for the Study of Vulvovaginal Disease terminology and classification of vulvar dermatological Disorders: An approach to clinical diagnosis. J Low Genit Tract Dis 2012.
9. Margesson LJ. Contact dermatitis of vulva. Dermatol Ther 2004 ; 17 : 20-7.
10. Crone AM . Aetiological factors in vulvar dermatitis. J Eur Acad Dermato Venereol 2000 ; 14 : 181-6.
11. Brenan JA. Evaluation of patch testing in patients with chronic vulvar symptoms. Australas J Dermatol 1996 ; 37 : 40-3.
12. Goldsmith PC, Rycroft RJ, White IR, et al. Contact sensitivity in women with anogenital dermatoses. Contact Dermatitis 1997 ; 36 : 174-5.

13. Bircher AJ, Hirsbrunnerp, Langauer S. Allergic contact dermatitis of the genital to additives in condoms. Contact Dermatitis199 3; 28 : 125-6.
14. Mroczkowski TF. Common nonvenereal genital lesions. Med Clin North Am1990 ; 74 : 1507-1528.
15. Salim A,Wojnarowska F. Skin diseases affecting the vulva. Curr obstet Gynaecol 2002 ; 12 : 81-89.
16. Apgar BS , Cox JT. Differentiating normal and abnormal findings of the vulva. Am Fam Physician 1996 ; 53 : 1171-1180.
17. Varghese M, Kindel S. Pigmentary disorders and inflammatory lesions of the external genitalia. Urol Clin North Am 1992 ; 19 : 111-121.
18. Weinrauch L, Katz M. Psoriasis vulgaris of labium majus. Cutis1986 ; 38 : 333-334.
19. Albert S, Neil S, Derrick EK, Calonje E. Psoriasis associated with vulval scarring. Clin Exp Dermatol 2004 ; 29 : 354 -356.
20. Morris A, Rogers M, Fischer G, Williams K. Childhood psoriasis: a clinical review of 1262 cases. Pediatric Dermatol 2001 ; 18 : 188-198.
21. Lewis FM, Shah M, Harrington CI. Vulvar involment in lichen planus: a study of 37 women. Br J Dermatol 1996 ; 135 : 89-91.
22. Santegoets LA, Helmerhorst TJ, Van derMeijden WI. A retrospective study of 95 women with clinical diagnosis of genital lichen planus. J Low Genital Tract Dis 2010 ; 14 : 323-8.
23. Lewis FM. Vulval lichen planus. Br J Dermatol 1998 ; 138 : 569-75.
24. Eisen D. The vulvovaginal - gingival syndrome of lichen planus. The clinical characteristics of 22 patients. Arch Dermatol 1994 ; 130 : 1379-82.
25. Wallace HJ. Lichen sclerosus et atrophicus. Trans St.John’s Hosp Dermatol Soc 1971 57 : 9-30.

26. Meffe rt JJ, Davis BM, Grimwood RE. Lichen sclerosus. J A M Acad Dermatol 1995; 32: 393-416.
27. Ridley CM, Neil SM. Non-infective cutaneous conditions of vulva. In: Ridley CM ,Neil SM, eds. The Vulva. Oxford: Blackwell Science, 1999 : 154-6.
28. Powell JJ, Wojnarowska F. Lichen sclerosus.Lancet 1999 ; 353 : 1777-83.
29. Ridley CM. Genital lichen sclerosus (lichen sclerosus et atrophicus) in childhood and adolescence. J R Soc Med 1993 ; 86 : 69-75.
30. Chaudhry SI, Morgan PR, Neil SM. An unusual tongue. Clin Exp Dermatol 2006 ; 31 : 831-2
31. Marren P, Miland P, China Y et al. Mucosal lichen sclerosus/ lichen planus overlap. Br J Dermatol 1994 ; 131 : 118-23.
32. Meneux E, Paniel BJ, Pouget F, Revuz J, RonjeaJC, Wolkenstein P. Vulvovaginal sequelae in toxic epidermal necrolysis. J Reprod Med.1997 ; 42 : 153-6.
33. Uzun S, Alpsoy E, Durdu M, Akman A. The clinical course of Behcets disease in pregnancy. A retrospective analysis and review of the literature. J Dermatol 2003 ; 30 : 499-502.
34. Marsal S, Falga C, Simeon CP, Vilardell M & Bosch JA. Behcet's disease and pregnancy relationship study. British Journal of Rhematology 1997 ; 36 : 234-238.
35. Garnier G. Benign plasma - cell erythroplasia. Br J Dermatol 1957 ; 69 : 77-81.
36. Brix WK, Nassau SR, Patterson JW, et al. Idiopathic lymphoplasmacellular Mucositis - dermatitis. J Cutan Pathol 2010 ; 37 : 426-31.
37. Mc creedy CA, Melski JW. Vulvar erythema: Vulvitis chronic plasmacellularis. Arch Dermatol 1990 ; 126 : 135-7.
38. Amagai M. Pemphigus : autoimmunity to epidermal cell adhesion molecules. Adv Dermatol 1996 ; 11 : 319-52.

39. Mignogna MD, Fortuna G, Leuci S, et al. Oropharyngeal pemphigus vulgaris and clinical remission: a long-term, longitudinal study. Am J Clin Dermatol 2010 ; 11 : 137- 45.
40. Liu Z, Diaz LA. Bullous pemphigoid: end of the century overview. J Dermatol 2001 ; 28 : 647-50.
41. Marren P, Wojnarowska F, Venning VA, et al. Vulvar involment in autoimmune bullous diseases. J Reprod Med 1993 ; 38 : 101-7.
42. Urano S. Localized bullous pemphigoid of vulva. J Dermatol 1996; 23: 580-2.
43. Schornick JK. Herpes gestationis. Dermatol Clin1993 ; 11 : 527-33.
44. Burge SM. Hailey - Hailey disease: the clinical features, response to treatment and prognosis. Br J Dermatol 1992 ; 126 : 275-82.
45. Evron S, Leviatan A, Okon E. Familial benign chronic pemphigus appearing as leukoplakia of vulva. Int J Dermatol 1984 ; 23 : 556-7.
46. Wieselthier JS, Pincus SH. Hailey- Hailey disease of vulva. Arch Dermatol 1993; 129 : 1344-5.
47. Sakuntabhai A, Ruiz-Perez V, Carter S, et al. Mutation in ATP2A2, encoding a Ca+ pump, cause Darier disease. Nat Genet 1992 ; 21 : 271-7.
48. Burge SM, Wilkinson JD. Darier-White disease: a review of the clinical features of 163 patients. J Am Acad Dermatol 1992 ; 27 : 40-50.
49. Barrett JF, Murray LA, MacDonald HN. Dariers disease localized to vulva. Case report. Br J Obstet Gynaecol 1989 ; 96 : 997-9.
50. Wheat LJ, Kohler RB, White A. Treatment of nasal carriers of coagulase - positive staphylococci.In : Maibach HI, Aly R, editors. Skin microbiology: Relevance to clinical infection. New York : Springer, 1981 : 50-58.
51. Thearle MJ, Wise R, Allen JT. Blue nappies. Lancet 1973 ; 499-500.

52. Bonar BE, Rabson AS. Gynaecological aspects of leprosy. Obstet Gynecol 1957; 33-8.

53. Beyt BE, Ortbals DW, Santa Cruz DJ, et al. Cutaneous mycobacteriosis: Analysis of 34 cases with a new classification of the disease. Medicine. 1981 ; 60 : 95-109

54. Ringdhal EN. Treatment of recurrent vulvovaginal candidiasis. Am Fam Physician 2000 ; 61 : 3306 -3312.

55. Fidel PL Jr, Sobel JD. Immunopathogenesis of recurrent vulvovaginal candidiasis. Clin Microbiol Rev 1996 ; 9 : 335- 348.

56. Ferrer J.Vaginal candidiasis : epidemiological and etiological factors. Int J Gynaecol Obstet 2000 ; 60 : 21-27.

57. Venugopal TV,Venugopal PV, Paramasivan CN, Shetty BMV, Subramanian S. Mycetomas in Madras. Sabouraudia 1977 ; 15 : 17-23.

58. Bradsher RW. Therapy of blastomycosis. Sem Resp Infection1997 ; 12 : 263-7.

59. Naguibs SM. Epidemiologic study of trichomoniasis in normal women. Obstet Gynecol.1966; 27: 607-16.

60. Brown TJ, Yen-Moore A, Tyring SK. An overview of sexually transmitted diseases. J Am Acad Dermatol 1999 ; 41: 511- 532.

61. WHO.Vaccineshumanpapillomavirus.www.who.int/vaccines/en/hpvrd.Accessed January 19, 2010.

62. Winer RL, Lee SK, Hughes JP, Adam D, Kiviat NB, Koutsky LA. Genital human papillomavirus infection : incidence and risk factors in a cohort of female university students. Am J Epidemiol 2003 ; 157 : 218-226.

63. CDC. Quadrivalent human papillomavirus vaccine : recommendations of advisory committee on immunization practices . MMWR 2007 ; 56 : 1-24.

64. Dunne EF, Unger ER , Sternberg M , et al. Prevalence of HPV infection among females in United States. JAMA 2007 ; 297 : 813-819.

65. Villarreal E. Current and potential therapies for the treatment of herpe simplex infections. Prod Drug Res 2003 ; 60 : 263-307.

66. Schwartz RA. Kaposi's sarcomaan update. J Surg Oncol 2004; 87:146-51.

67. Brady R, Bernstein D. Treatment of herpes simplex infections. Antiviral Res 2004; 61: 73-81.

68. Lafferty W. The challenging epidemiology pf HSV-1 and HSV-2 and implications for serological testing. Herpes 2002; 9: 51-5.

69. Holmes K K, Stamm S, Piot WE , Wasserheit J N, Corey L, et al. *Sexually Transmitted Diseases*. 4th ed. NewYork : Mc Graw-Hill ; 2008. Canadian STI Guidelines 2008 Revised Edition.

70. Karthikeyan K. Scabies in children. Arch Dis Child Educ Pract 2007; 92: 65-9.

71. Alexander JOD. Arthropods and skin, ed. Berlin: Spinger – Verlag ; 1984. P 50-5.

72. Passor MR, Carvalho AV, Dutra AL, Goulart Filho RA, Barreto NA, Salles RS, et al. Vulvar myiasis . Infect Dis Obstet Gynecol 1998 ; 6: 69 -71.

73. Smith KG. Anisopus larva (Diptera) in cases of intestinal and urino - genital myiasis. Nature 1966 ; 210 : 852.

74. Kingland CR, Alderman B. Crohns disease of the vulva. J R Soc Med 1991; 84: 236-7

75. Lowitt MH, Kariniemi A-L, Niemi KM, Kao GF. Cutaneous malakoplakia: a report of two cases and review of literature. J Am Acad Dermatol 1996 ; 34 : 325-32.

76. Chobanian SJ. Skin tags and colonic polyps : a gastroenterologists perspective. J Am Acad Dermatol 1997 ; 16 : 407-9.

77. Darmstatdt G. Perianal lympangioma circumscriptum mistaken for genital wart. Paediatrics. 1996 ; 98 : 461-3.

78. Shetty CM, Rai PK, Jain VK. Post traumatic epidermoid inclusion cyst of the orbit. Indian J Radiol Imaging 2006 ; 16 : 135-7.

79. Kettler AH, Goldberg LH. Seborrheic keratoses. Am Fam Physician 1986; 34: 147-52.

80. Cashmore RW, Perry HO. Differentiating seborrheic keratosis from skin neoplasm. Geriatrics 1985 ; 40 : 4-5, 69-71.

81. Braun RP, Rabinovitz HS, Krischer J, Kreusch J, Oliviero M, Naldi L, *et al*. Dermoscopy of pigmented seborrheic keratosis: A morphological study. Arch Dermatol 2002 ; 138 : 1556-60.

82. Carnerio SJ, Gardner HL, Knox IM. Syringoma of the Vulva. Arch Dermatol 1991; 103 : 49 4- 496.

83. Requena l, Pena M, Sanchez M,Sanchez YE. Papillary ecrine adenoma. J Am Acad Dermatol 1988 ; 18 : 114-20.

84. Biernat W, KordekR, Wozniak L. Papillary ecrine adenoma - a case of cutaneous sweat gland tumor with secretory and ductal differentiation. Pol J Pathol 1994 ; 45 : 319-22.

85. Fitzsimmons JS, Gilbert G. A family study of hidradenitis suppurativa . J Med Genet 1985 ; 22 : 367-73.

86. Church JM, Fazio VW, Lavery IC. The differential diagnosis and comorbidity of hidradenitis suppurativa and perianal crohn's disease. Int J Colorectal Dis 1993 ; 8 : 117-9.

87. Schreiber MM. Vulval von Recklinghausen's. Arch Dermatol 1963 ; 88 : 320-1

88. Lewis FM, Lewis-Jones MS, Toon PG et al. Neurofibromatosis of vulva. Br J Dermatol 1992 ; 127 : 540-1.

89. Mann PR. Leiomyoma cutis- An electron microscopic study. Br J Dermatol 1970 ; 82 : 463.

90. Nanda A, Kanwar AJ, Kapoor MM, et al. Xanthoma disseminatum. Int J Dermatol. 1990 ; 29 : 727-8.

91. Scurry J, Wilkinson GJ. Review of the terminology of vulvar squamous cell carcinoma. J Lower Genital Tract disease 2006 ; 10 : 161-9.

92. Sugase M, Matsukura T. Distinct manifestation of human papillomaviruses in the vagina. Int J Cancer 1997 ; 72 : 412- 5.

93. Joura EA. Epidemiology, diagnosis and treatment of vulval intraepithelial neoplasia. Curr Opin Gynecol 2002 ; 14 : 39-43.

94. McNally OM, Mulvany NJ, Paganao R, et al. VIN3: A clinicopathologic review. Int J Gynecol Cancer 2002 ; 12 : 490-5.

95. Aho M, Vestrinen E, Mayer B, et al. Natural history of Vaginal intraepithelial neoplasia. Cancer 1991; 68 : 195-7.

96. Raju RR, Goldblum JR, Hart WR. Pagetoid squamous cell carcinoma in situ of the external genitalia. Int J Gynecological Pathol 200 3; 22 : 127-135.

97. Taieb A , Picardo M. Epidemiology, definition and classification. In: Vitiligo. Berlin: Heidelberg Springer; 2010. p13-24.

98. Dolatshahi M, Ghazi P, Feizy V, Hemami MR. Life quality assessment among patients with vitiligo: comparision of married and single patients in Iran. Indian J Dermatol venereol Leprol 2008 ; 74 :700.

99. Mattoo SK, Handa S, Kaur I, Gupta N, Malhotra R. Psychiatric morbidity in vitiligo and psoriasis : a comparative study from India. J Dermatol 2001; 28 : 424-32.

100. Choi S, Kim DY, Whang SH, Lee JH, Hann SK, Shin YJ. Quality of life and psychological adaptation of Korean adolescents with vitiligo. J Eur Acad Dermatol Venereol 2010 ; 24 : 524-9.

101. Dave S, Thappa DM, Souza DM. Clinical predictors of outcome in vitiligo. Indian J Dermatol Venerol Leprol 2002 ; 68 : 323 -325.

102. Stevenson CJ . Occupational vitiligo: Clinical and epidemiological aspects. Br J Dermatol 1981; 105 : 51-56.

103. Lynch PJ. Pigmented disorders. In: Edwards L, Lynch PJ, editors. Genital dermatology atlas. 2nd edition. Philadelphia: Lippincptt Williams & Wilkins; 2010 : 170 -85.

104. Wiseman MC, Klemperer E. Brown lesions. In: Edwards L, editor. Genital dermatology atlas. Ist edition. Philadelphia: Lippincott Williams & Wilkins ; 2010. 170- 85.

105. Grasinger C, Wild R, Parker I. Vulvar acanthosis nigricans: a marker for insulin resistance in hirsute women. Fertil Steril 1993 Mar ; 59: 583-6.

106. Rock B, Hood AF, Rock JA. Prospective study of vulvar nevi. J Am Acad Dermatol 1990 ; 22 : 104-6.

107. El Shabrawi- Caelen L, Soyer HP, Schaepp H, et al. Genital lentigines and melanocytic nevi with superimposed lichen sclerosus: a diagnostic challenge. J Am Acad Dermatol 2004 ; 50 : 690-4.

108. Fargnoli MC, Orlow SJ, Semel – Conception J, et al. Clinicopathologic findings in Bannayan- Riley- Ruvalcaba syndrome. Arch Dermatol 1996 ; 13 2: 1214-8.

109. Rhodes AR, Silverman RA, Harris TJ, et al. Mucocutaneous lentigines, cardio mucocutaneous myxomas and multiple blue nevi: the LAMB syndrome. J Am Acad Dermatol 1984 ; 10 : 72-82.

110. Virgili A, Bacileri S, Corazz M. Managing vulvar lichen simplex chronicus. J Reprod Med 2001; 46 : 343-6.

111. OKeefe RJ, Scurry JP, Dennerstein G, et al. Audit of 114 non - neoplastic vulvar biopsies. Br J Obstet Gynaecol 1995 ; 102 : 780-6.

112. LaPolla J, Foucar E, Leshin B, et al. Vulvar Lymphangioma circumscriptum: a rare complication of therapy for squamous cell carcinoma of the cervix. Gynec Oncol 1985 ; 22 : 363-6.

113. Dere O, Bildiricil l, Al A. Massive vulvar edema complicating a diabetic pregnancy. Eur J Obstet gynecol Reprod Bio 2000 ; 42 : 554.

114. Singh N, Thappa DM, Jaisankar TJ, Syed H, Pattern of non- venereal dermatoses of female external genitalia in south India Dermatology online Journel 14: 1.

115. Puri N, Puri A. A study on non-venereal genital dermatoses in north India. Our Dermatol Online. 2012 ; 3 : 304–307.

116. Acharya KM, Ranapara H, Sakia JJ, et al. A study of 200 cases of genital lesions of non-venereal origin. Ind J Dermatol Venereol Leprol 1999 ; 64: 68-70.

117. Karthikeyan K, Jaisankar TJ, Thappa DM. Non-venereal dermatoses in male genital region-prevalence and patterns in a referral centre in South India. Indian J Dermatol 2001 ; 46 : 18-22.

118. Khoo LS, Cheong WK. Common genital dermatoses in male patients attending a public sexually transmitted disease clinic in Singapore. Ann Acad Med Singapore1995 ; 24 : 505-9.

119. Erlap . Concurrent oral and genital involment in lichen planus. Ind J Dermatol Venereol Leprol 2009 ; 75 : 77-78.

120. Cheung ST, Gach JE, Lewis FM. Aretrospective study of the referral patterns to a vulval clinic: highlighting educational needs in this subspecialty . J Obstet Gynaecol; 26 : 435-7.

121. Meneux E, Paniel BJ, Pouget F, Revuz J, Roujean JC, WolkensteinP. Vulvovaginal sequelae in toxic epidermal necrolysis. J Reprod Med.1997 ; 42 : 1536.

122. Marren P, Wojnarowska F. Venning V et al. Vulvar involvement in autoimmune bullous diseases. J Reprod Med 1993 ; 38 : 101-7.

123. Fischer G, Rogers M. Vulvar diseases in children: A clinical audit of 130 cases Pediatr Dermatol 2000 ; 17 : 1-6.

ANNEXURES

CONSENT FORM

Mrs/Ms ----------

Age---------- years ----------

Adress ----------

Hereby give consent to Dr.Muktamani G ,for performing the procedure related to the study as previously explained to me and any other procedure necessary or advisable to complete the study include the use of local anaesthesia.

I have completely understood the purpose of the procedure and the associated possible complications. I also agree to co-operative with her and agree by my own free will and in complete consciousness without any influence give my consent.

I shall in no way hold the doctor responsible for any of the procedure or the consequences whatsoever.

PROFORMA

SL NO -

Name : Hosp No:

Age : Marital status:

Sex : Religion:

Occupation: Address:

PRESENTING COMPLAINTS;

DRUG HISTORY:

DURATION:

HISTORY OF PRESENTING COMPLAINTS:

1. Onset : Sudden/insidious
2. Progression : Sationary/infection/drugs
3. Initial site :
4. Oral Mucosa :
5. Associated Skin lesion :
6. Provoking factors : Emotion/strain/infection/drugs
7. Seasonal variation : Increased/decreased/nochange
8. Any other associated disease :

PAST HISTORY : history of similar illness: present/absent

FAMILY HISTORY :

PERSONAL HISTORY :

Diet : Appetite:

Bowel :

Micturition: :

Sleep : H/O exposure:

Menstrual history :

Vital signs :

Pulse : Respiratory rate:

Blood pressure : Temperature**:**

GENITAL EXAMINATION:

a. Morphology of lesion -

b. Size -

c. Shape -

d. Colour -

e. Scaling -

f. Symptoms -

g. Surrounding skin -

SYSTEMIC EXAMINATION

CVS : GIT :

CNS : RS :

PROVISIONAL DIAGNOSIS:

INVESTIGATIONS:

1) KOH preparation :

2) Blood:

3) Urine:

4) Stool:

5) SKIN BIOPSY:

FINAL DIAGNOSIS:

KEY TO MASTER CHART

1) Serial number

2) OP/IP

3) AGE-

4) Sex- female (F)

5) Marital status – M (Married) U (Unmarried)

6) Religion – Hindu (H), Muslim (M), Christian(C)

7) Duration – A (< I WEEK) c – (since birth)

B (> 1 WEEK)

8) Site –

A – Labia majora D- Introitus

B – Labia minora E- Groin

C- Mons pubis

9) Symptoms -

A- Pain F- White discharge

B- Itching G- Burning

C- White lesion H- Erosion

D- Scaling I- Fluid filled lesion

E- Pigmentation J- Swelling

10) Diagnosis-

A- Folliculitis O- Cyst

B- LSC P- Bullous Pemphigoid

C-Vitiligo

D- Candidacies

E- Intertrigo

F- Psoriasis

G- Scabies

H- T.Cruris

I-LP

J-LSEA

K-Skin tag

L-SJS

M-IED

Q- Pemphigus Vulgaris

R- Sebborehic dermatitis

S - Hemangioma

T- Leukoderma

U- Erythrasma

V- Molluscum contagiosum

W-Physiological Hyperpig

X- Maggot infestation

Y- Pediculosis pubis

Z- Diaper dermatitis

N-Edema

11) Investigation –

B- Biopsy

N-Nil

C- Culture

KP- KOH Positive

KY- KOH-Yeast

GP- Grams positive

M- Burrows

12) Associated systemic disease –

A – DM 2

B-HTN

C- Thyroid

D- Asthma

E- Anemia

F- Cataract

G- TB

13) Occupation –

A- Housewife

B – Teacher

C- Labourer

D - Agriculturist

E- School going

F- Others

MASTER CHART

SI NO.	NAME	Religion	HOSPITAL NO.	AGE	MARITAL STATUS	OCCUPATION	CHIEF COMPLAINTS	DIAGNOSIS	Site of Involment	Associated Conditions	INVESTIGATIONS	DURATION
1	Taruni	H	675571	17	U	E	A,B	A	C	E	N	A
2	Noorumisa	M	537615	12	U	E	AB	A	C	H	N	A
3	Renuka	H	497001	30	M	A	A,E	A	C	H	GP	A
4	Monika	H	663231	23	M	E	A,B	A	A	C	N	A
5	Rama mani	H	802076	35	M	B	A,B	A	C	D	GP	A
6	Rajama	H	432964	25	M	A	A,B	A	C	Xerosis	N	A
7	Sumatama	H	607278	36	M	A	A,B	A	A	B	GP	A
8	Yashodamma	H	858059	56	M	A	A,G	A	C	H	N	A
9	Sabana	M	848329	30	M	F	A,B	A	A	H	GP	A
10	Shanthi	H	80213	35	M	A	A	A	C	B	GP	A
11	Gauthami	H	807652	19	U	E	A,G	A	C	E	N	A
12	Radhama	H	814898	38	U	F	A	A	A	H	N	A
13	Venkatama	H	549422	38	M	A	A,B	A	A	F	GP	A
14	Buchamas	H	507223	40	M	A	A,B	A	C	D	GP	B
15	Malathi	H	590890	30	M	B	A,G	A	A	H	GP	A
16	Sabana	M	888448	20	U	B	A,G	A	C	H	GP	B
17	Indramani	H	888449	48	M	E	A,G	A	A	C	N	A
18	Smitha	H	905447	26	M	A	A,G	A	A	H	N	B
19	Anusha	H	904483	26	M	F	A,G	A	A	H	GP	A
20	Narayanama	H	904153	56	M	A	A,G	A	C	D	N	B
21	Shaheeba	M	9038008	48	M	F	A,B	A	A	H	GP	A
22	Lakshmidevi	H	898489	29	M	B	A,B	A	A	A	GP	B
23	Sathamani	H	893496	56	M	F	A,B	A	A	C	GP	A
24	Zaibunisha	M	892116	49	M	A	A,B	A	A	H	GP	B
25	Kusum	M	889535	26	M	A	A,B	A	C	H	N	A
26	Komalama	H	905105	56	M	A	A,B	B	A	H	N	B
27	Sakunthala	H	904784	44	M	A	A,B	B	A,E	stress	N	B
28	Ganjajama	H	901710	48	M	A	B	B	A	Intertrigo	N	B
29	Gopaman	H	904513	47	M	A	B	B	A	D	KP	B
30	Suthama	H	903680	48	M	A	E	B	A	H	N	B
31	Govindama	H	952235	45	M	A	E	B	A	xerosis	N	B
32	Shweta priya	H	841711	23	U	E	E	B	A	H	N	B
33	Anbazhagi	M	823404	44	M	A	B	B	A,E	D	N	B
34	Mangama	H	900327	56	M	A	B	B	A	B	N	B
35	Tajuniba	M	900864	38	M	A	B	B	A	H	N	B
36	Mytreya	H	700711	46	M	A	B	B	A	A	N	B
37	Geeta	H	631743	33	M	B	B	B	A	A	N	B
38	Suma	H	879503	35	M	B	A	B	A	H	N	B
39	Gowrama	H	689501	30	M	A	B	B	A	vitiligo vulgaris	N	B
40	Niramala	H	696880	31	M	A	B	B	A	H	N	B
41	Veena	H	796682	33	M	A	B	B	A	psoriasis	N	B

MASTER CHART

42	Shaheen Taj	M	945119	27	M	A	E	B	A	H	N	B
43	Shanthamma	H	636260	46	M	A	E	B	A	B	N	B
44	Shilpa	H	945247	47	M	B	B	B	A	H	N	B
45	Munibai	H	905416	54	M	A	B	B	A	H	N	B
46	Shruthi	H	991332	28	M	A	B	B	A	H	N	B
47	Shruthi	H	791332	28	M	B	B	B	A	E	N	B
48	Shakti	H	605881	22	U	D	C	C	A	vitiligo vulgaris	N	B
49	Sandhya	H	542402	32	M	D	C	C	C	vitiligo vulgaris	N	B
50	Pushpa	H	606038	42	M	C	C	C	B	H	N	B
51	Varalakshmi	H	798211	12	U	C	C	C	A	D	N	B
52	Shashikala	H	728372	44	M	A	C	C	A	H	N	B
53	Reshma	H	556025	40	M	D	C	C	A	B	N	B
54	Venkatama	H	834095	60	M	A	C	C	A	H	N	B
55	Shantama	H	553003	32	M	A	C	C	A	D	N	B
56	Suruppa	H	857044	38	M	B	C	C	A	liptip vitiligo	N	B
57	Naveena	H	857095	32	M	A	C	C	A	H	N	B
58	Shantama	H	587066	32	M	B	C	C	B	liptip vitiligo	N	B
59	Sharmila	H	562294	35	M	B	C	C	A	liptip vitiligo	N	B
60	Nanndini	H	639900	23	U	B	C	C	A	B	N	B
61	Sujatha	H	884983	38	M	C	C	C	A	H	N	B
62	Muniya	H	886805	48	M	A	C	C	A	H	N	B
63	Muniayama	H	574080	30	M	A	C	C	A	E	N	B
64	Munikantama	H	886090	55	M	A	C	C	A	Xerosis	N	B
65	Parijatha	H	904849	36	M	F	C	C	A	vitiligo vulgaris	N	B
66	Bharathi	H	904202	26	M	A	C	C	B	impetigo	N	B
67	Sakama	H	893370	56	M	D	C	C	A	H	N	B
68	Venkatama	H	900476	42	M	A	C	C	A	H	N	B
69	Chandrika	H	886838	28	M	A	H	D	D	A	KY	A
70	Fareeda	M	851538	30	M	A	A,F	D	D	H	N	B
71	Bayama	H	901772	48	M	A	B	D	D	A	N	A
72	Madhavi	H	905392	30	M	A	G	D	D	A	N	A
73	Chinama	H	502478	20	M	C	F	D	D	H	N	A
74	Sakarama	H	905163	47	M	A	F	D	D	A	N	B
75	Saralakshmi	H	619176	33	M	B	G	D	D	oral mucosa	N	A
76	Amulya	H	552877	23	U	D	F	D	D	H	KY	B
77	Manasama	H	550359	36	M	A	B	D	D	oral mucosa	KY	B
78	Ashwathama	H	429919	26	M	A	F	D	D	H	N	A
79	Divya	H	623949	23	M	A	B,G	D	D	H	N	A
80	Yallama	H	673166	30	M	A	E,F	D	D	pregnancy	N	B
81	Sarasamma	H	612009	37	M	A	E,F	D	D	H	KY	B
82	kumari	H	861004	74	M	A	B	E	A	A	N	B
83	Nasaba	M	895458	49	M	A	A,B	E	A,E	B	N	B
84	Shakuntala	H	831974	36	M	B	B	E	A	H	N	B
85	Umavathi	H	888872	29	M	A	B	E	A	H	N	B

MASTER CHART

86	Bharathi	H	886844	29	M	A	A,G	E	A	H	N	B
87	Lakshmidevi	H	802327	60	M	A	B	E	A	H	N	B
88	Sathamani	H	861266	68	M	A	A,G	E	A	A	N	B
89	Vijaya	H	884022	48	M	A	B,D	E	A	B	N	B
90	Bhavani	H	882781	23	M	A	B	E	A	A	N	B
91	Manjula	H	663042	36	M	D	B,D	E	A	C	N	B
92	Sayeda	M	672281	34	M	F	G	E	A	H	N	B
93	Deepa	H	707604	23	M	A	D	E	A	H	N	B
94	Rukmani	H	793736	31	M	A	B,D	E	A	H	N	B
95	Navarathnama	H	905073	37	M	A	B,D	F	A	H	N	B
96	lakshmama	H	796679	50	M	A	B,D	F	A	psoriasis	N	
97	Preema	H	570657	32	M	A	D	F	A	psoriasis	N	B
98	Venkatlakshmama	H	747043	35	M	A	D	F	A	psoriasis	N	B
99	Sunitha	H	892411	26	M	B	B,D	F	A	psoriasis	N	B
100	Malathi	H	901313	28	M	A	B,D	F	A	psoriasis	N	B
101	Sneha	H	888557	39	M	A	B,D	F	A	psoriasis	N	B
102	Rizwana	M	857801	46	M	A	B,D	F	A	psoriasis	N	B
103	Priyarani	H	860432	10	U	E	B,F	F	A	t.corporis	N	
104	Bibijan	M	794321	45	M	A	D	G	A	scabies infamily	N	B
105	Manjama	H	641615	44	M	A	B	G	A	tuberculoosis	M	A
106	Mallika	H	8885096	28	M	B	B	G	A	vitiligo vulgaris	N	A
107	Sarojamma	H	885282	50	M	A	B	G	A	A	M	A
108	Anusuyama	H	893467	29	M	A	B	G	A	gen scabies	N	A
109	Chadana	H	689861	24	U	C	B	H	A	H	KP	B
110	Madhavi	H	792296	28	M	D	B,D	H	A	xerosis	KP	B
111	Subhalakshmi	H	557171	38	M	A	B,D	H	A	folliculitis	N	B
112	Supriya	H	547655	23	M	D	B,D	H	A	H	N	B
113	Madhuri	H	798128	28	M	B	B	H	A	t.corporis	KP	B
114	Prema	H	570657	30	M	C	G	I	B	oral lp	B	B
115	Shobha	H	798229	38	M	B	A	I	B	lp of body	B	B
116	Subramani	H	673167	26	M	C	A	I	B	lp of body	N	B
117	Malathi	H	640145	35	M	D	A	I	A	lp of body	N	B
118	Sahana	H	857106	42	M	A	C	J	A	C	B	B
119	Shammama	H	512756	48	M	B	C	J	A	B	B	B
120	Athira	H	524699	52	M	A	C	J	B	A	B	B
121	Sumana	H	834257	3	U	nil	C	J	B	H	N	B
122	Tabasum	M	860111	18	U	E	H	J	A,B	oral &conjuntiva	N	B
123	Thimaka	H	901862	48	M	A	G	J	D	body&oral	N	B
124	Viramalal	H	901352	36	U	B	H	J	B	invol of body	N	B
125	Anitha	H	807626	29	U	B	H	J	A,B	invol of body	N	B
126	Suchitra	H	799151	15	U	E	B,D	M	A,C	H	N	A
127	Umavathi	H	614099	33	M	A	A,B	M	A,C	T.corporis	N	A
128	Lalitha bai	M	810735	38	M	A	B	M	A	A	N	A
129	Shikhama	H	503987	38	M	A	J	N	B	Furuncle	C	A

MASTER CHART

130	Maharam	H	945237	38	M	A	J	N	A,B	cellulities	N	A
131	Kanthan	H	888892	47	M	A	J	N	B	vitiligo vulgaris	N	B
132	Geeta	H	888822	26	M	A	J	O	B	H	N	A
133	Mynussia	M	856959	49	M	A	J	O	B	B	N	A
134	Sumathi	M	580669	34	M	A	J	O	B	A	N	A
135	Kamala	M	502826	63	M	A	I	P	A,C	B,F	B	B
136	Muniyama	M	549391	62	M	A	I	P	A,C	B,C	N	B
137	Jabeen Taj	H	876912	44	M	A	I	P	A	B	B	B
138	Krishnamma	H	796591	42	M	C	H,I	Q	B	Oral&scalp	B	B
139	Umavathi	H	796837	33	M	A	H	Q	B	Scalp&oral mucosa	B	B
140	Nethravathi	H	535656	33	M	A	D,G	R	A	scalp&nasolabial	KP	B
141	Zeenath BEE	M	791383	60	M	A	D	R	A,C	F	KP	B
142	Vandhana	H	894946	4mont	nil	nil	J	S	A	H	N	C
143	Saraswathi	H	885283	34	M	A	C	T	A	H	N	B
144	Mangama	H	547092	30	M	D	E	U	A	C	GP	A
145	Asha	H	663368	3	M	nil	J	V	A,C	H	N	B
146	Shalya	H	836296	30	M	A	E	W	D	H	N	C
147	Byamma	H	576912	23	M	A	H	X	A	H	N	A
148	Shammama	H	592933	36	M	D	K	Y	C	immunocompromised	N	B
149	Surekla	H	642913	31	M	B	J	K	A	H	N	B
150	Baby of komala	H	868791	3day	nil	nil	E	Z	A,E	diarrhoea	N	A